

"Encuentro Internacional Escuelas de Ozonoterapia"

4 y 5 Junio 2010



aepromo

Asociación Española de Profesionales Médicos en
Ozonoterapia

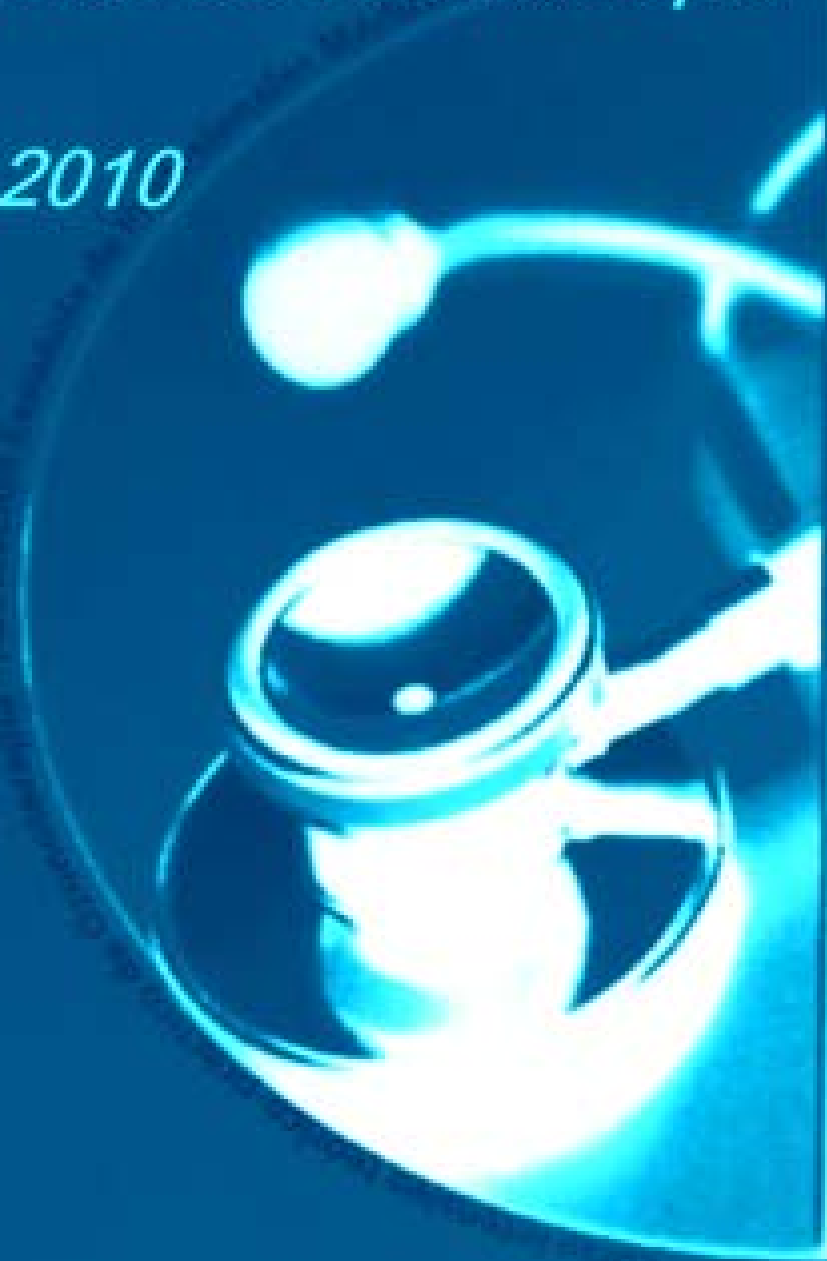AEPROMO

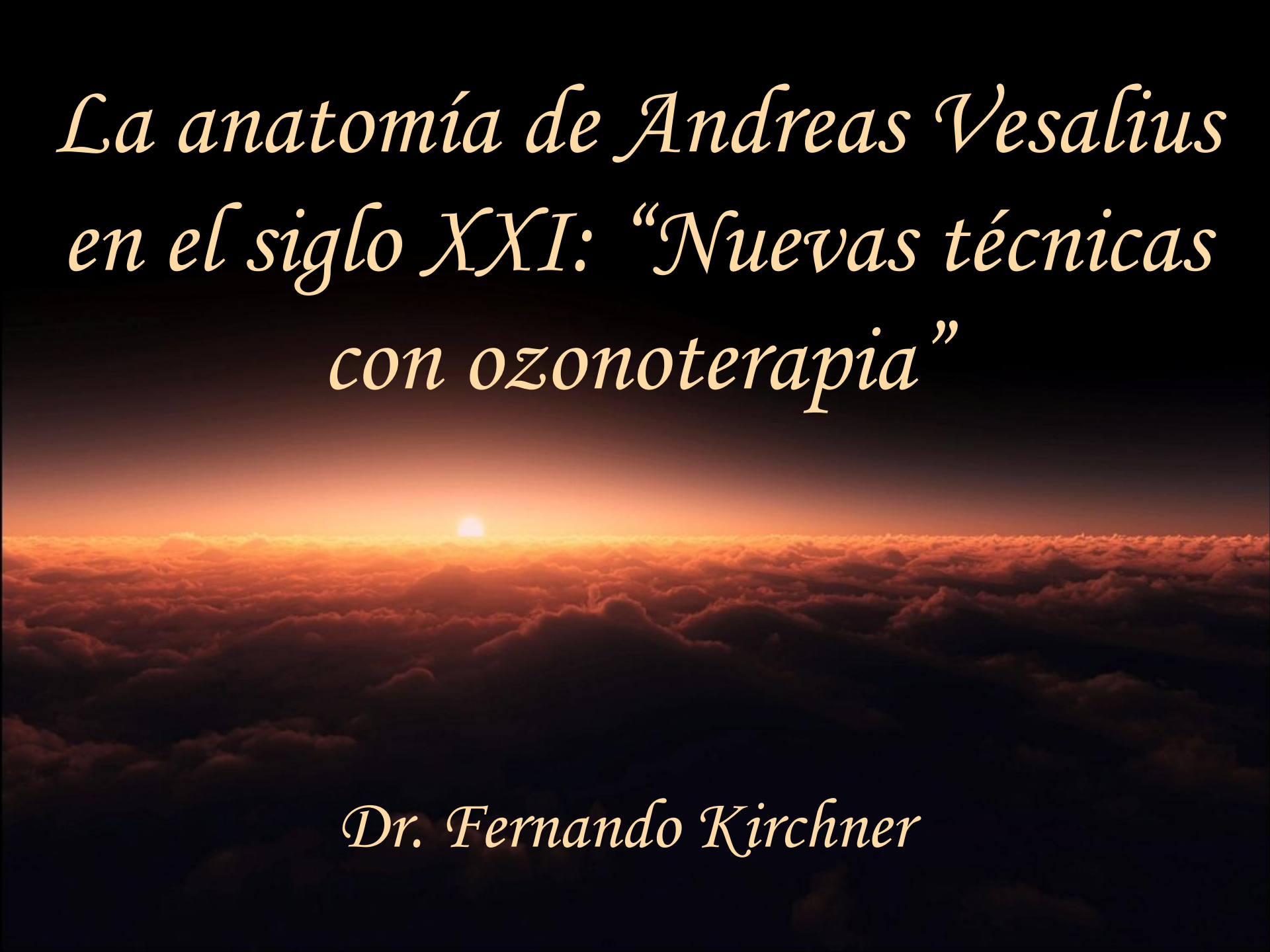
Avenida Juan Andrés 60, local 1 bajo, 28015 Madrid

Teléfono: (+34) 669685429 y (+34) 913515175

Fax: (+34) 913515175

Asociación Española de Profesionales Médicos en Ozonoterapia




A sunset scene with a bright sun low on the horizon, casting a warm orange glow over a vast expanse of dark, textured clouds. The sky transitions from a deep orange near the horizon to a dark, almost black, at the top.

*La anatomía de Andreas Vesalius
en el siglo XXI: “Nuevas técnicas
con ozonoterapia”*

Dr. Fernando Kirchner


















Leonardo de Vinci

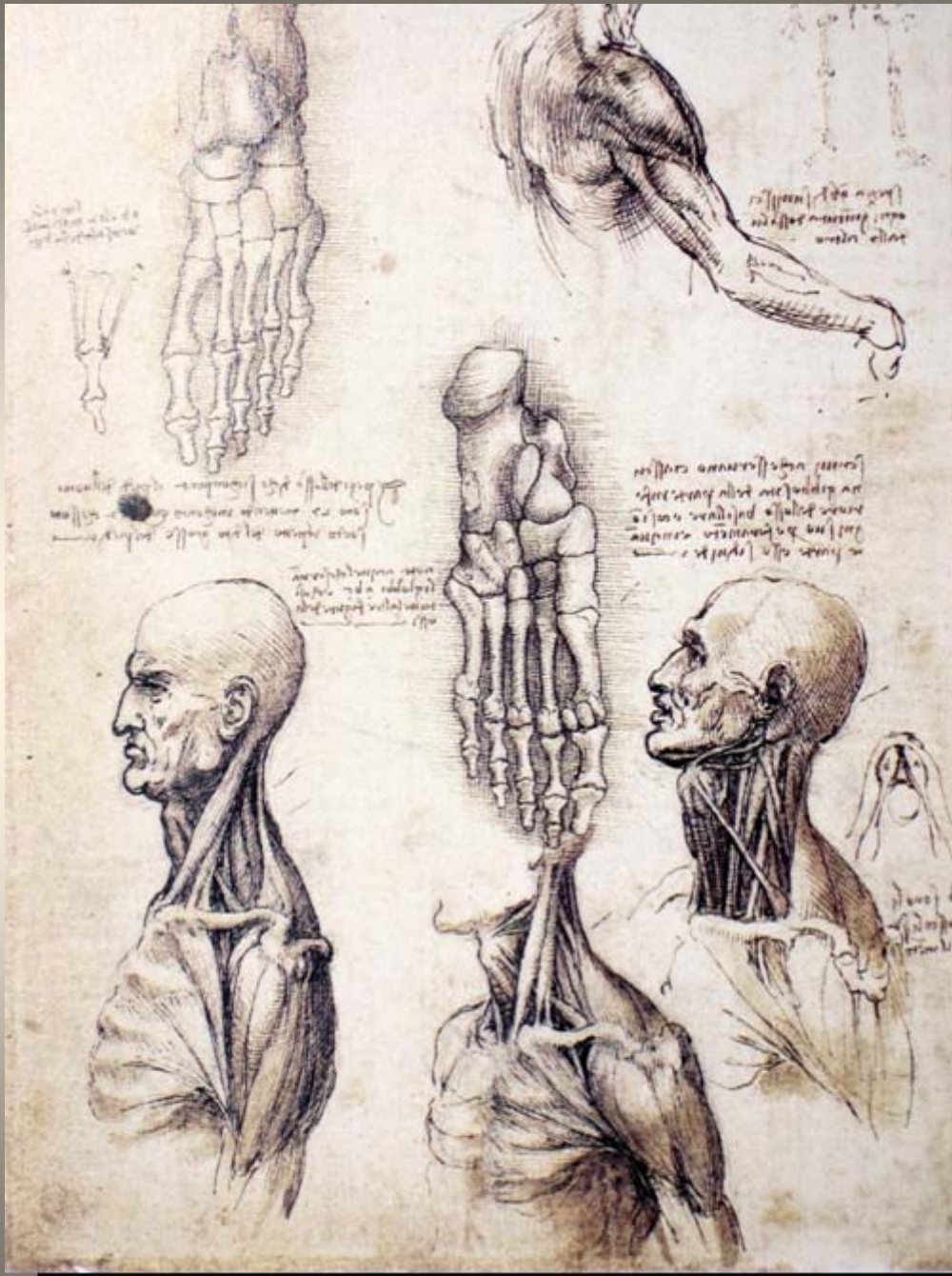
LE VITE
DE' PIV ECCELLENTI PITTORI,
SCULTORI, E ARCHITETTORI

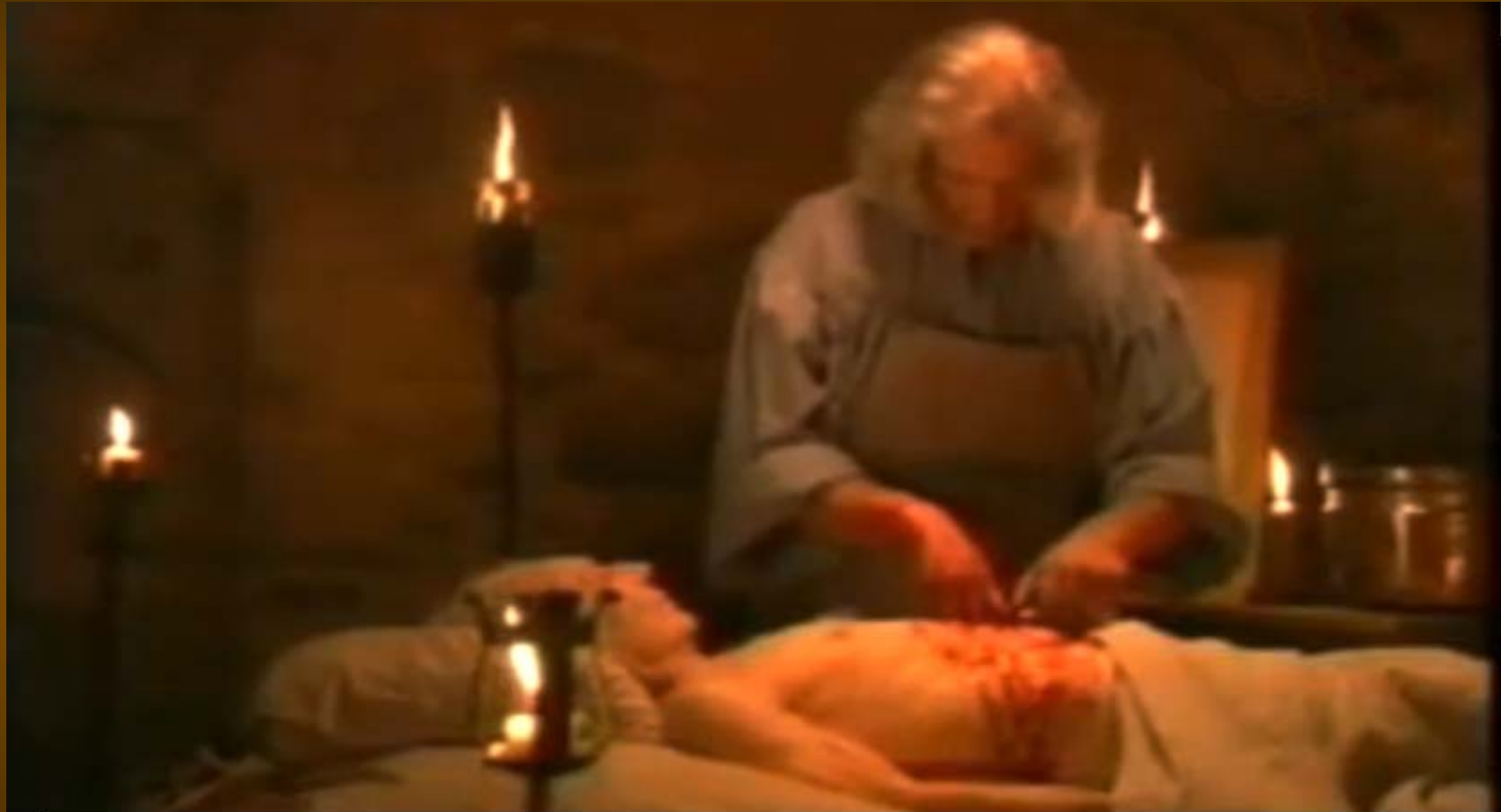Scritte
DA M. GIORGIO VASARI PITTORE
ET ARCHITETTO ARETINO,
Di Nume dal Medesimo Sculpe
Et Ampliare
CON I RITRATTI LORO
Et con l'aggiunta delle Vite de' vivi, & de' morti
Dall'anno 1550. infino al 1657.
Prima, e Seconda Parte.
*Con le Tavole in cui sono delineate, Delle cose più Notabili,
De' Lavori, Delle Vite degli Artisti, Et de
Lugli dove sono state loro.*

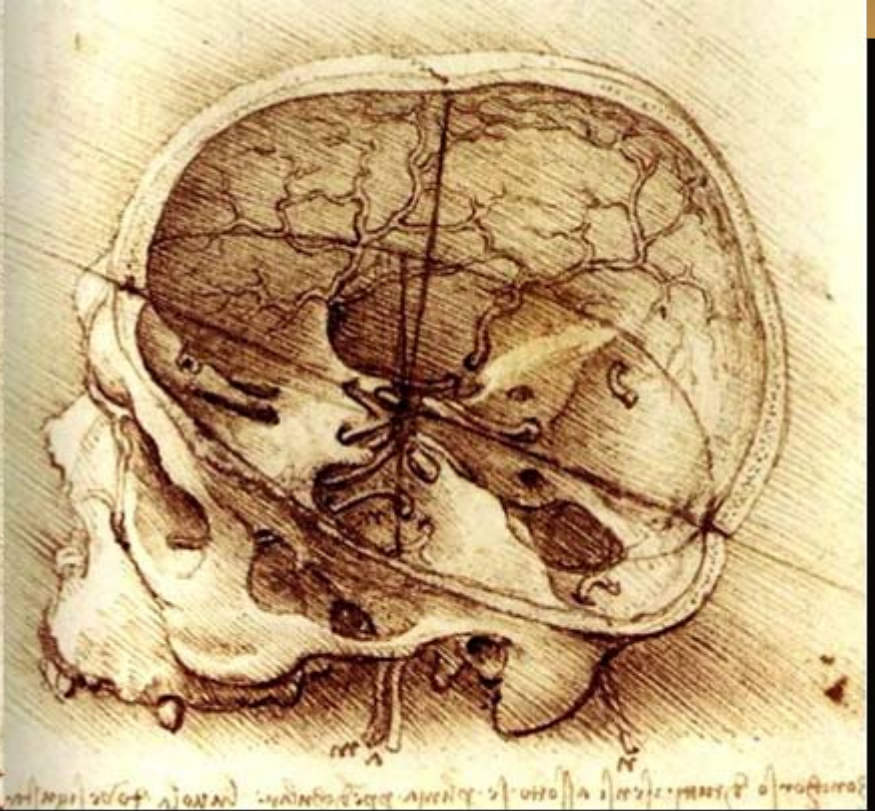
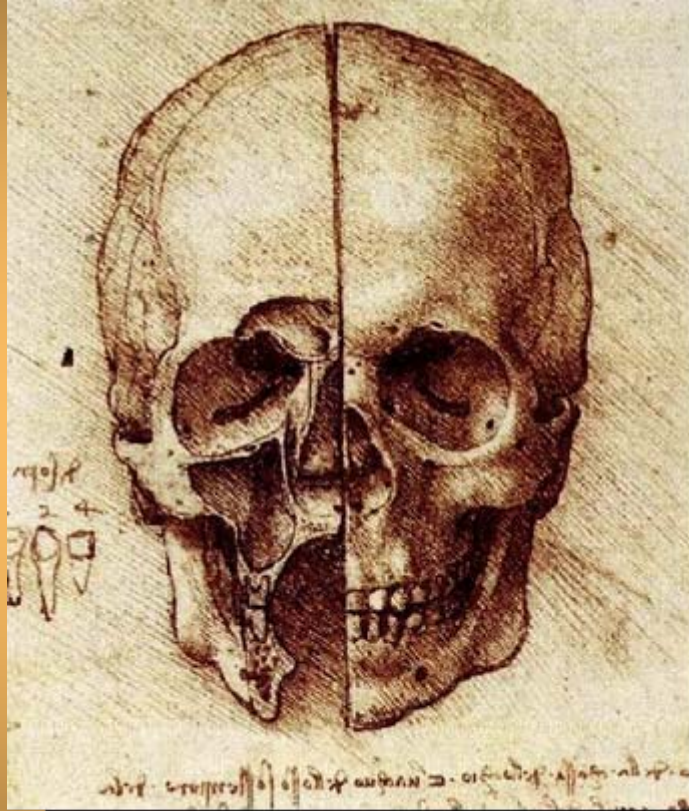
CON LICENZA E PRIVILEGIO DI A. S. PIO V. ET
DELLA CILIA DI FIRENZA E SIENA.

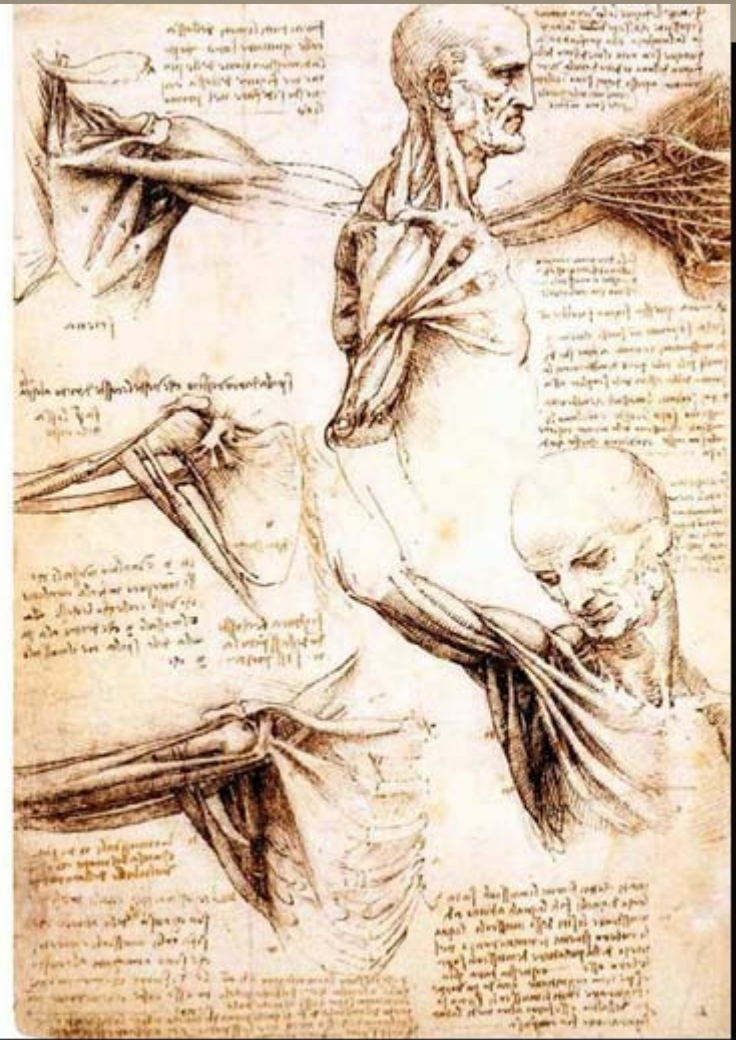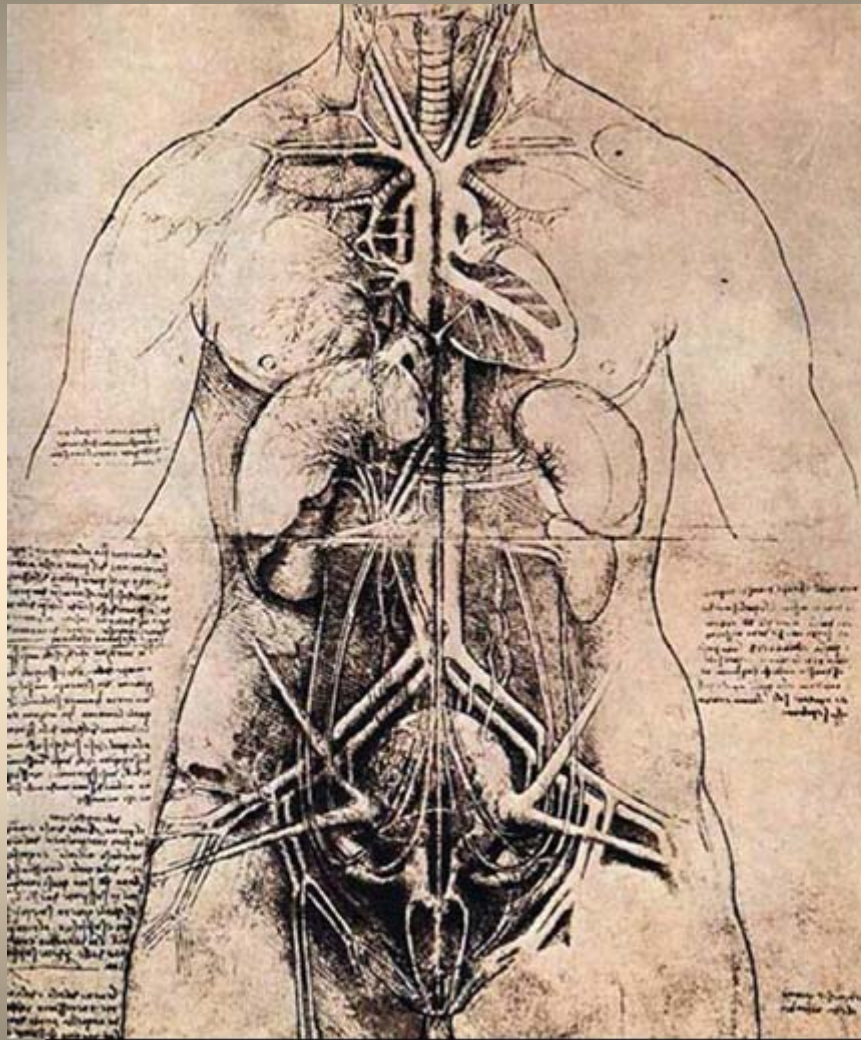


In Firenze, Appresso Gio: Battista









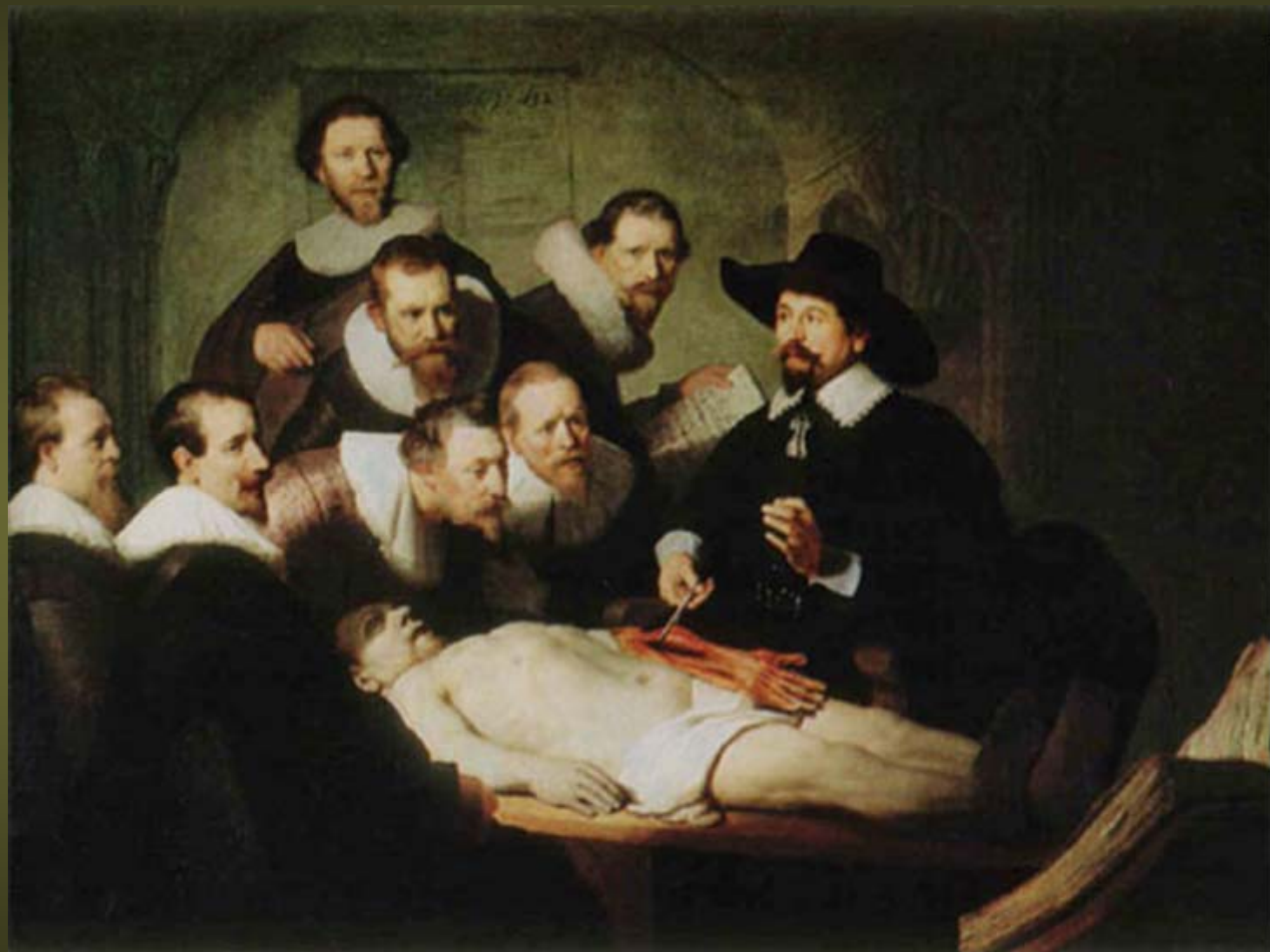
ANDREAE VESALII.



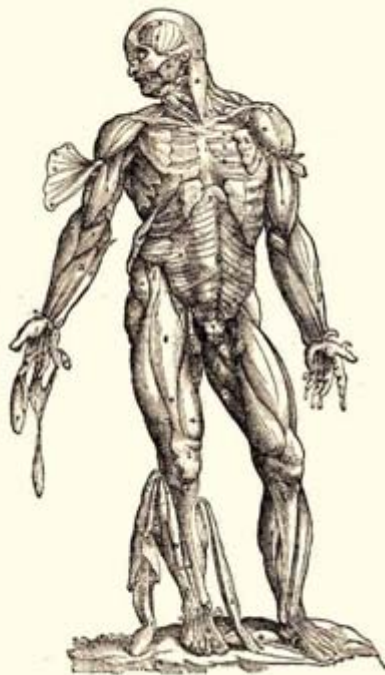

ANDREAE VESALII
BRUXELLENSIS, SCHOLAE
medicorum Patavinae professoris, de
Humani corporis fabrica
Libri septem.

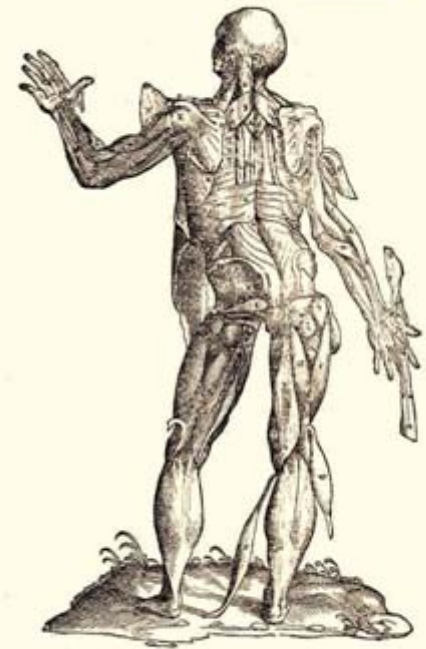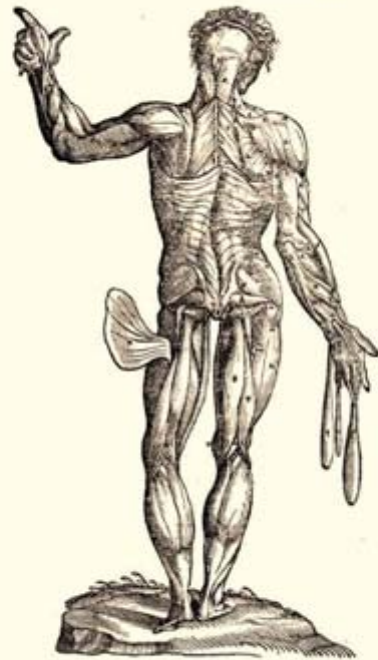MDLXXII
M. de B. Cellarius R. de P. de S. de V. de G. de
de G. de P. de S. de V. de G. de



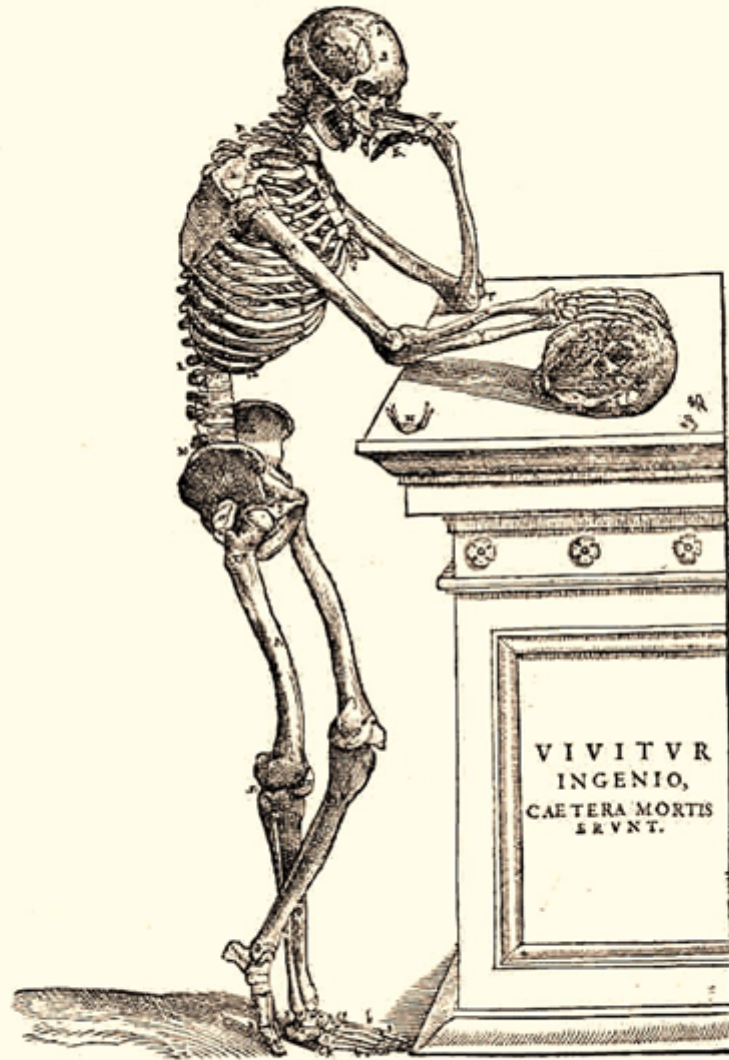




M 4



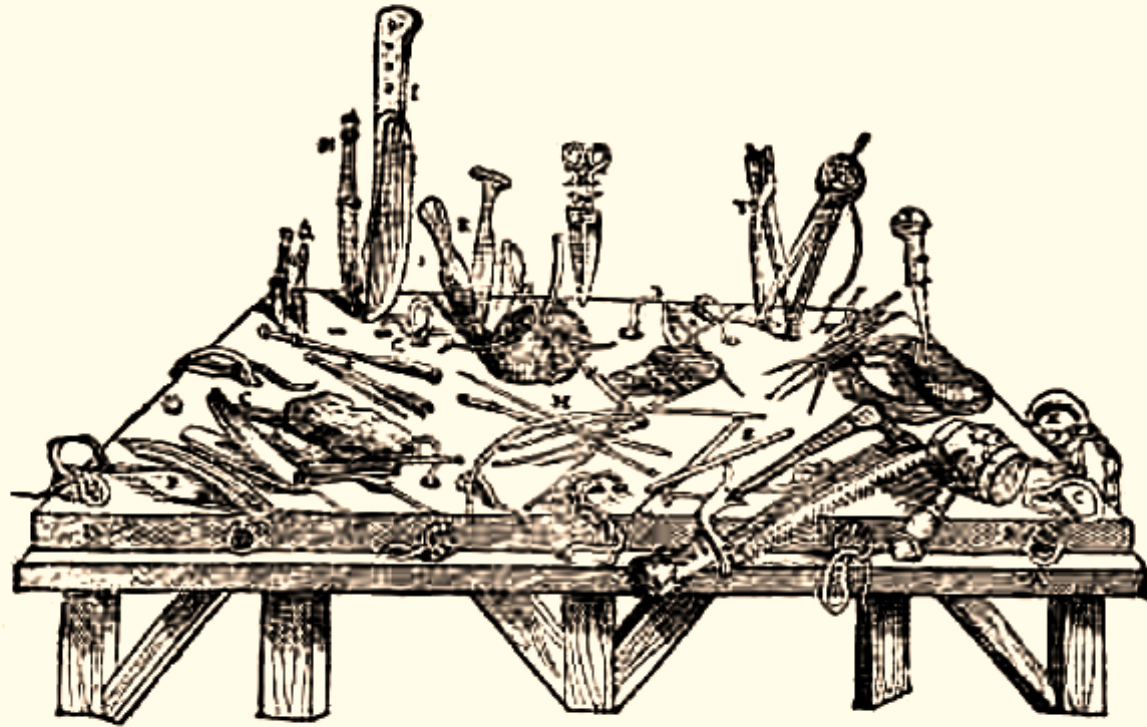
HUMANI CORPORIS OSSIVM EX LATERE DELINEATIO.



VIVITVR
INGENIO,
CAETERA MORTIS
ERVNT.

DE INSTRUMENTIS, QUAE ANATOMES STUDIOSO
debent esse ad manum. Caput XLI.

ANATOMICORVM INSTRUMENTORVM DELINEATIO.



QUADRAGESIMIPRIMI CAPITIS FIGVRARVM,
eiusdemq; characterum Index.

ANDREAE
VESALII
BRUXELLENSIS,

INVICTISSIMI CAROLI V. IMP.
MEDICI,

DE HUMANI CORPORIS FABRICA

LIBRI SEPTEM.

Cum Indice rerum & uerborum memorabilium locupletissimo.

~~FRANCISCI~~

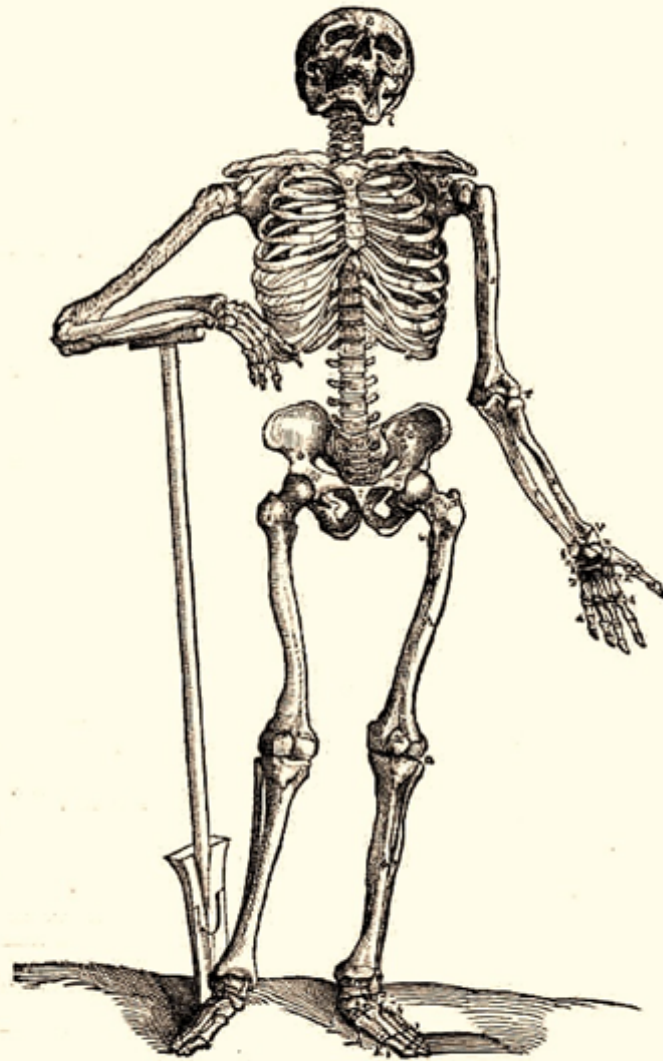


VENETIIS,

Apud Franciscum Franciscium Senensem, & Ioannem Criegher Germanum.

M D LXVIII.

HUMANI CORPORIS OSSIVM SIMVL
Costas thoracis anterior facies.

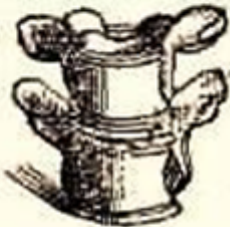

Ligamenta
vertebrarum
carum con-
nata sunt.
Cap. XL. lib.
de Offibus.



LIGAMENTA primam vertebram capiti, & secundam primæ, & secundam rursus capi-
ti colligantia, superius enarraui: quæ autem reliquas vertebra inuicem conuin-
dunt, nunc pertractabo, ab illis quæ vertebrarum corpora colligant, sermonis facturus ini-
tium. Inter secundæ itaque & tertie vertebæ cervicis, ac deinceps inter reliquarum om-
nium vertebrarum corpora, substantia quedam reponitur, quam Galenus cartilaginem
vocat, & qua vertebra inuicem hæc colligant, contra eorum qui illum præcesserunt disse-
ctionis Procerum sententiam, asserit, Nam non huius cartilaginis beneficio ipsas, committi uult, uerum ter-
tiz dorsalis medulla tunicæ, inter vertebrarum corpora se insinuans. Cuiusmodi uerò hæc sit, in dorsalis
medulle sermone persequar, tunc nimium, quando præter duas cerebri membranas, dorsali medullæ pro-
ximè aduatas, vertebrarum foramina, seu cavitatem (quæ dorsali uiam præbet) membrana quidam obis-

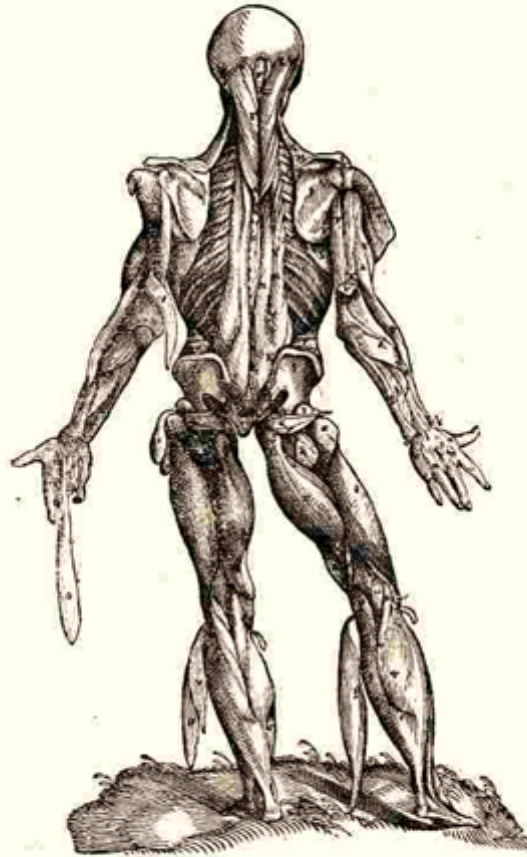
Ve leuari uentris, quæ hic pertracto, affoqueris,
dicas è diuersis uentris, uentris suis in partem
corporis vertebrarum. In quibus & uentris superio-
ris uentris carti-
laginem sui corpo-
ris inferioris ap-
pendicem, in quibus
corpora uentris
sunt. & eiusde uen-
tris humiliter
appellati sunt. & carti-
laginem ligamen-
tum, superioris im-
ferioris uentris appendicem intercedens. & superio-
ris inferioris uentris appendicem. & cartilaginem
distans uentris appendicem sui uentris caputem.



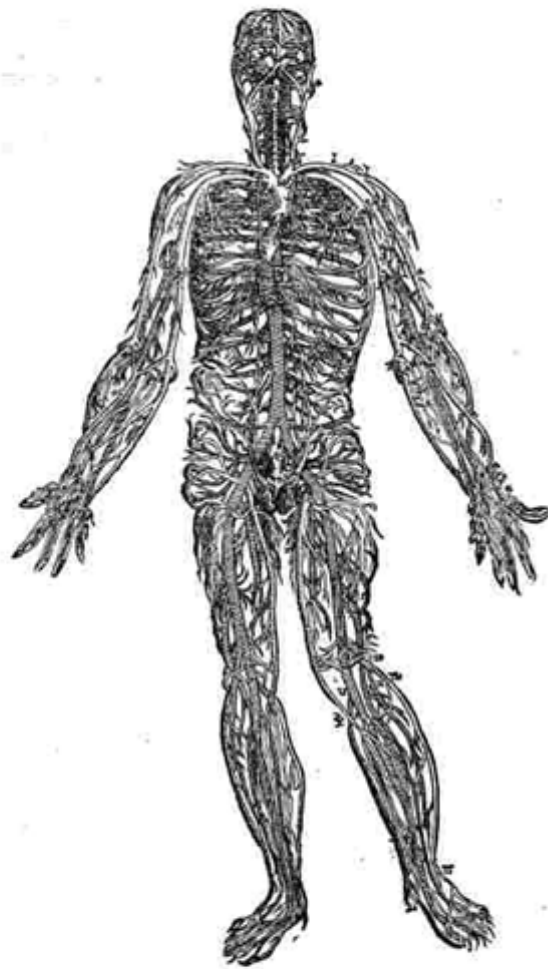
cul Galeni placito, iturus ex quoque tibi persuaderi sinez, membranam quandam, cuius beneficio uer-
bræ

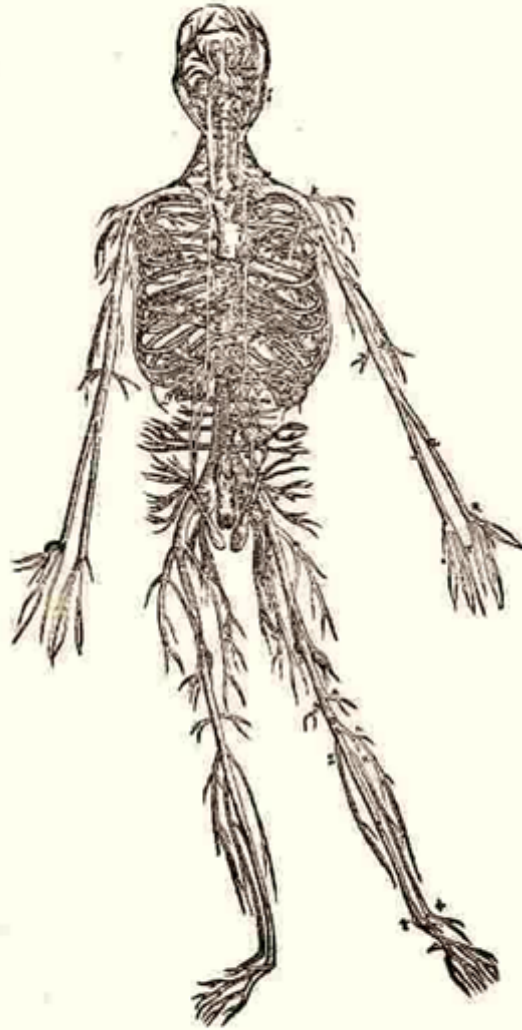
a Sci. 70.
d. 209; das
etiam ligam-
entum seu
quod quis
ad ostiæ cir-
constrictionem
sinez
posset, præ-
sente nobis
his licet: quare
etiam
ad ostiæ
fieri
c. p. 22. 24
lib. 1. 2. 3.

DUODECIMA MUSCULORUM TABULA.



INTEGRA ET AE OMNIBVS PARTIBVS
Libra nona. causa delineatio.

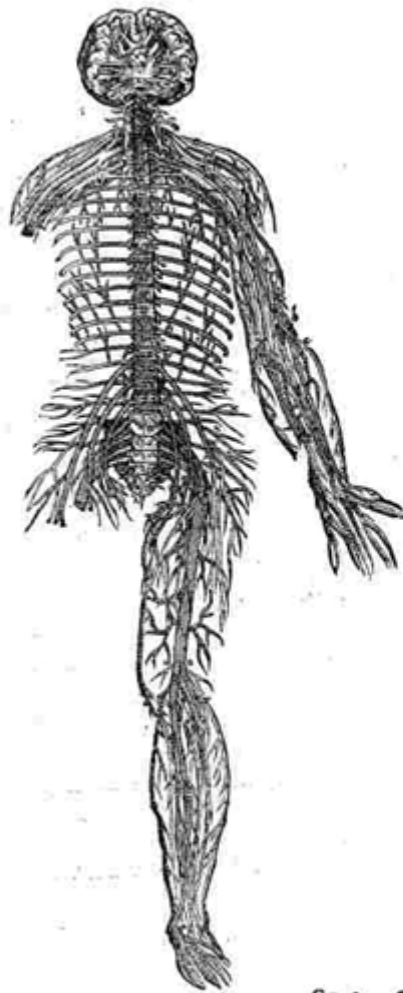


INTEGRA TOTIUS MAGNAE ARTERIAE AB
omnibus partibus libera delineatio.

NERVORUM DELINEATIO. QUAE SEPTEM
 partium nervorum qui à cerebro & dorsali medulla initio prouaduntur
 ortus propago, & distributionem seriemq; omnium partium qua
 à dorsali medulla in dorso ossibus complexa originem
 ducunt, pulcherrime refert.

- M** Quartus pars.
N Quinti partis gracillior radix.
O Quinti partis infusior radix.
P Membrana, in quam quintum par
 ta auditus organo praecipue exor-
 titur.
Q Minoris quinti partis radix propa-
 gina, quarum hae per eadem ela-
 batur foramen, illa uero per aliud si-
 bi proprium.
S Sextus nervorum pars.
T Septimus nervorum cerebri par.
 Atque horum nervorum progres-
 sus hic ubi delineari potuerunt ele-
 gantissime proponuntur secunda fi-
 gura, huius libri secundo Capiti
 praeposita.
V Dorsalis medulla ex cerebri basi
 medio mittitur.
X Dorsalis medulla sedes, qua cala-
 rian excedit.

1. & 2. **Q** Noneri characteres systeme cer-
 uicis, duodecim thoracis, quinque
 lumborum, & sex sacri ossi indi-
 cant vertebrae, atque ad id triginta
 nervorum à dorsali medulla unum
 illis vertebriis contraria profusa-
 tionem paria, quorum seriem quum
 potui accuratissime & simplicissi-
 me in hac tabula meo more expressi
 si. Verum quia hic locus exigentem
 characterum declarationem admittit
 et non omnes nervorum foveles li-
 teris inscribere sum.
3 Septi transversus sinister nervus, qui
 extra aliam characterem operi ex
 quarti, quinti & sexti partium pro-
 paginibus efformari conficitur.
4 Nervus à quinto pari, cuius summa
 lumborum musculi, & deus mu-
 sculo brachionis attollenti praecipue
 distribuitur.
R Primus brachij nervus, ipsiusque
 propago hic in cutem excurrente.
5 Secundus brachij nervus, ipsiusque in
 anteriorem cubiti flexionem mus-
 culum foveles.
T Tertius brachij nervus, ipsiusque
 propago, cuius anteriorem brachij
 sedem videmus oblata.
V Tertij nervi propago ad posterio-
 rem musculum cubiti flexionem
 mittitur.
X Secundi nervi portio, tertium acce-
 dita nervum.
Y Quinti secundij nervi caput adiens
 longiori radice in primum muscu-
 lum musculi.
Z Secundi nervi distributio in duo
 impares ramos.
6 Minor rami secundum radium cui
 ad pollicem usque exproccit.

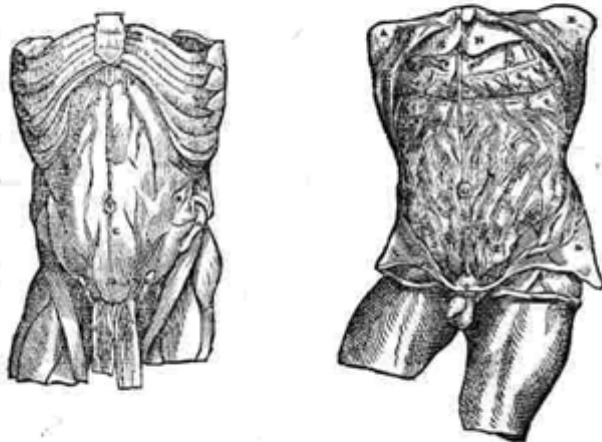


Gg a Crasler

ANDREAE VESALII, DE CORPORIS HVMANI FABRICA LIBER QVINTVS,

ORGANIS NVTRITIONI, QVAE CIBO POTVQVE FIT, ET DEIN
PROPTER PARTIVM CONNEXVM AC VICINIAM
instruendis generationi faeculamentibus dedicatur, & omnes sibi peculiarias figuras
seriatim simulq; mox in initio ostendens, quo minus ex dem figuræ
plurimæque Capitis passim præponende ueniunt.

PRIMA QVINTI LIBRI FIGVRA. SECUNDA QVINTI LIBRI FIGVRA.



PRIMAE FIGVRAE, EIVSDEMQUE CHARACTERVM INDEX.

PRÆSENTI figuræ tantæ humani corporis parte delineatur, quanta ad peritonæam ostendendam sufficit
expressitur enim hic anterior peritonæi sedes, scilicet seritæ ab illo abdominis musculi libera, nullæque ex parte
dissita.

A. A. C. D. His characteribus peritonæam insignitur.

E. L. Linea à mucronata pectoris ossis cartilagine ad pubis usque ossium coniunctionem procedens, cui obliquè descenden-
tium & obliquè ascendentium, & transversim procedentium abdominalis musculorum nervosa tenuitates peritonæi
sunt commiscuitæ.

F. Umbilicus, quoniam inter differendam etiam ademptis abdominis musculis, gratia opportuna umbilici uasorum deman-
strationis, referre solemus.

G. Semihæra sinistri lateris uasæ, suis membranis, quas à peritonæo mouentur, adhuc obvoluitæ.

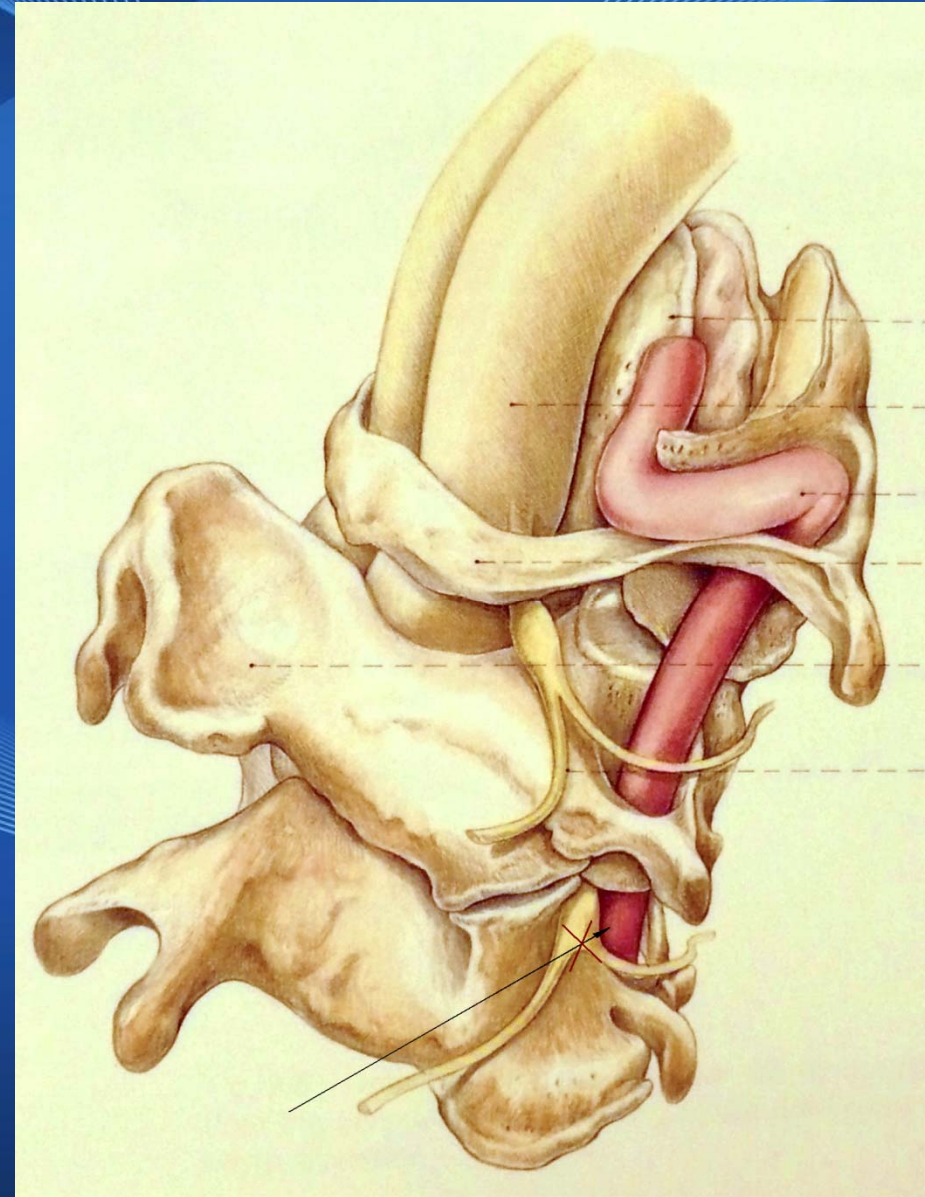
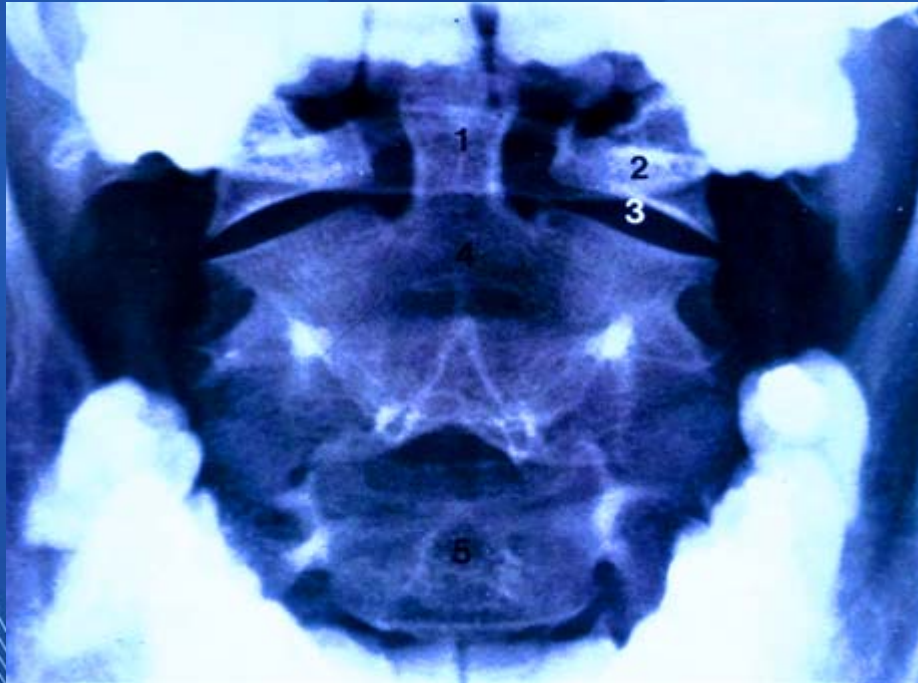
H. Semihæra dextri lateris uasæ.

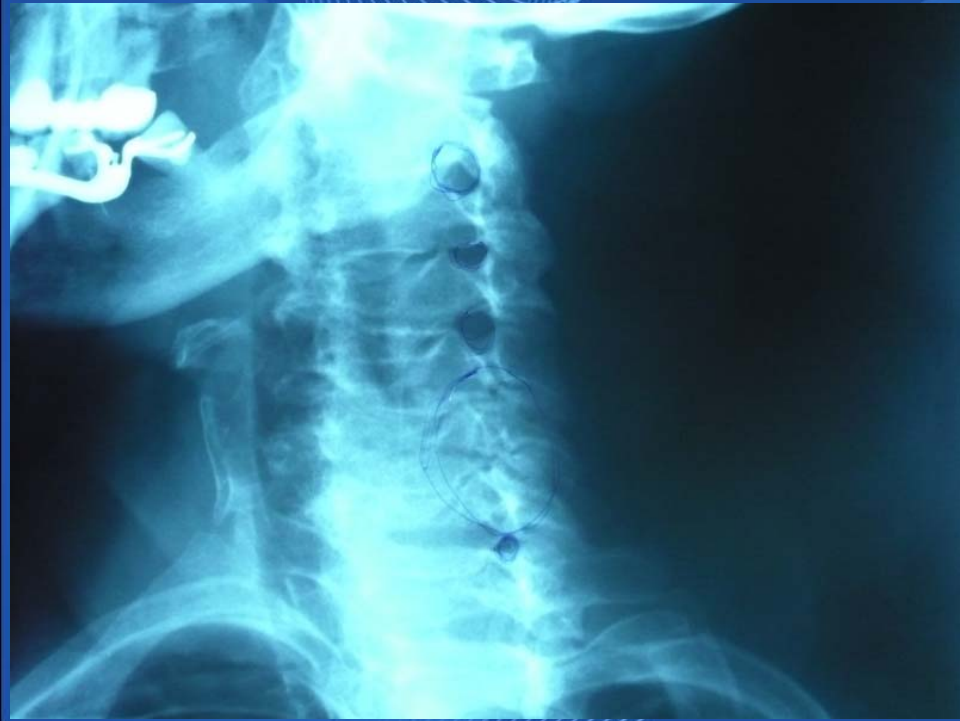I. Venæ arteriæque postquam inferiori stadi restituta abdominalis musculorum exspurgantur, quorum & hic quo-
que præsedat portio, pubis ossibus adhuc connexa.

X. Venæ & arteriæ, quæ sub ossis pectoris exsertæ, in anteriorem abdominis fidem prælabuntur, præcipuè rectus ab-
dominis

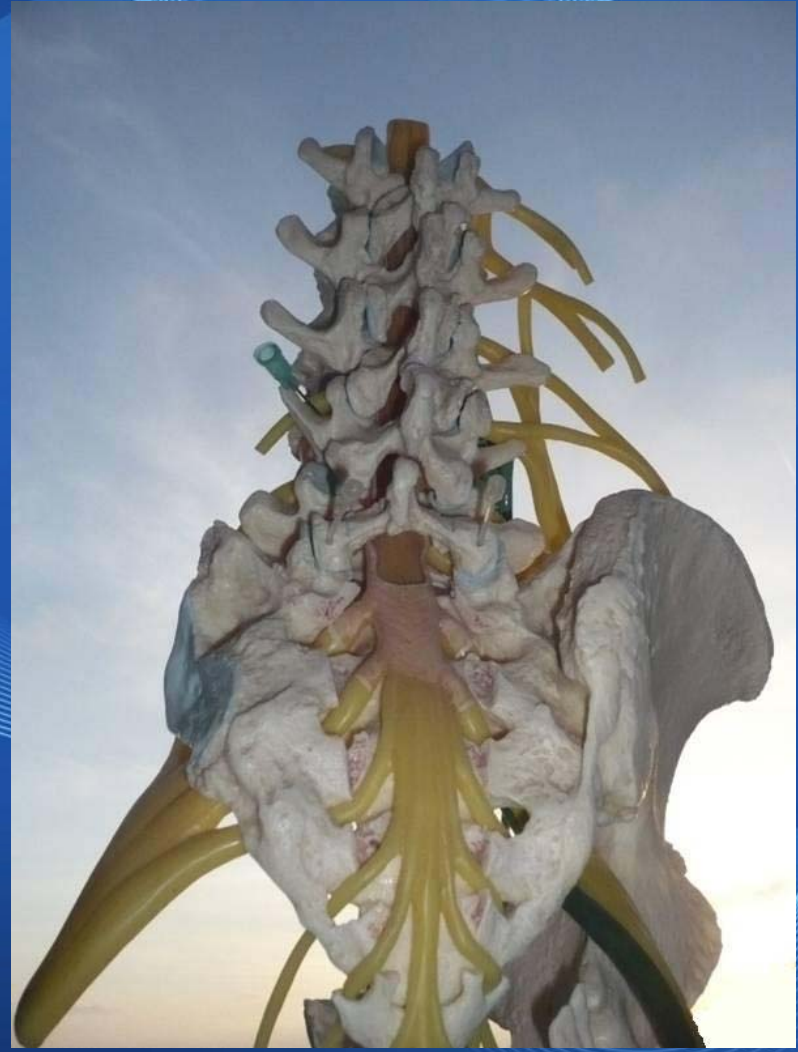
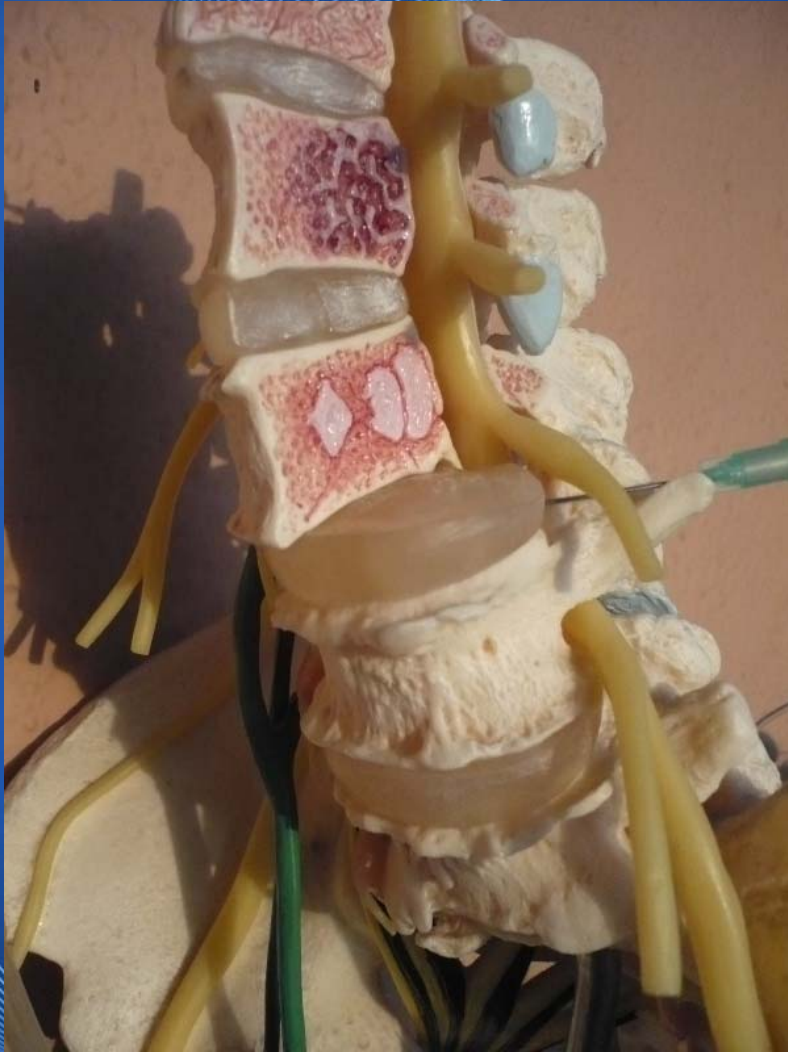
Radiología y Anatomía profunda

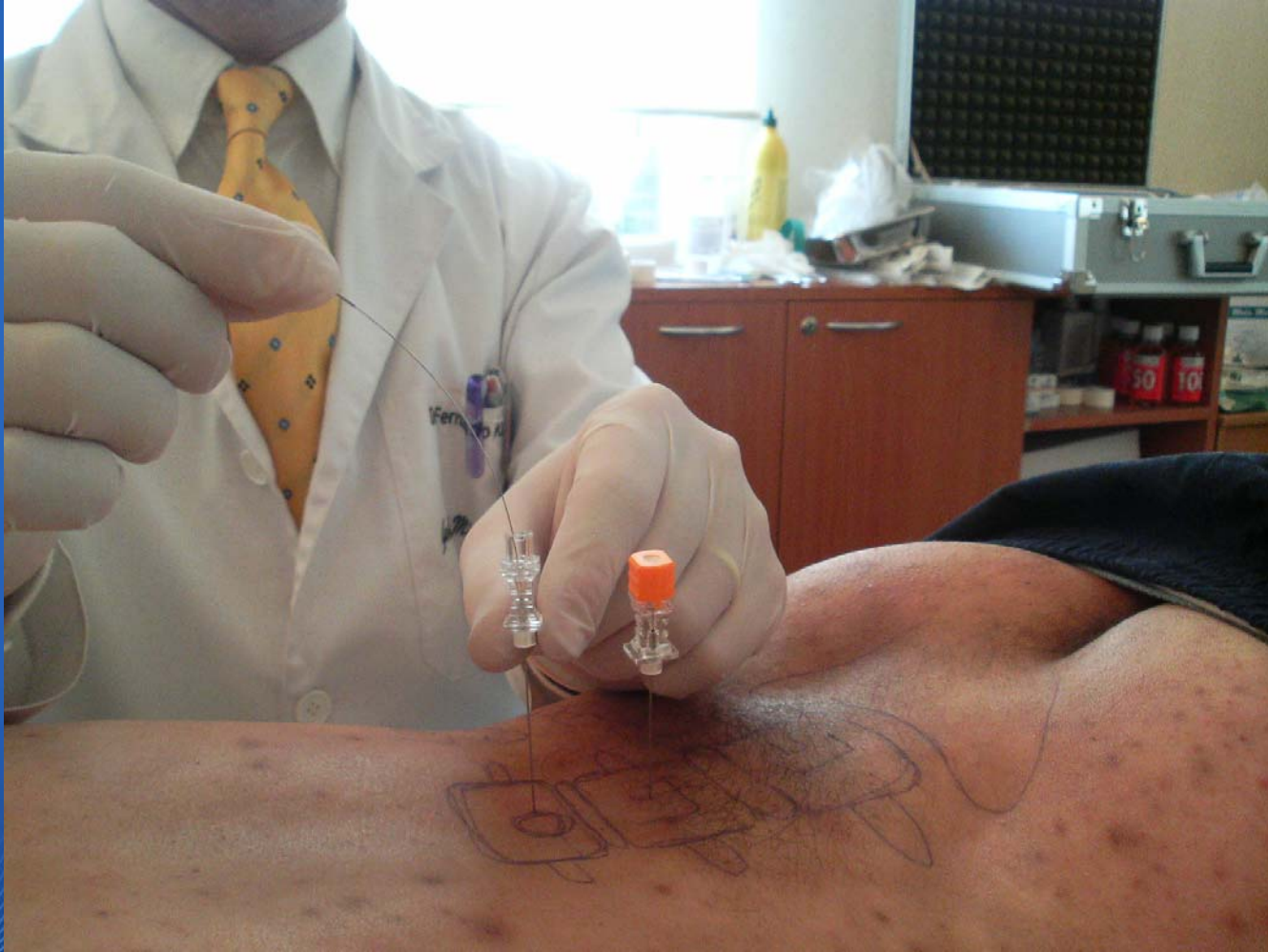



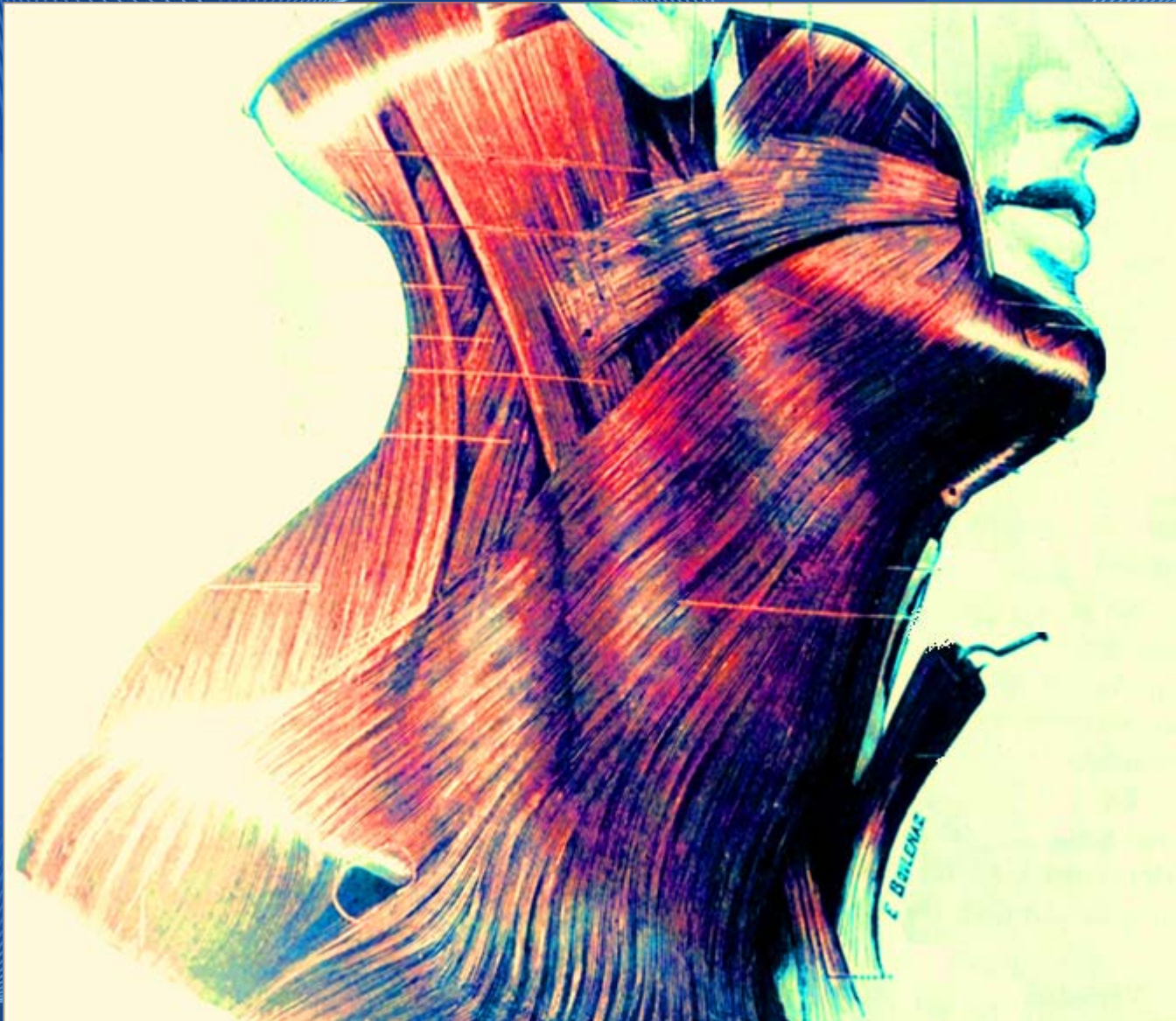Anatomía en el espacio



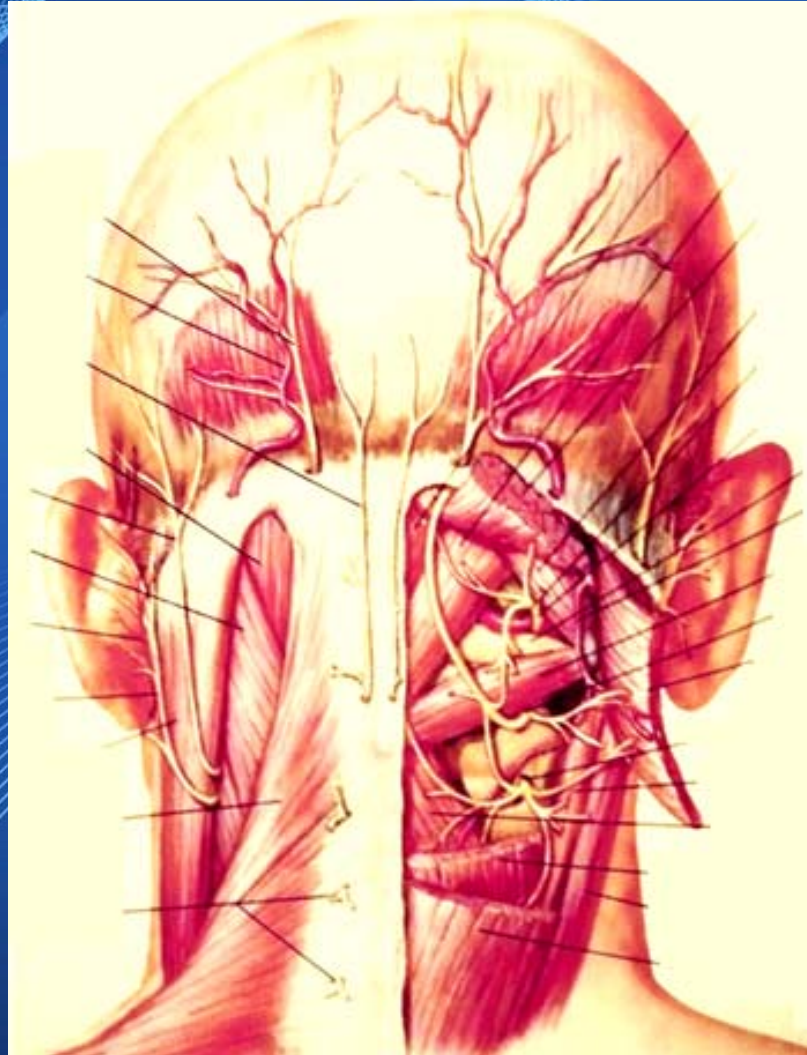
Anatomía en el espacio



Musculatura de Superficie



Referencias Anatómicas Cutáneas- Musculares



Musculatura Profunda

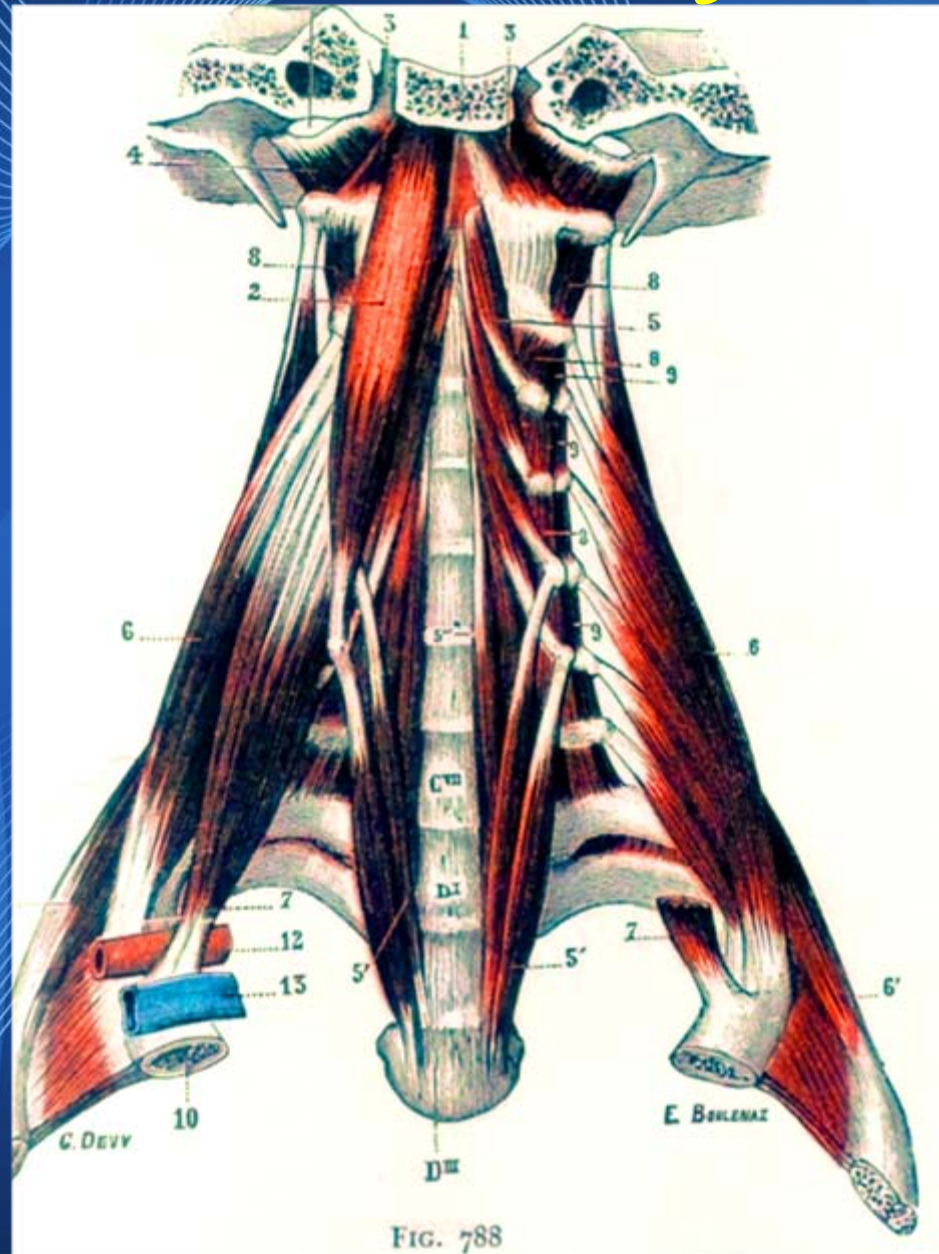
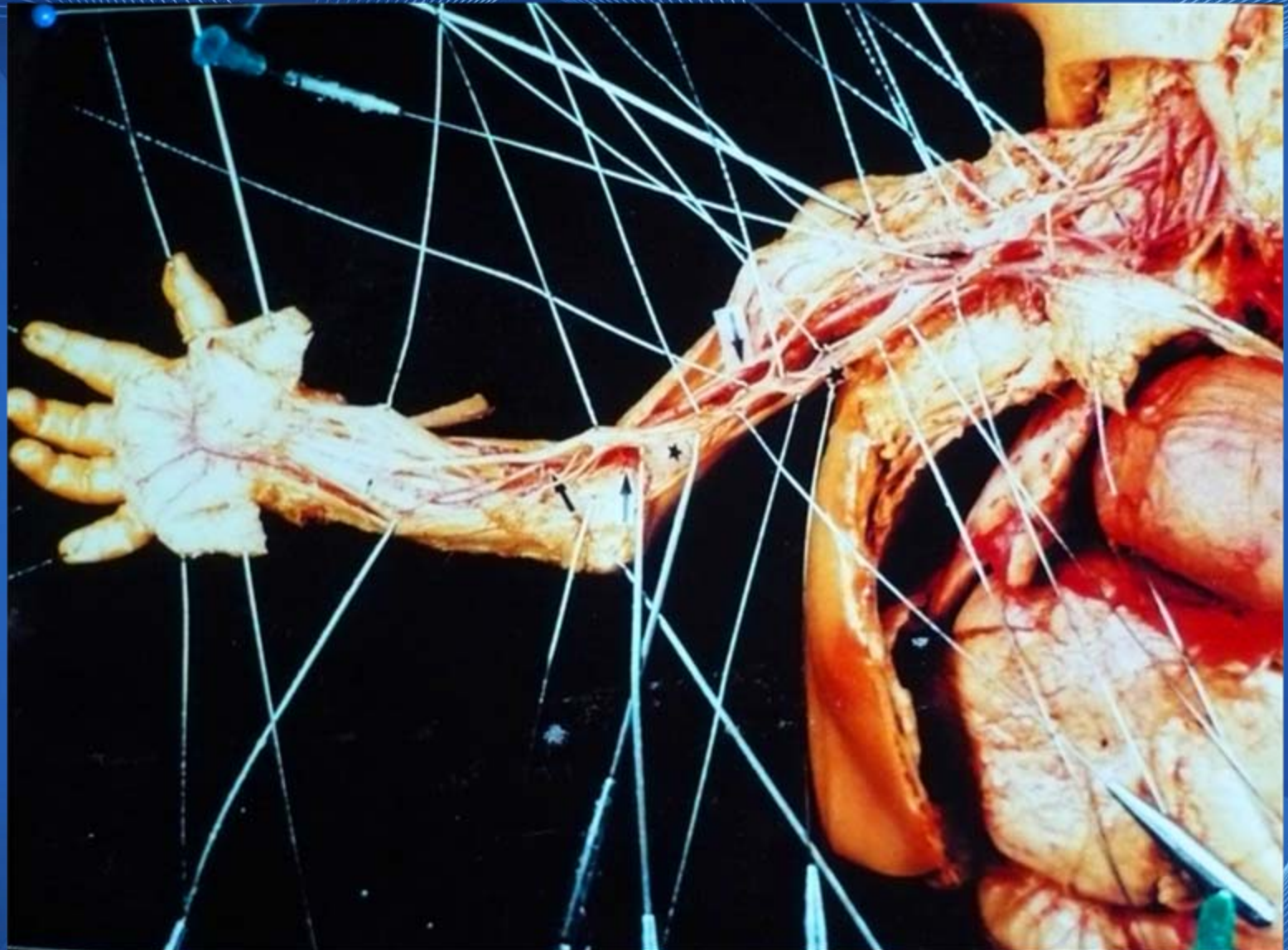
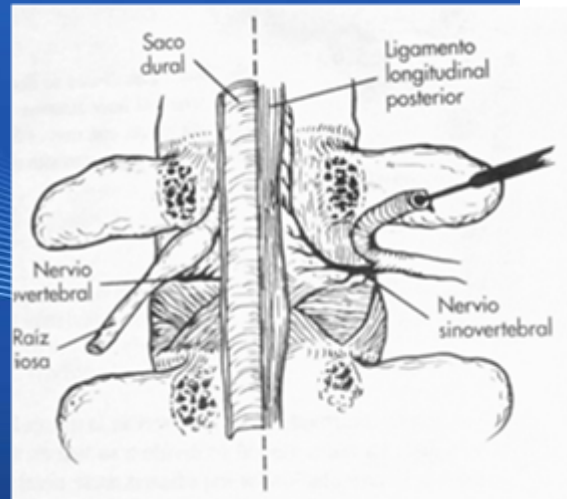
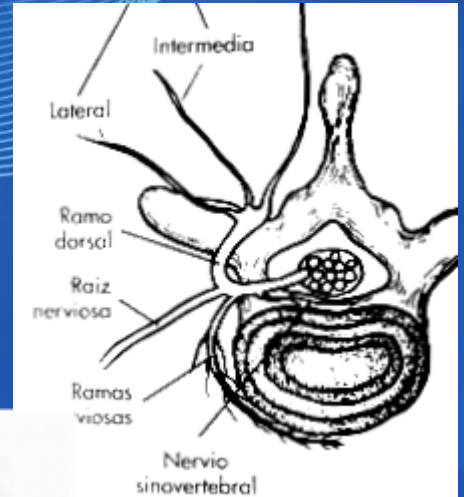


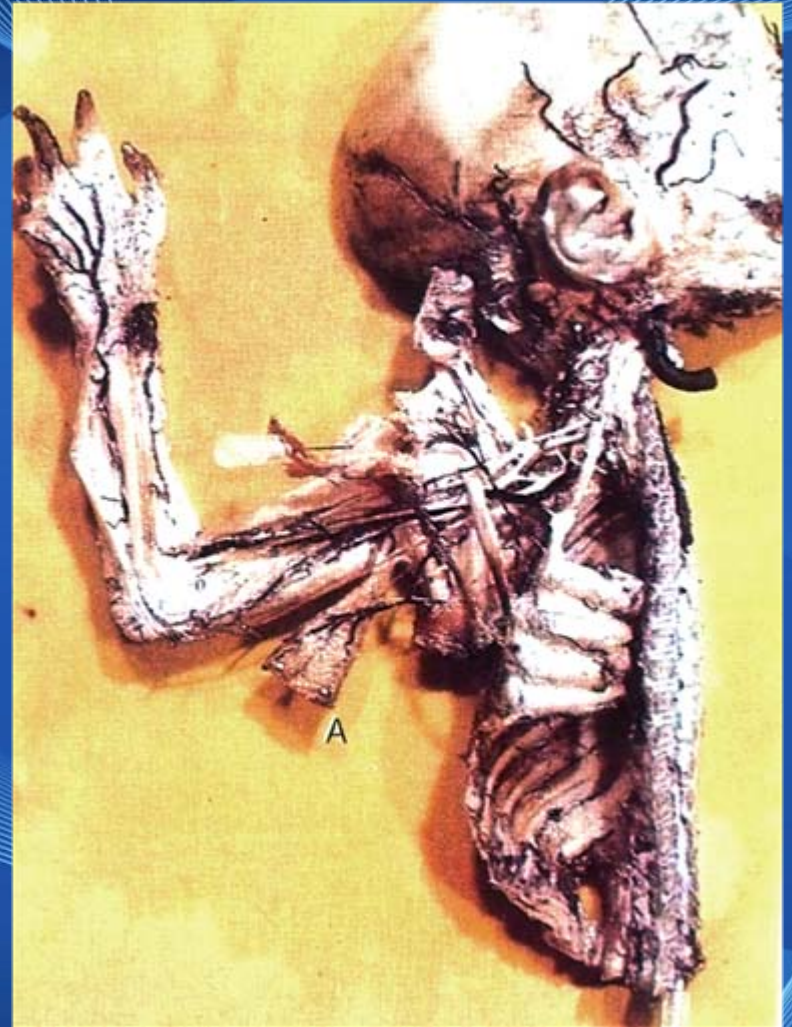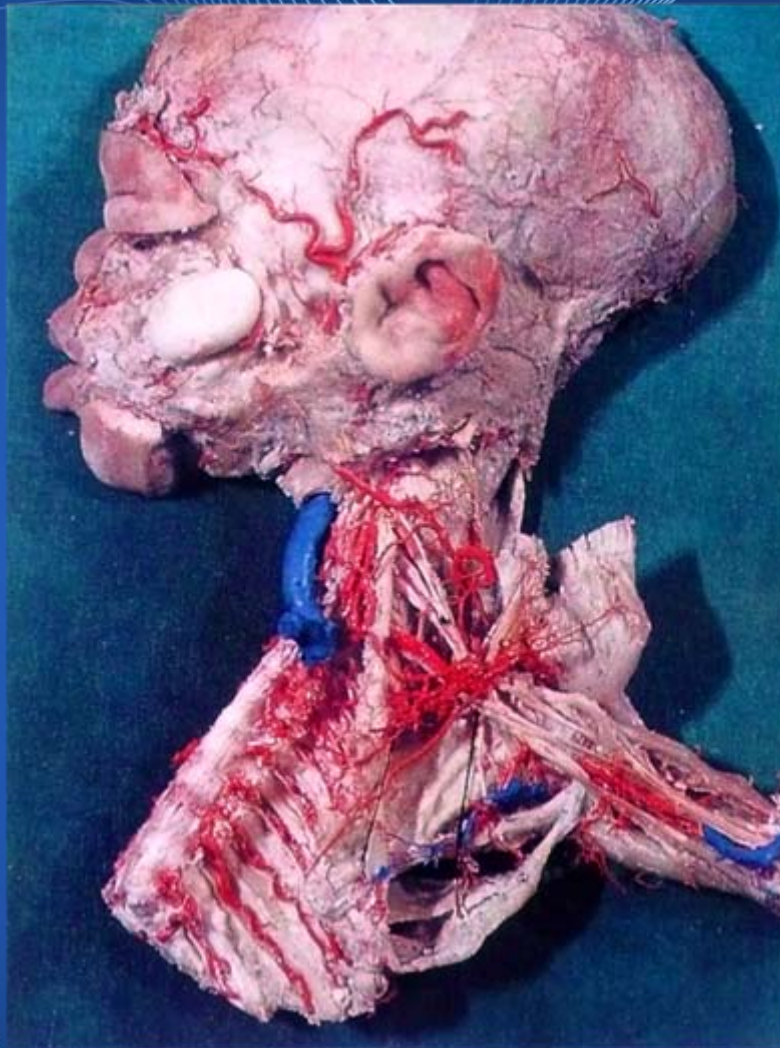
FIG. 788



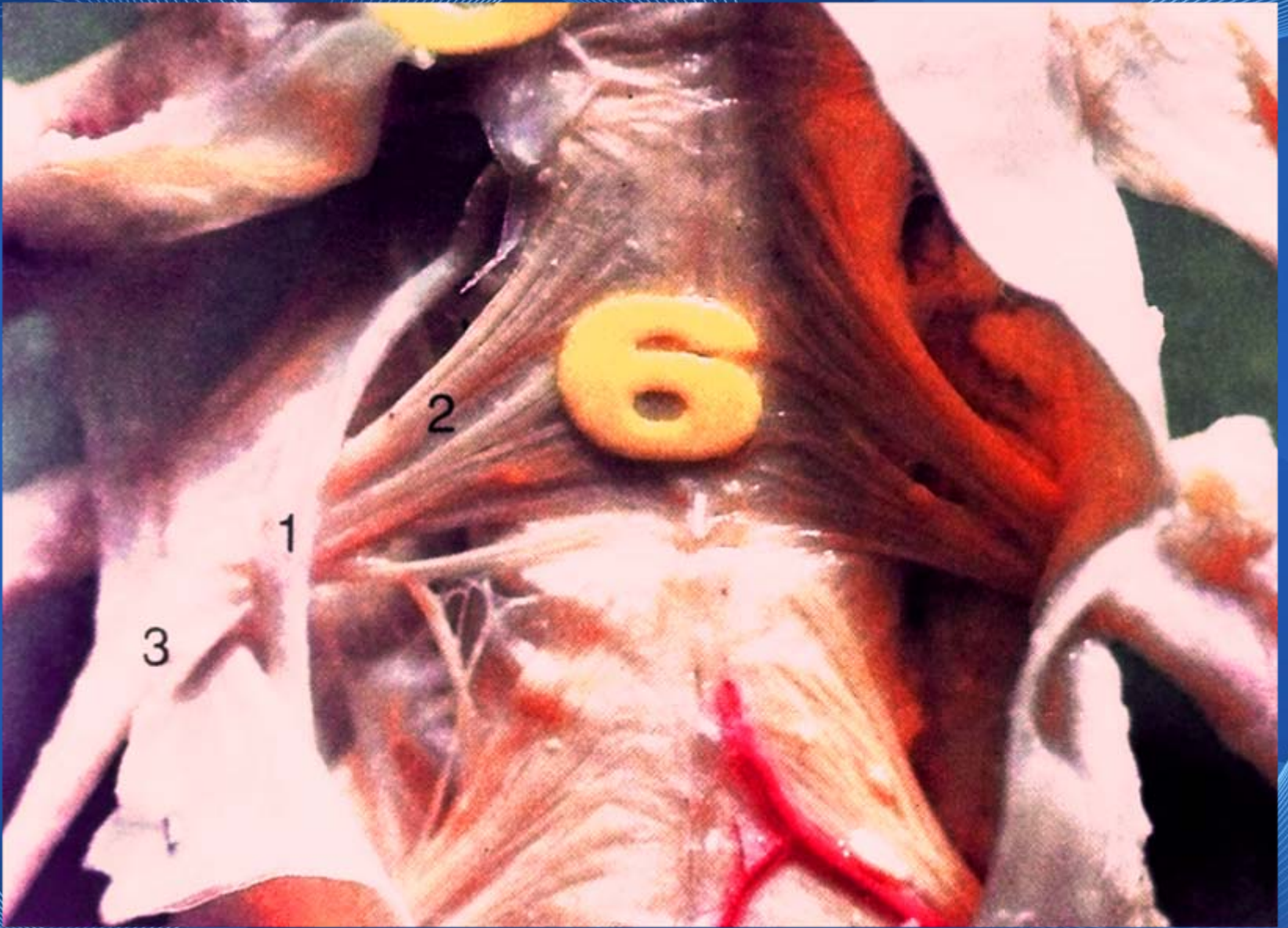Hubert Von Luschka

(1820-1875)





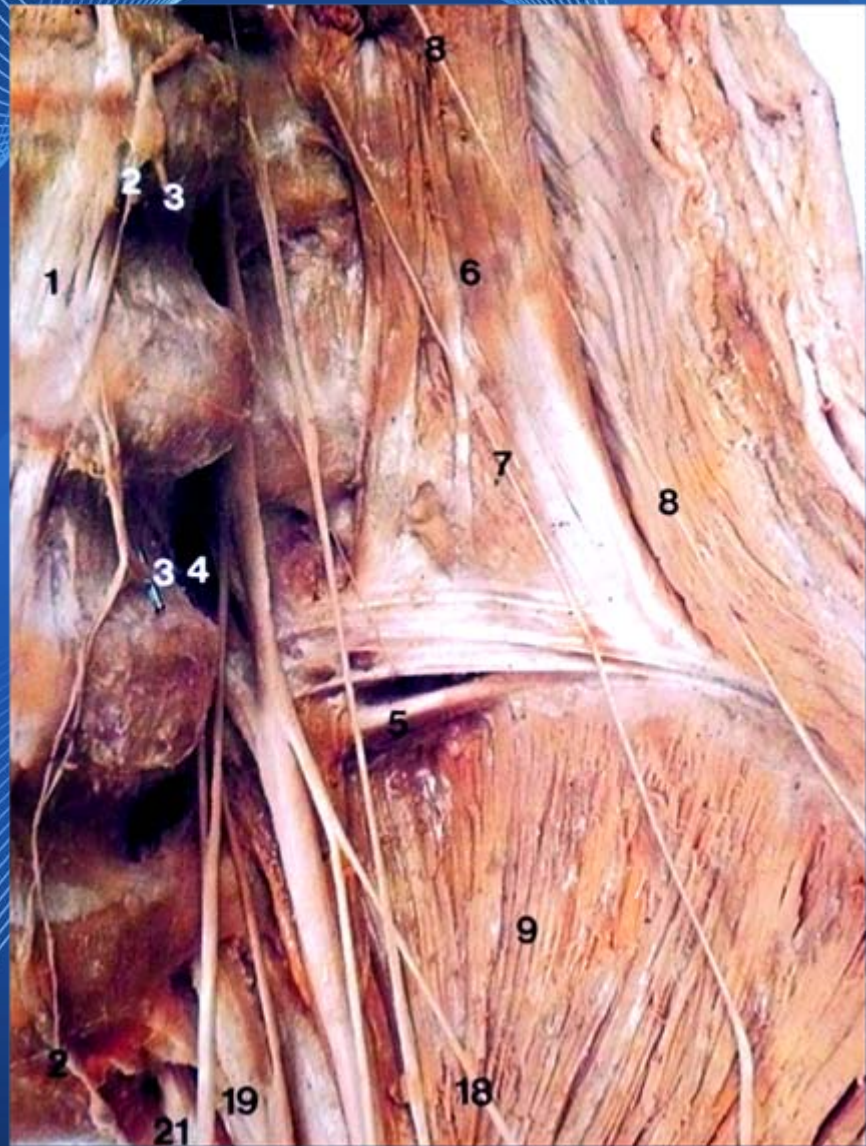



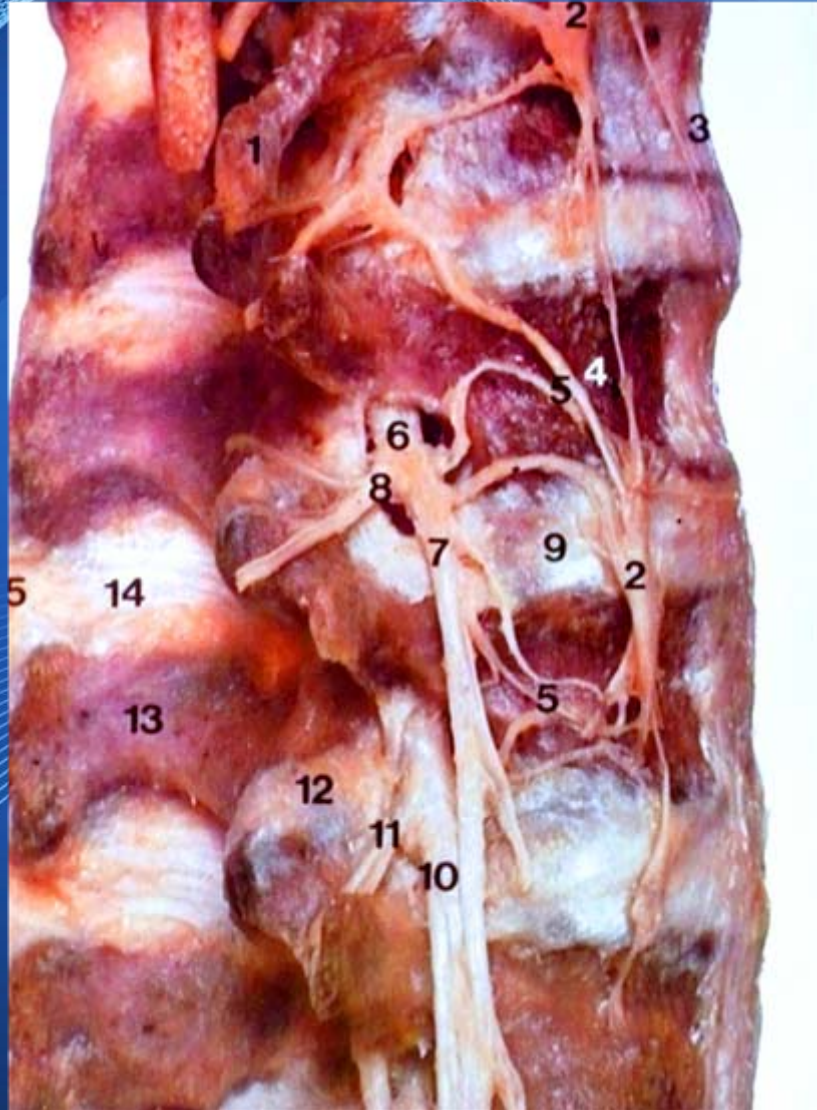


*Nuevas Técnicas en
Ozonoterapia*

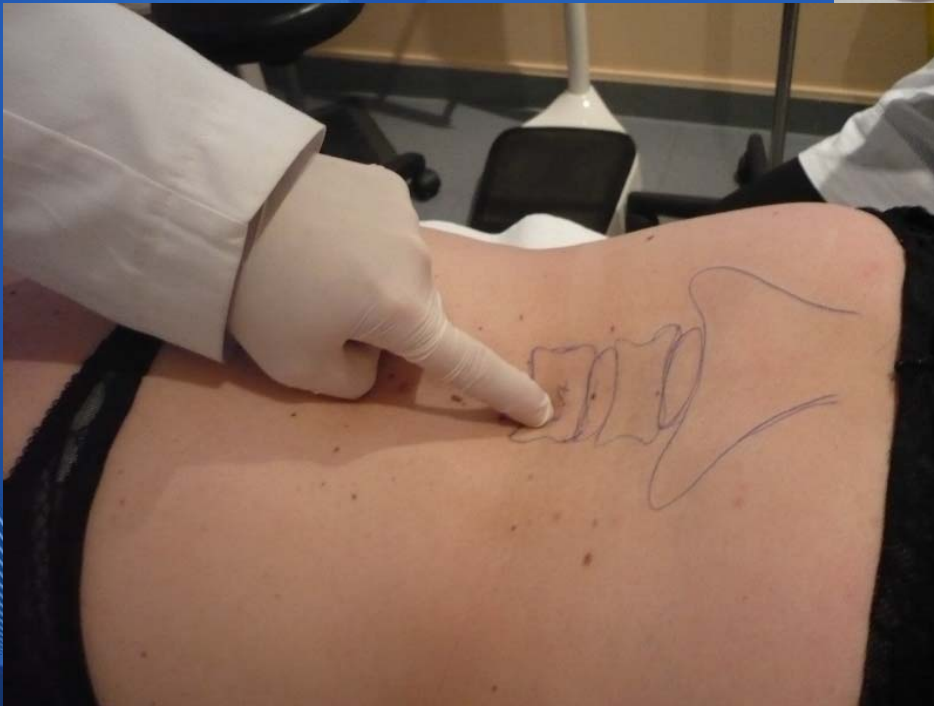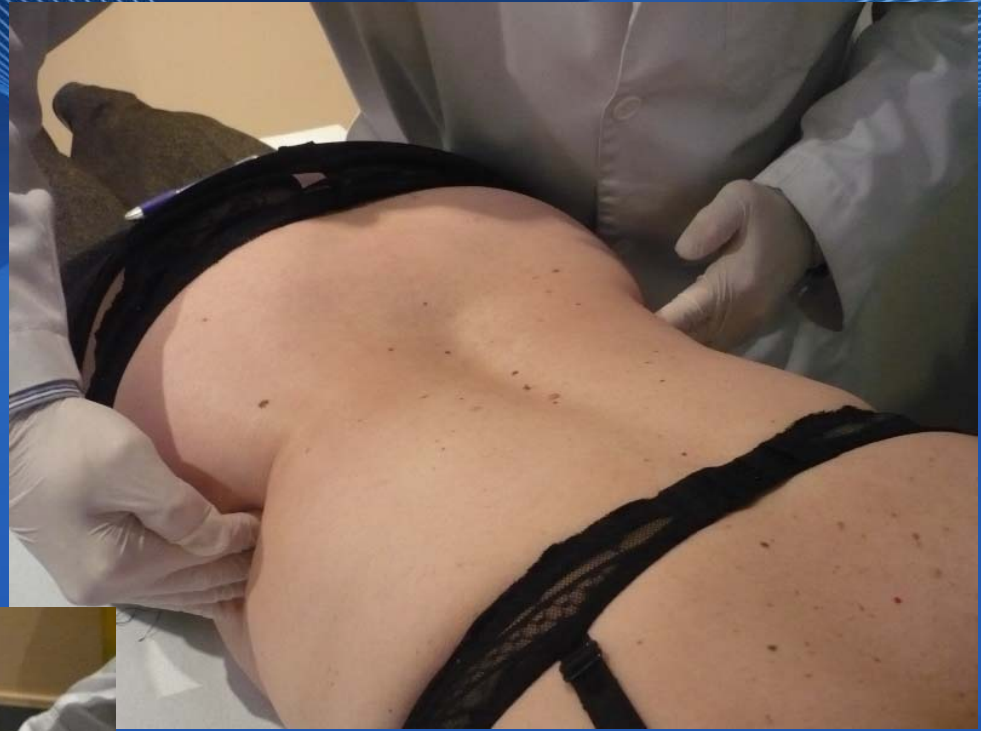Plexo Lumbo-Sacro



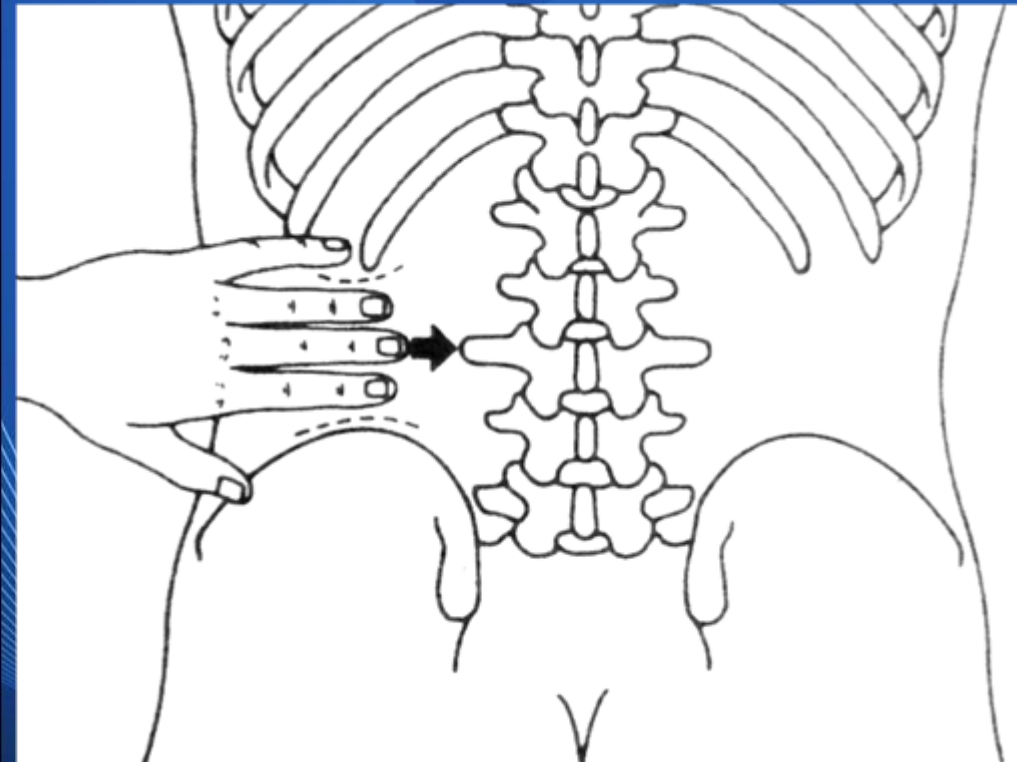
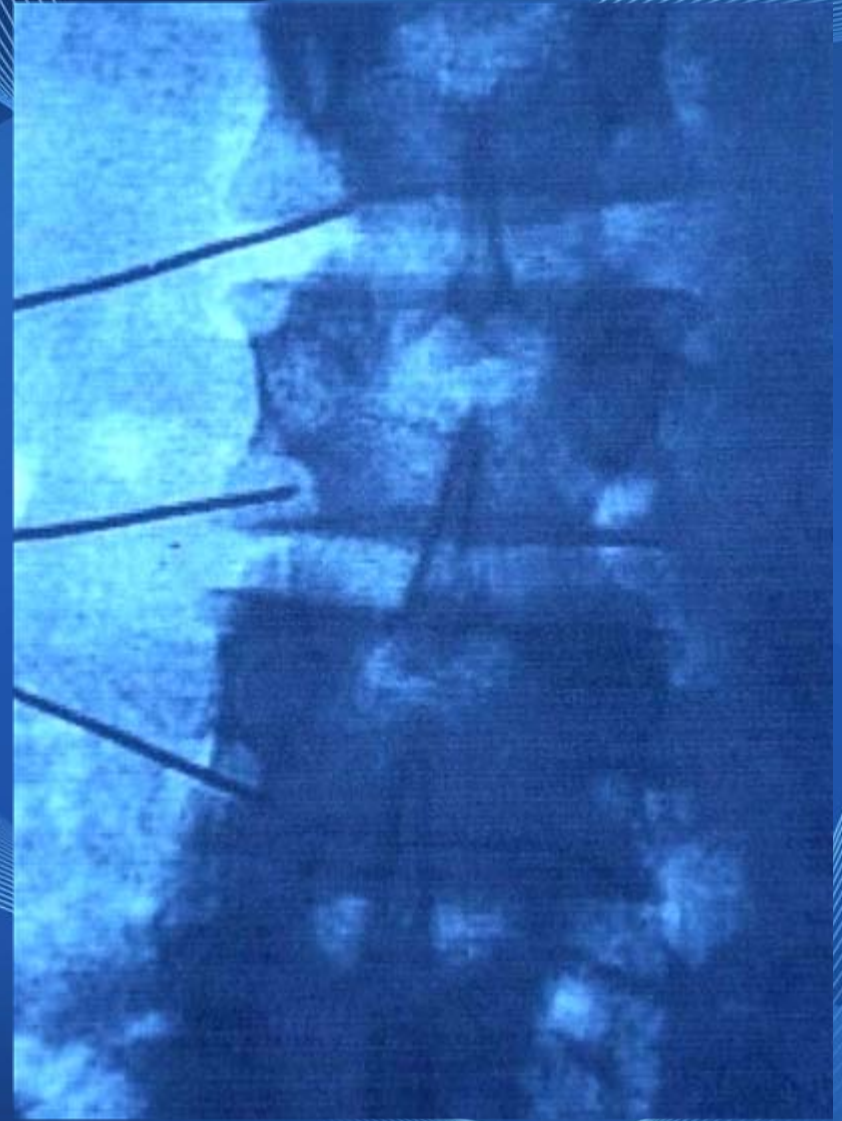Cadenas Simpáticas Paravertebrales

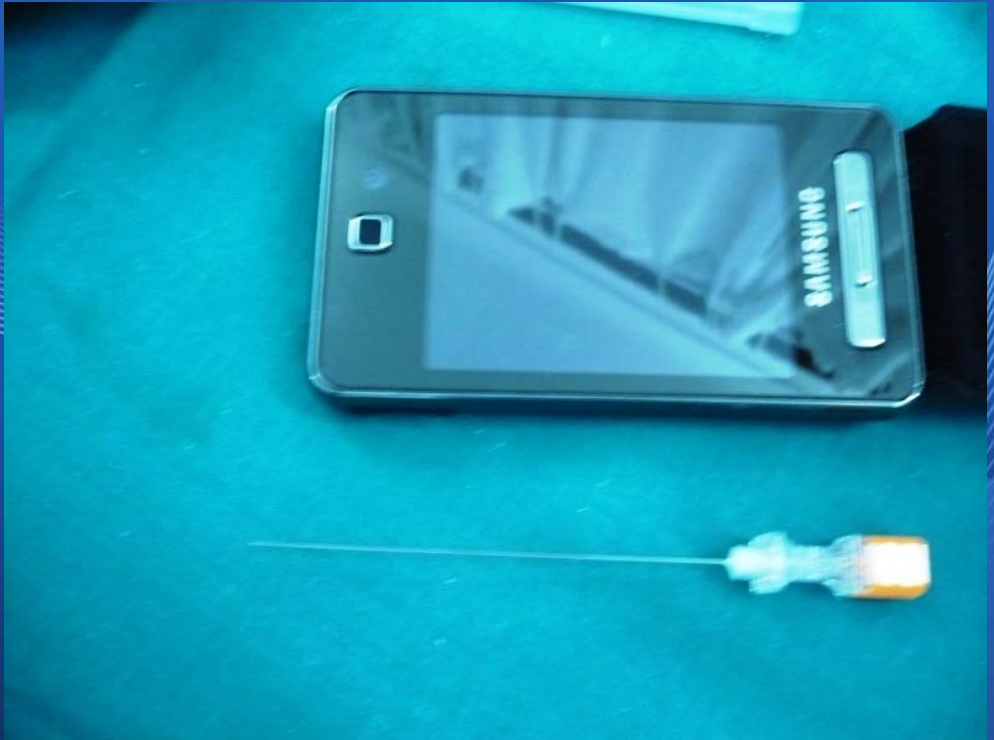
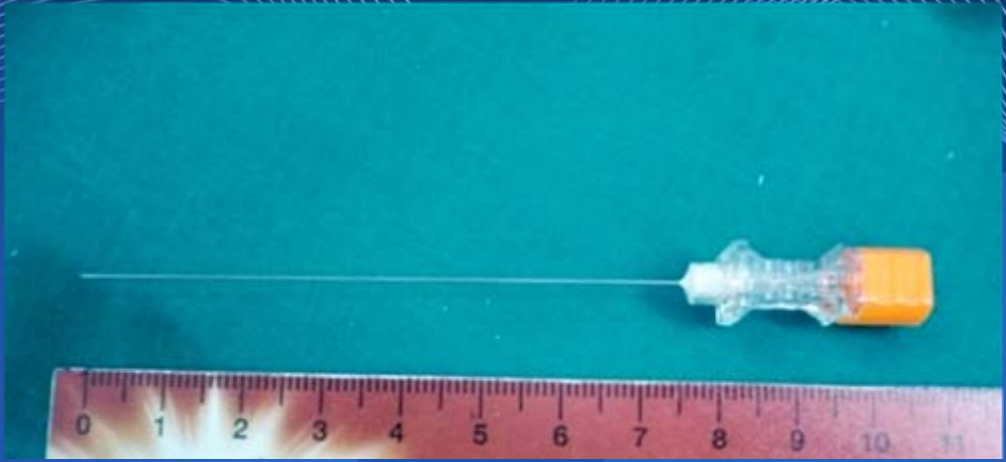


Referencia de Superficie

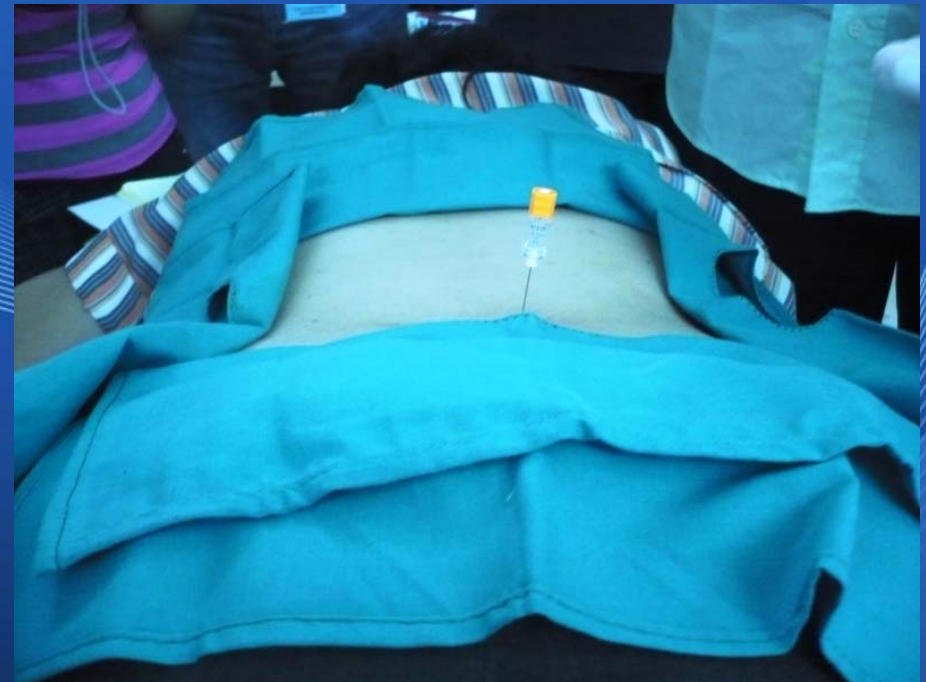
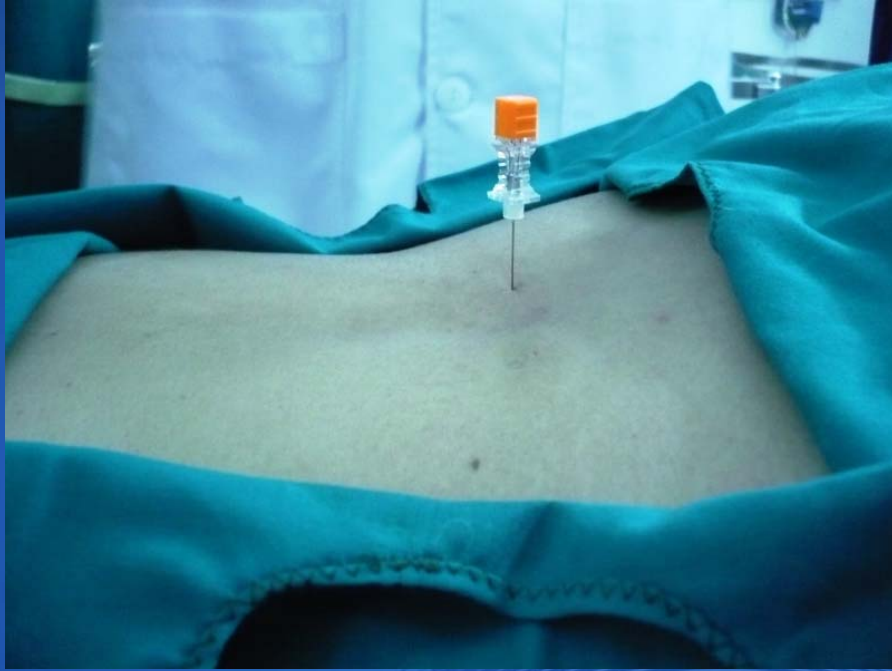
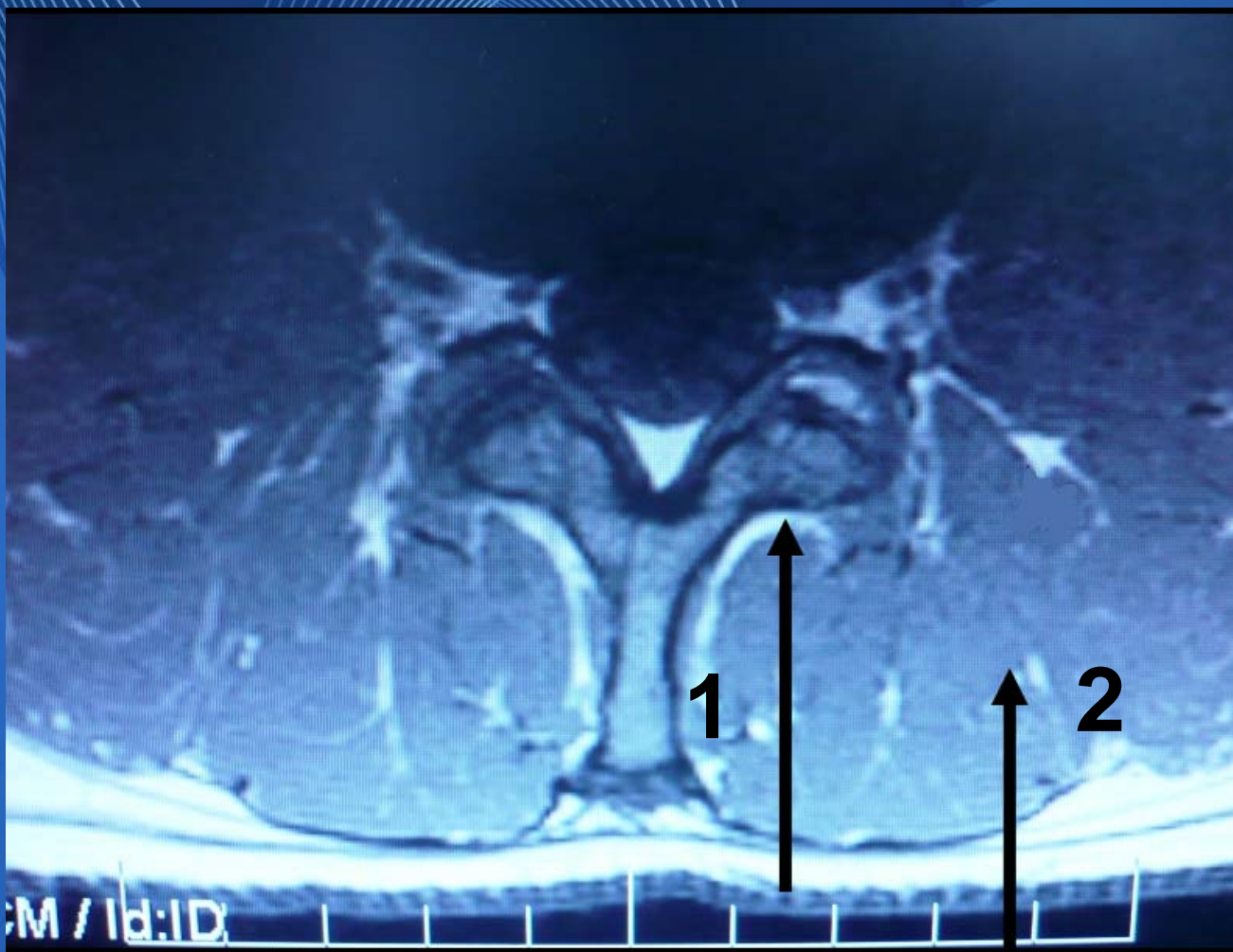
*Referencia de
Superficie – Palpación
Cresta Iliaca L3-L4*





Abordaje Paravertebral Profundo

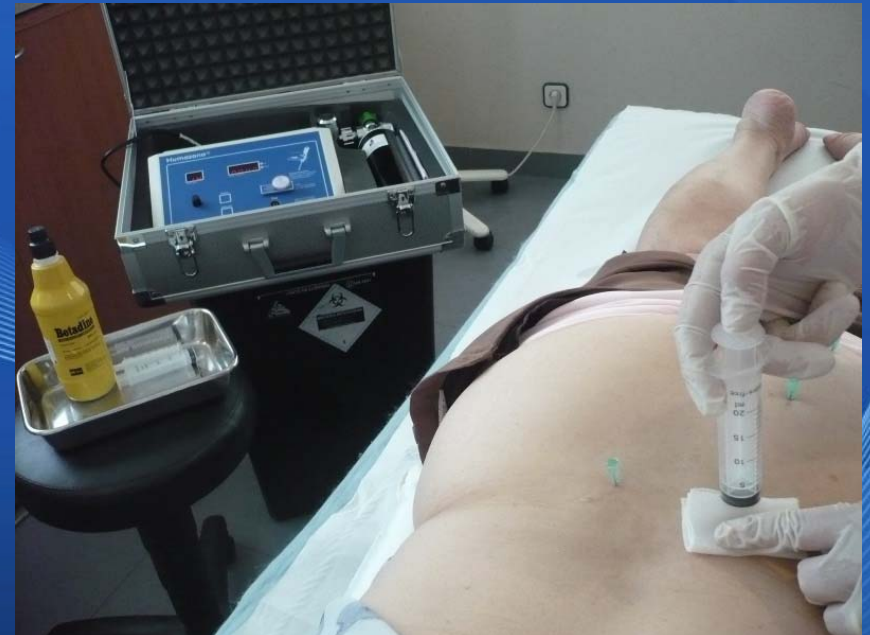
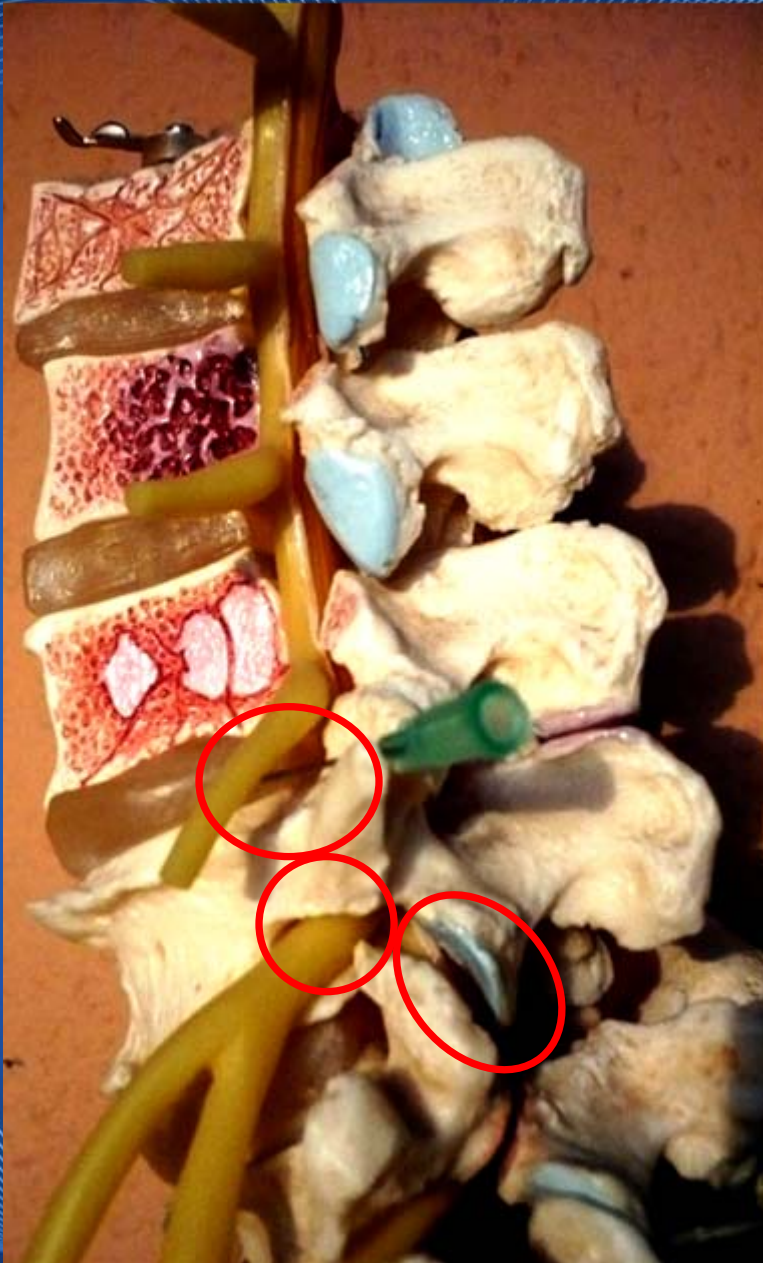


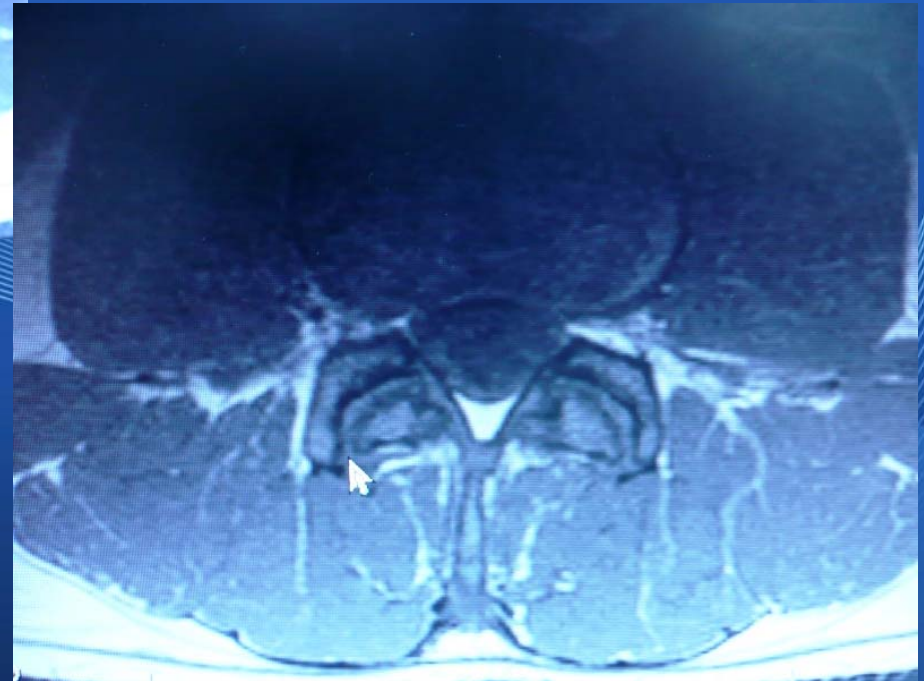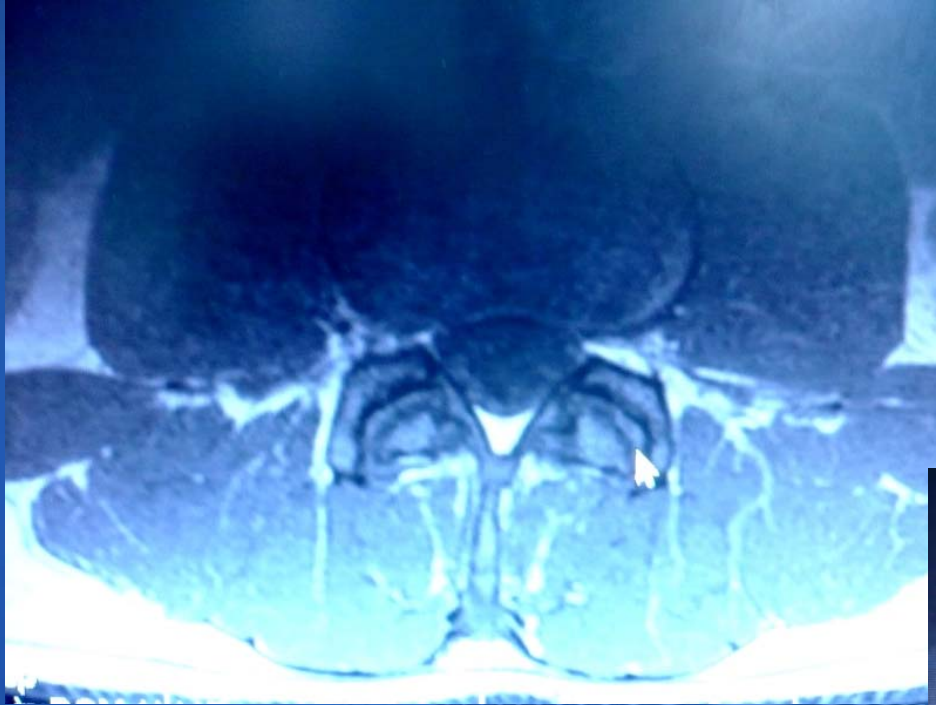1 *Infiltración
paravertebral
profunda*

2 *Infiltración
paravertebral
clásica*

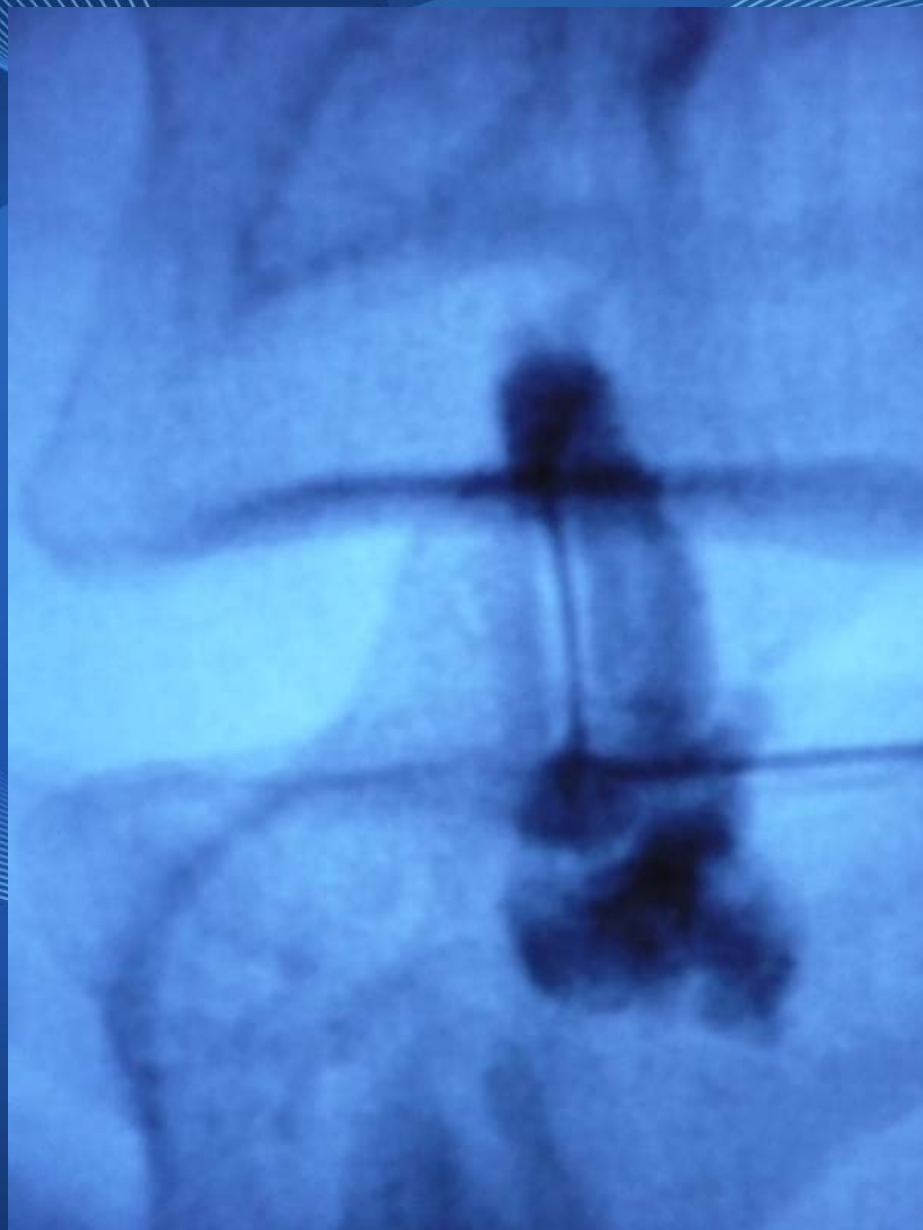
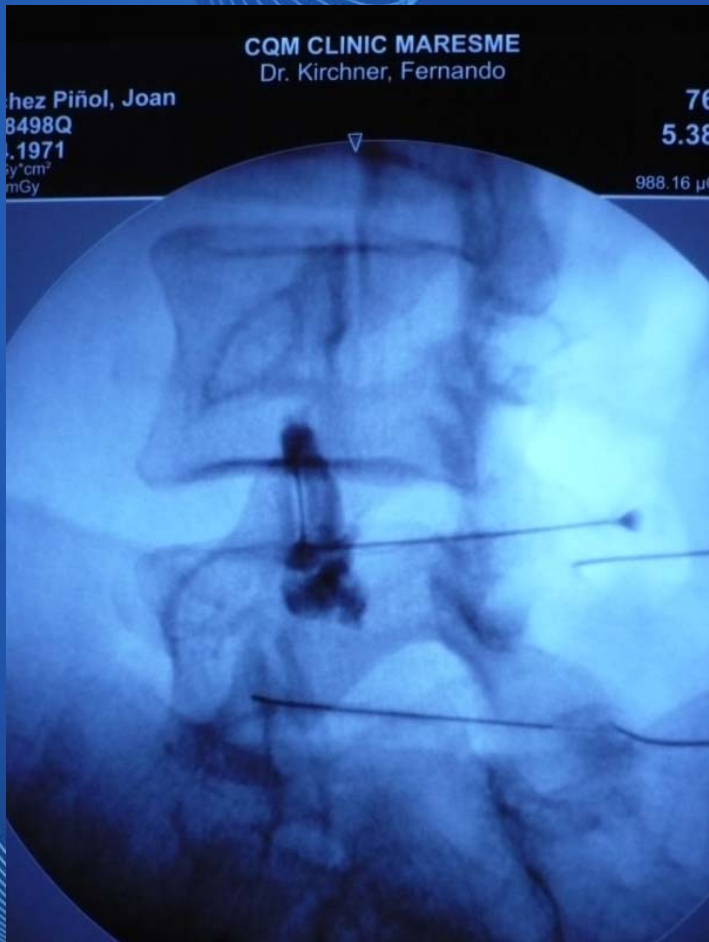
Aplicaciones de la Ozonoterapia en la Columna




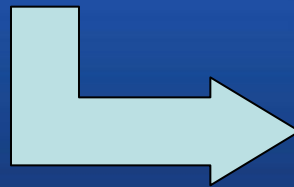
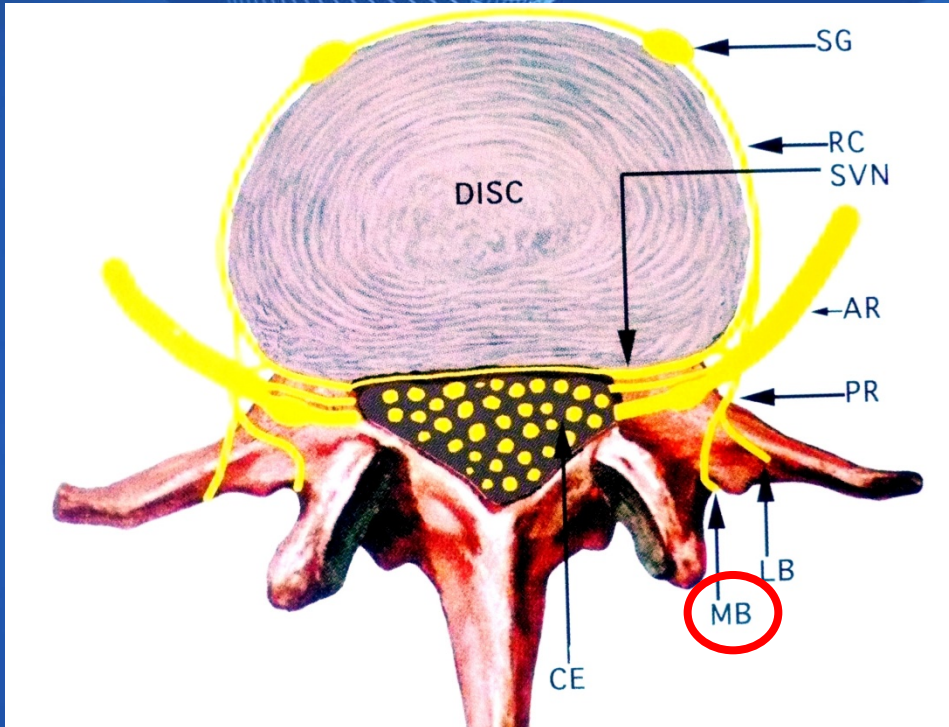
Articulación Interapofisaria



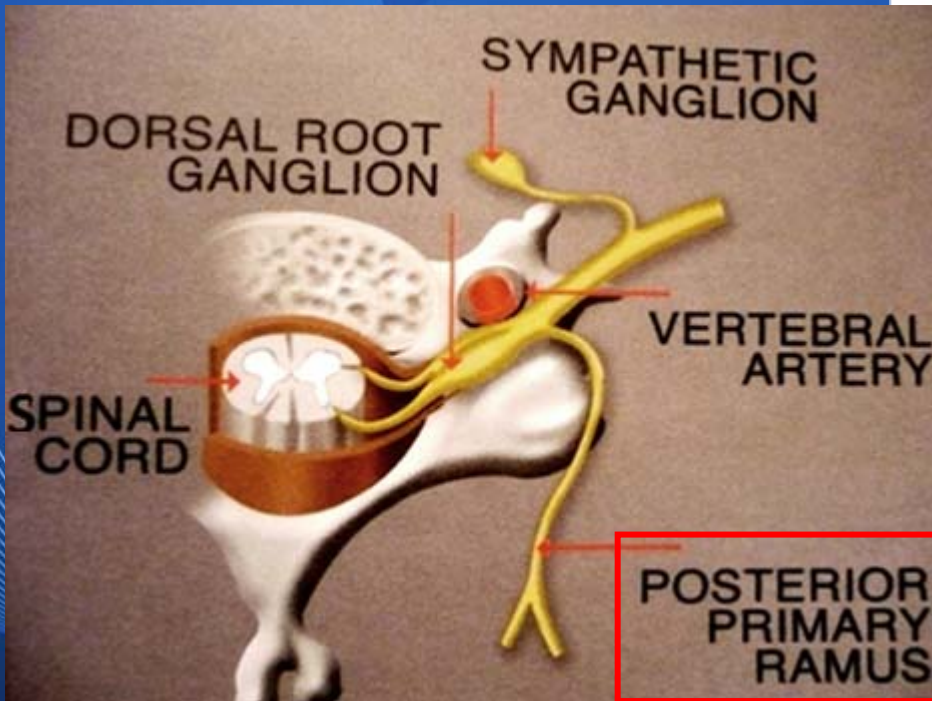
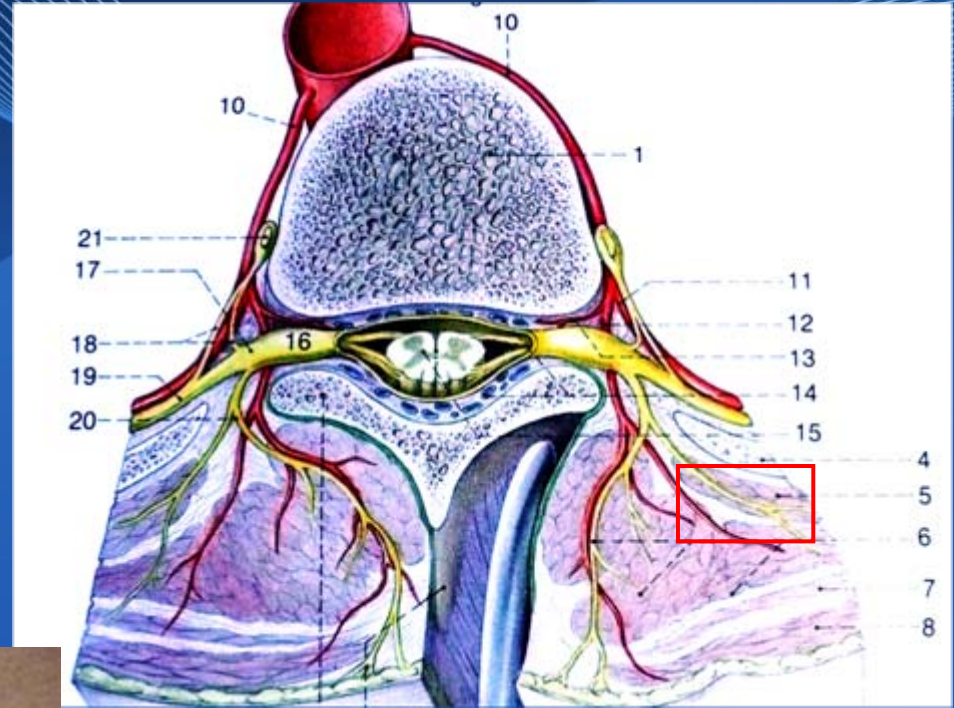
Infiltración Articular



Rama Medial del Ramo Posterior

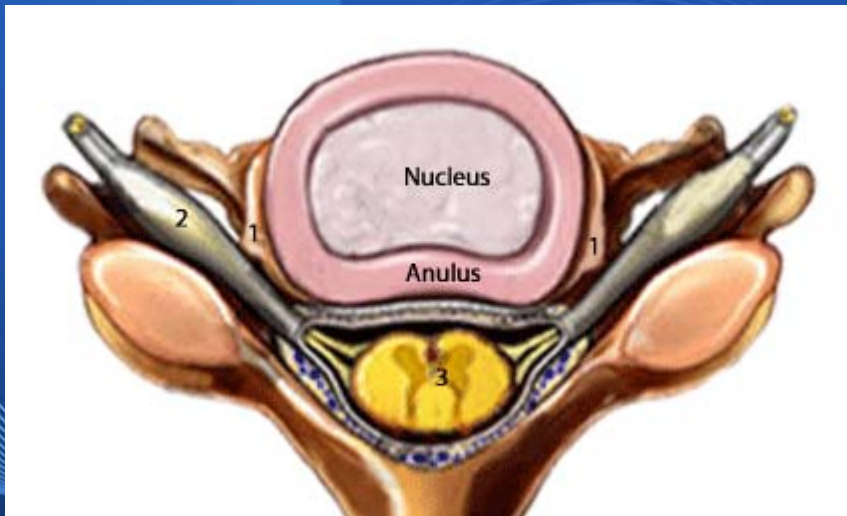
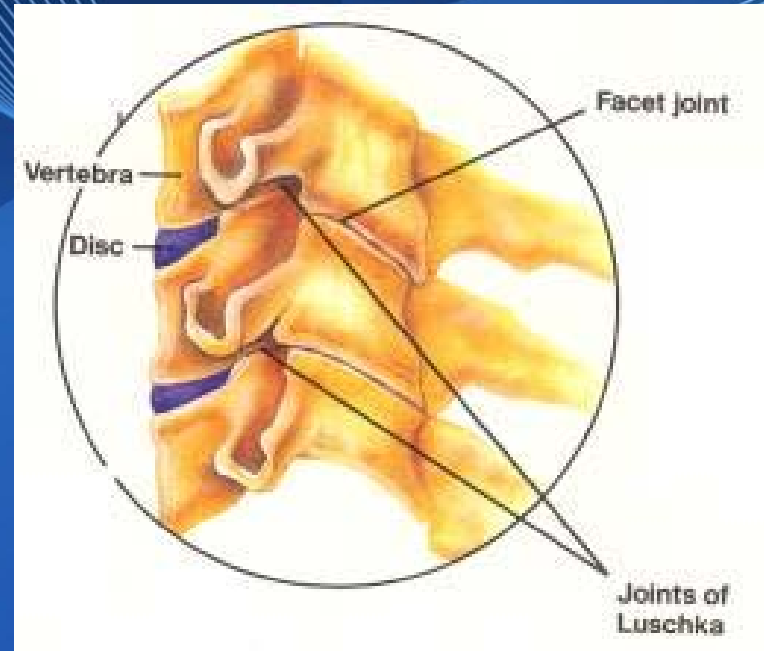


Rama medial del ramo posterior (o dorsal) de la raíz



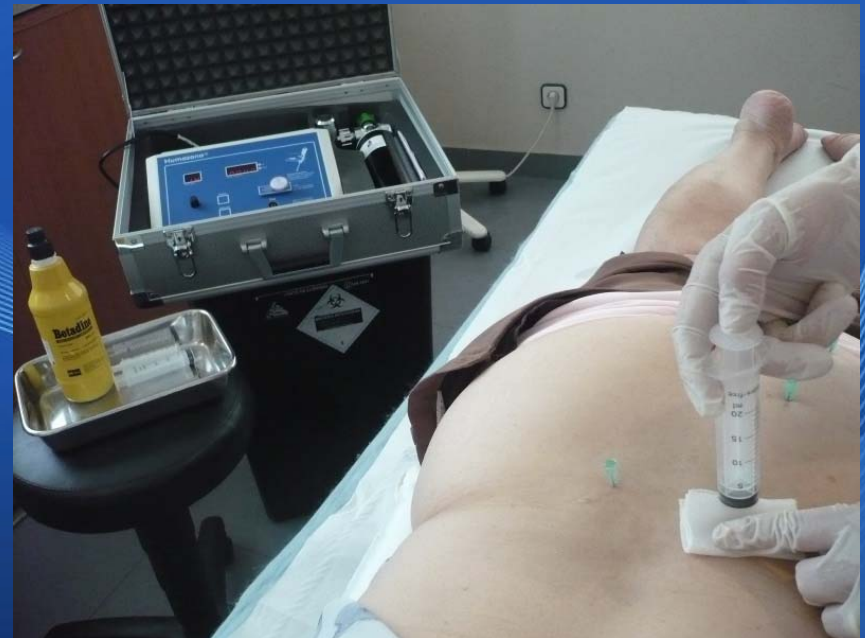Publicación de sus trabajos anatómicos sobre columna vertebral:

Anatomie des Menschen in Rücksicht auf das Bedürfnis der praktischen Heilkunde (1862-1869).

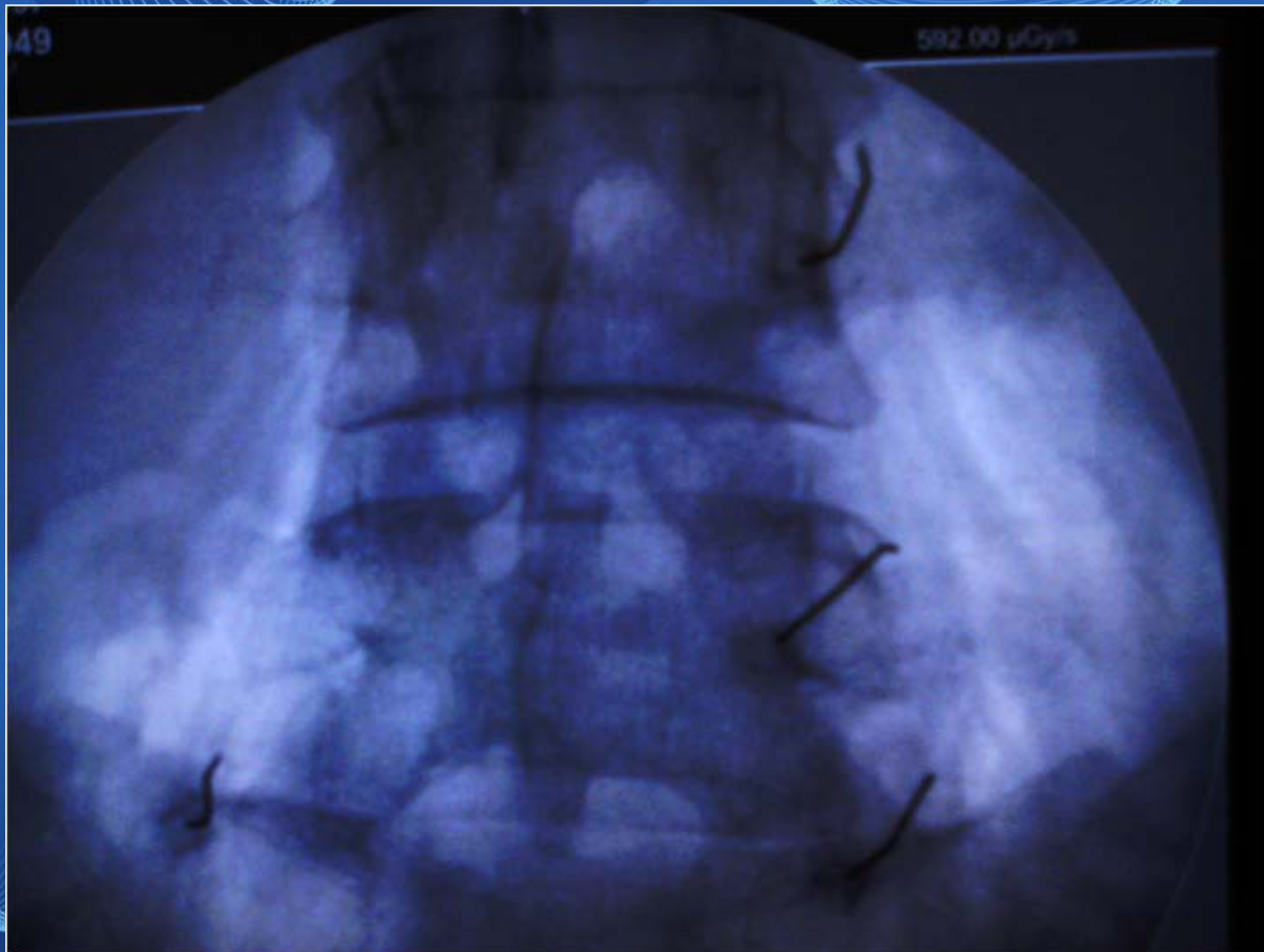


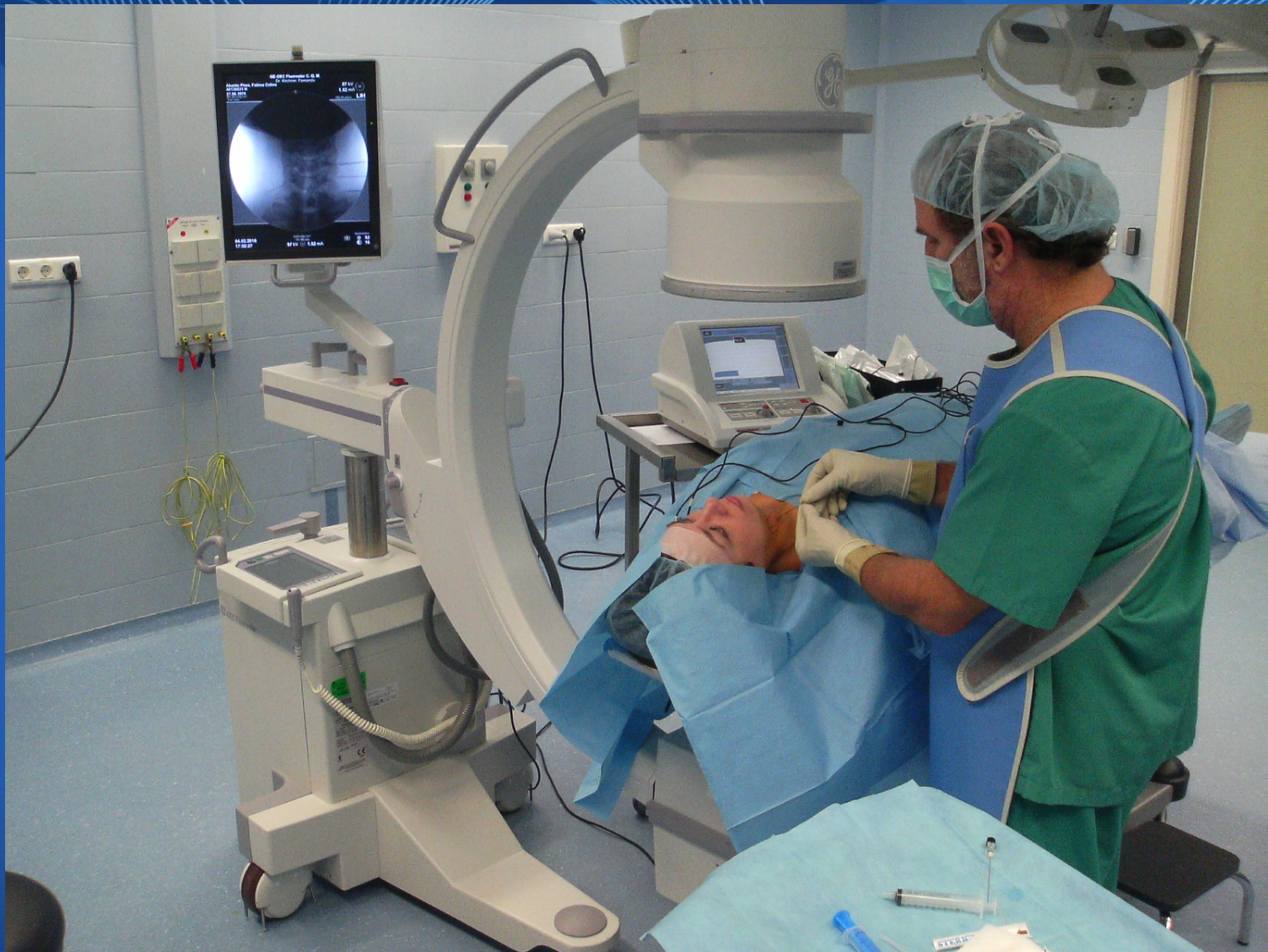1. *Crestas de Luschka*
2. *Nervio espinal*
3. *Médula espinal*

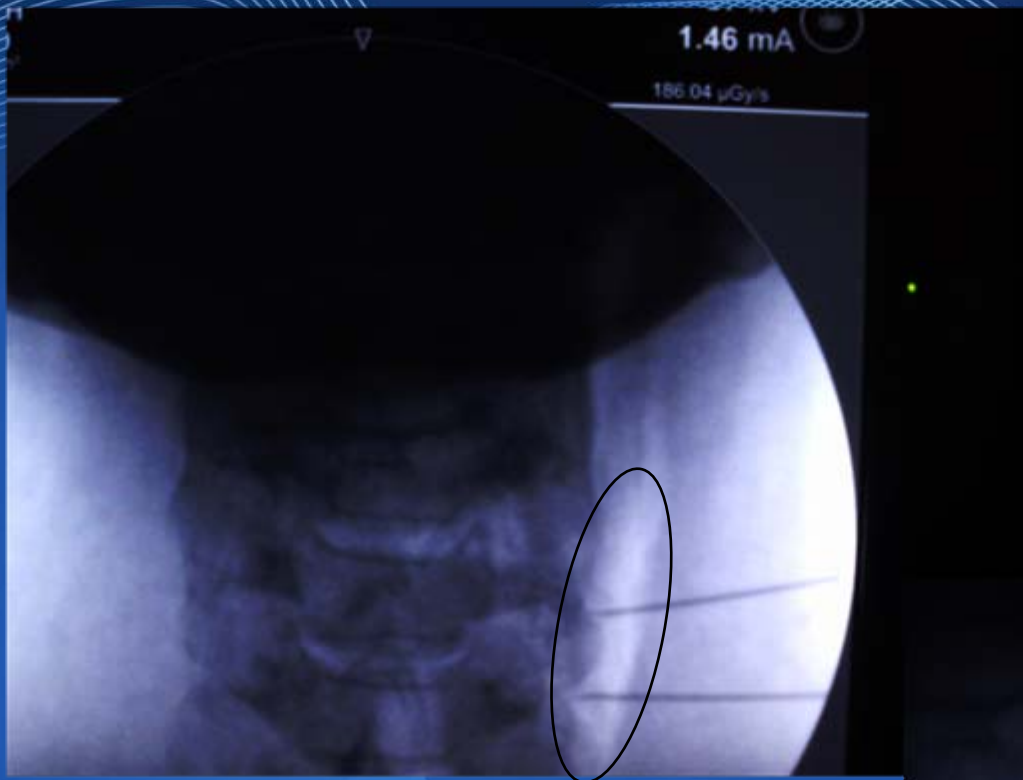
Aplicaciones de la Ozonoterapia en diferentes estructuras



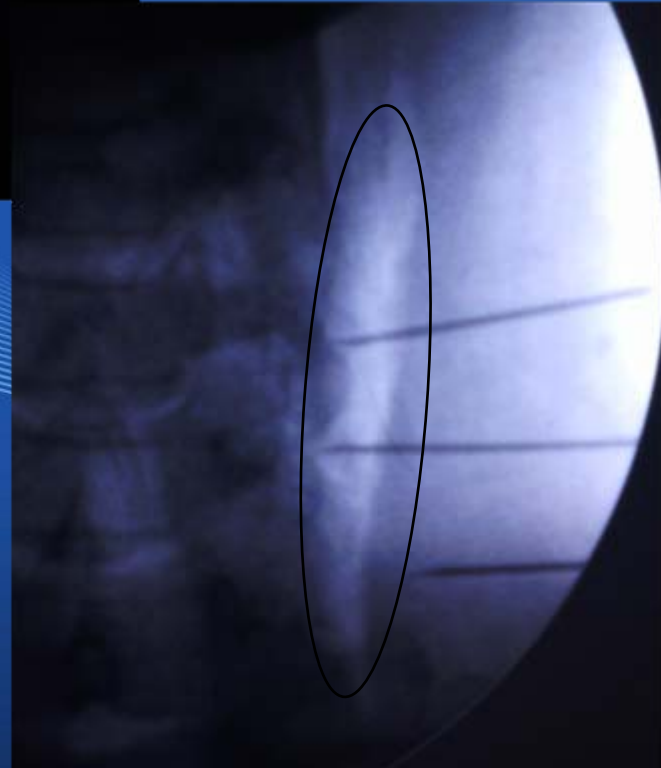
Inyección Paravertebral Profunda





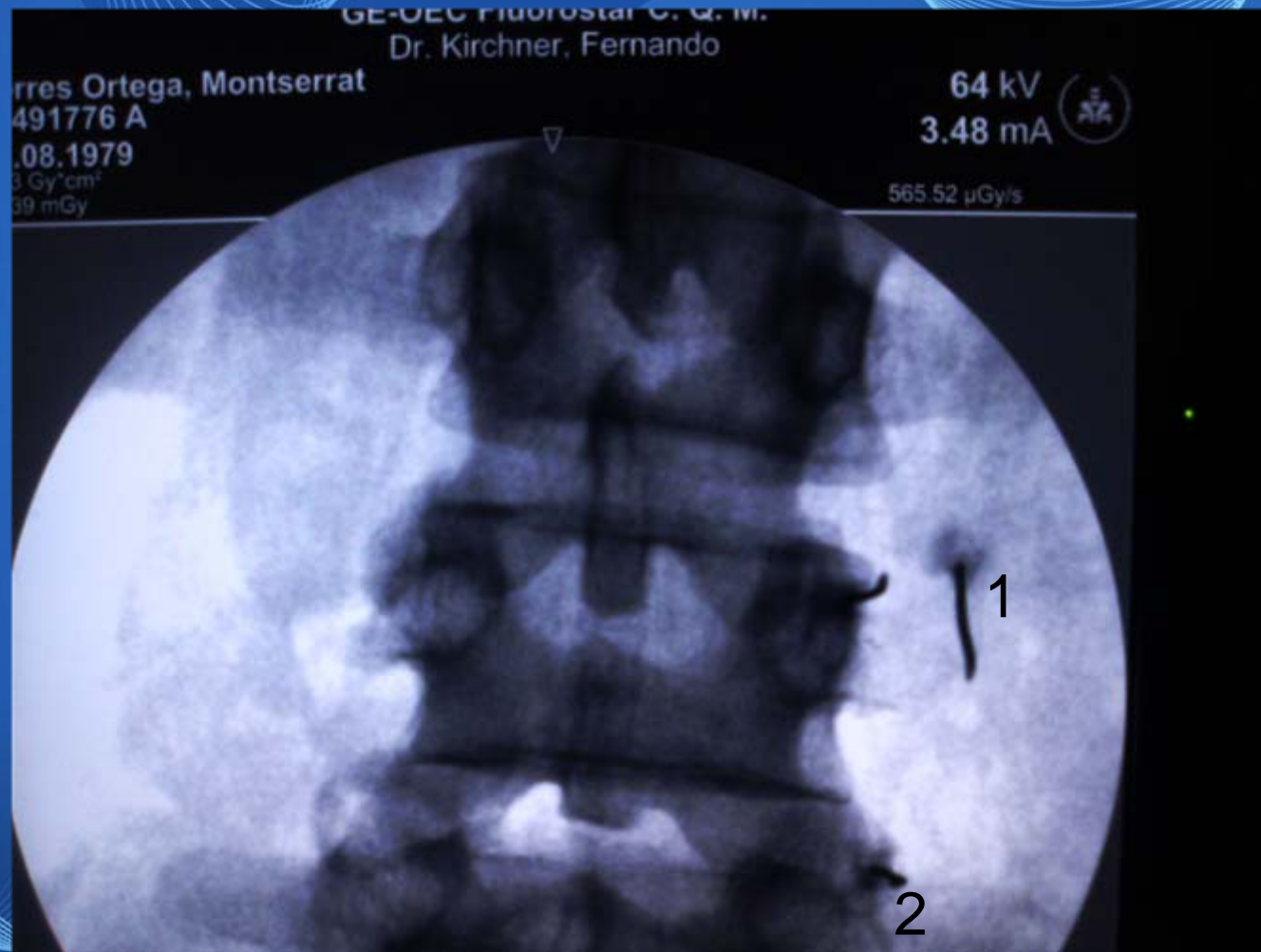

Infiltración Profunda en Columna Cervical



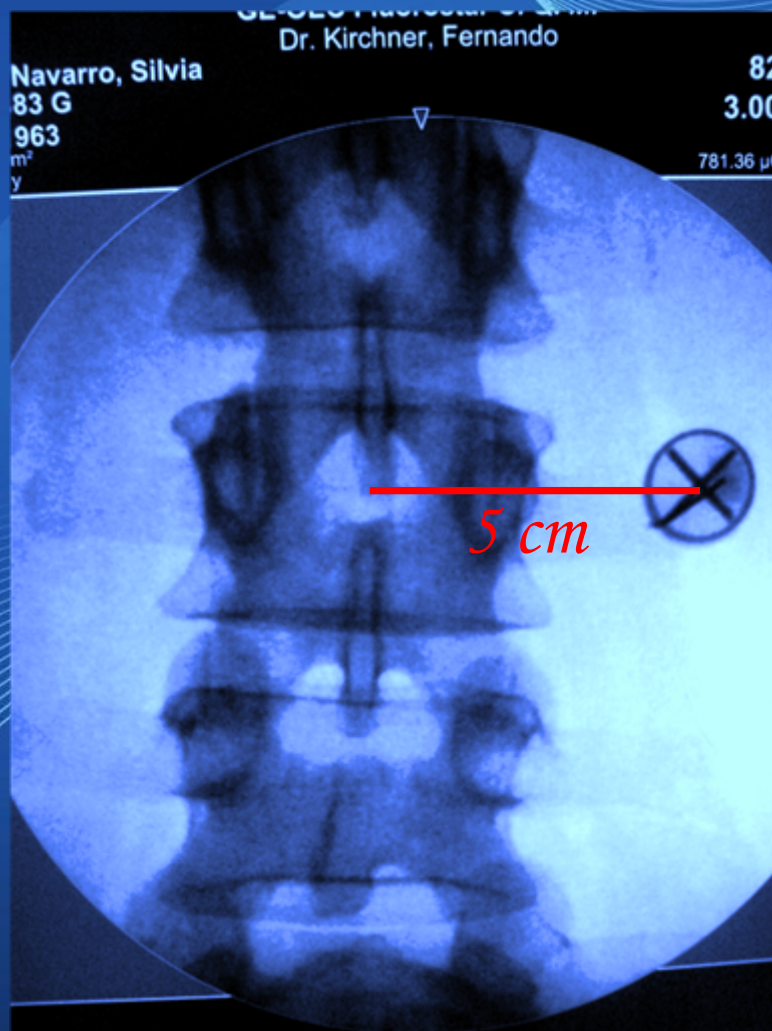
1- *Paravertebral Clásica*

2- *Paravertebral Profunda*

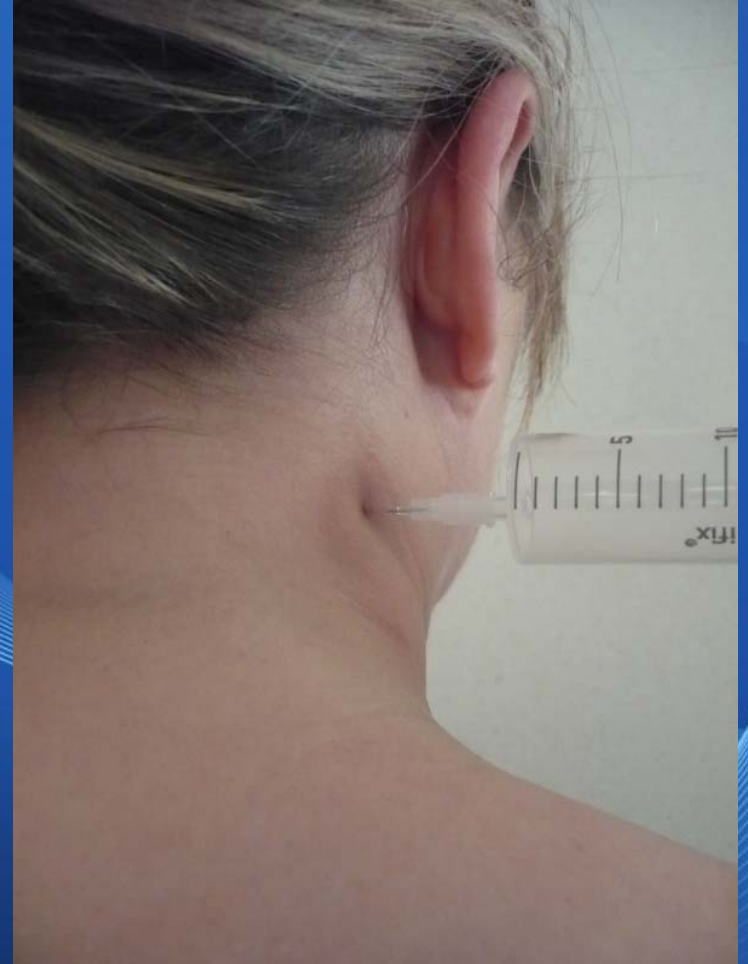
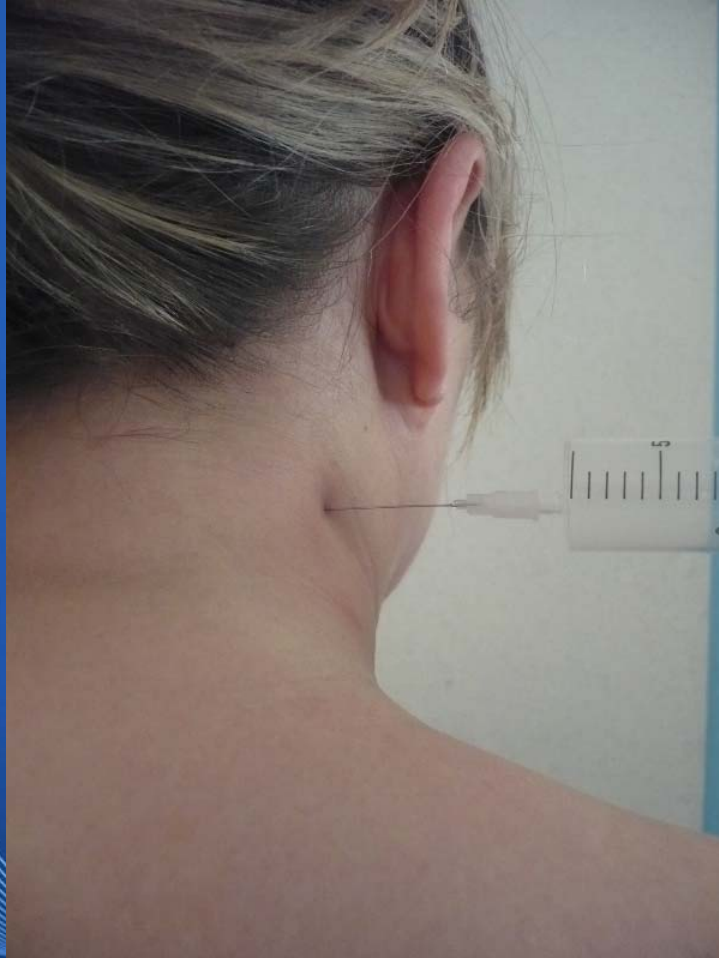
Inyección Paravertebral Clásica

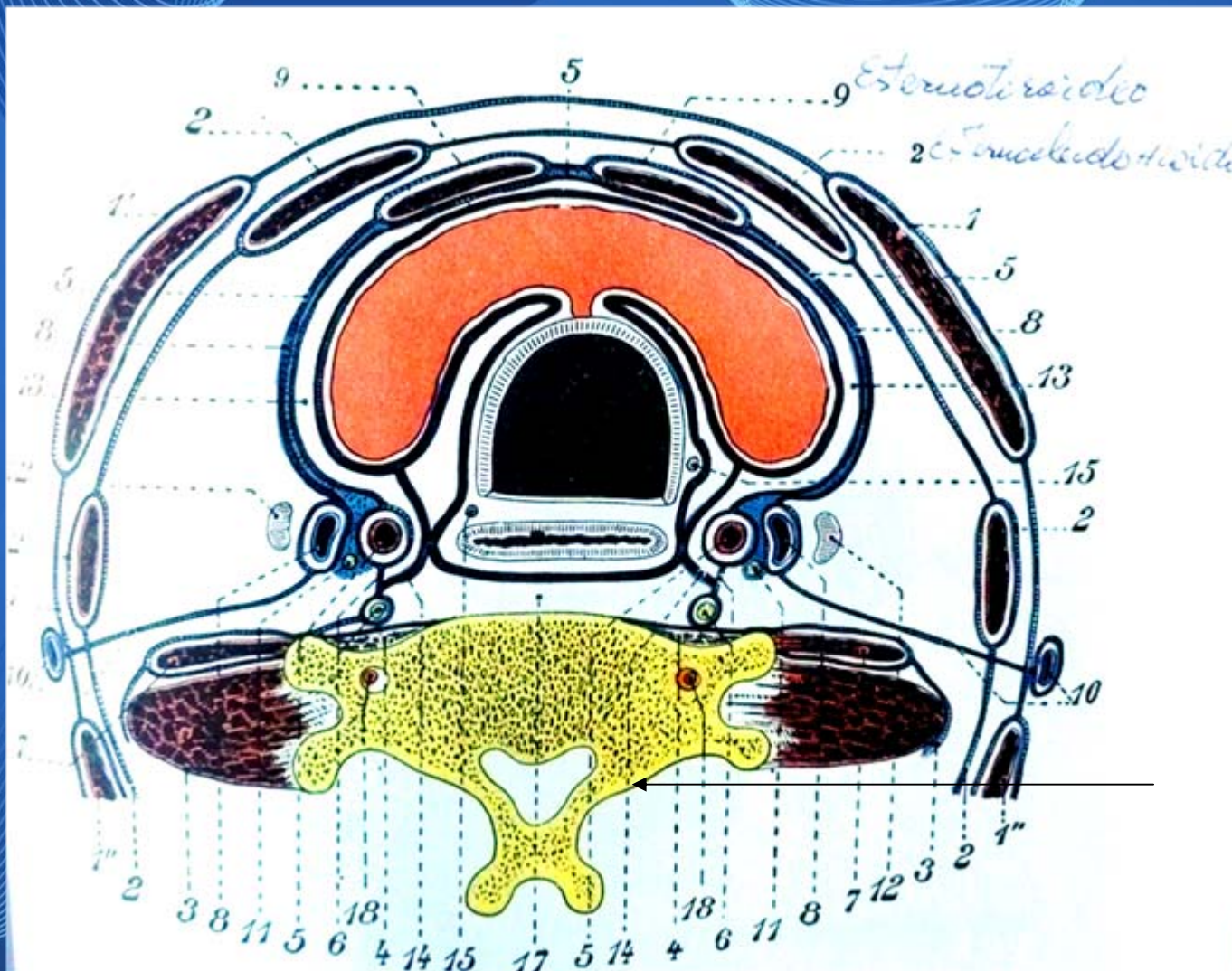
Constatación Radiológica



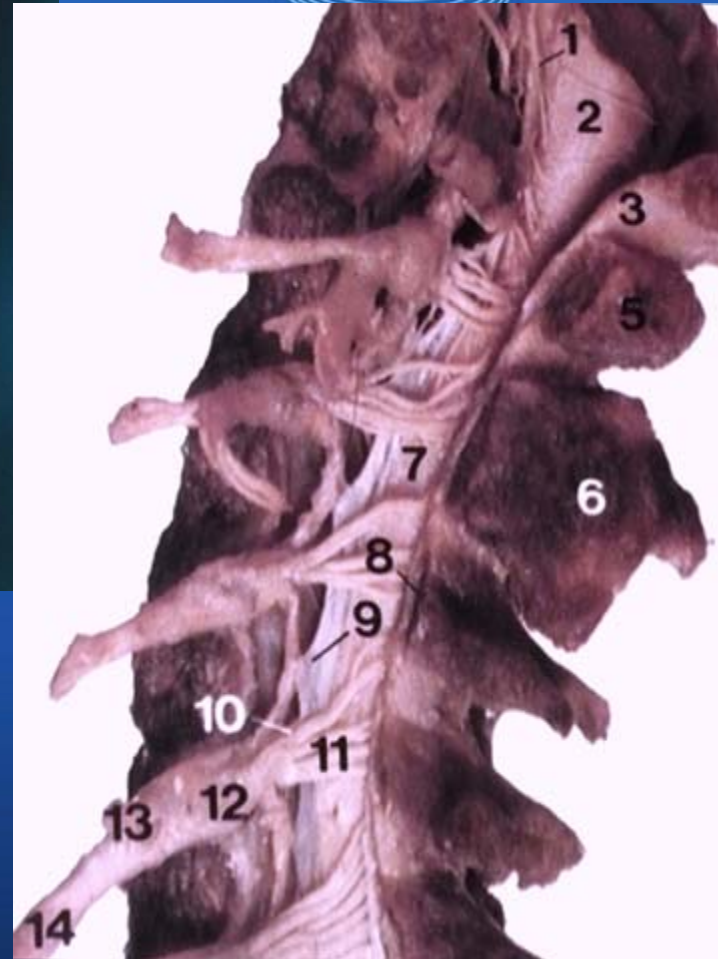
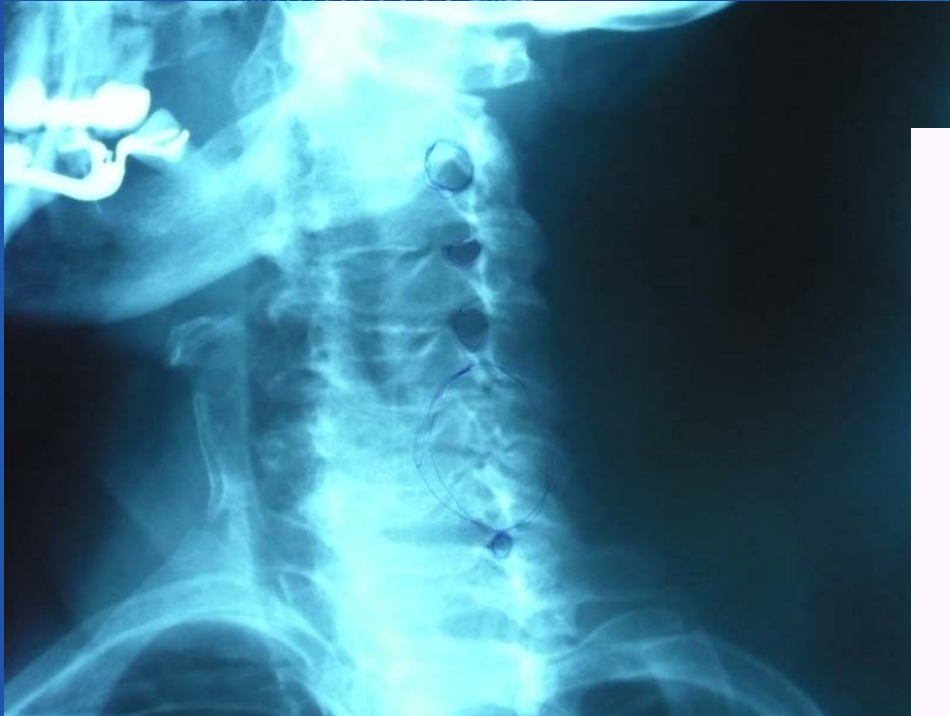Inyección Paravertebral Lateral Profunda Cervical

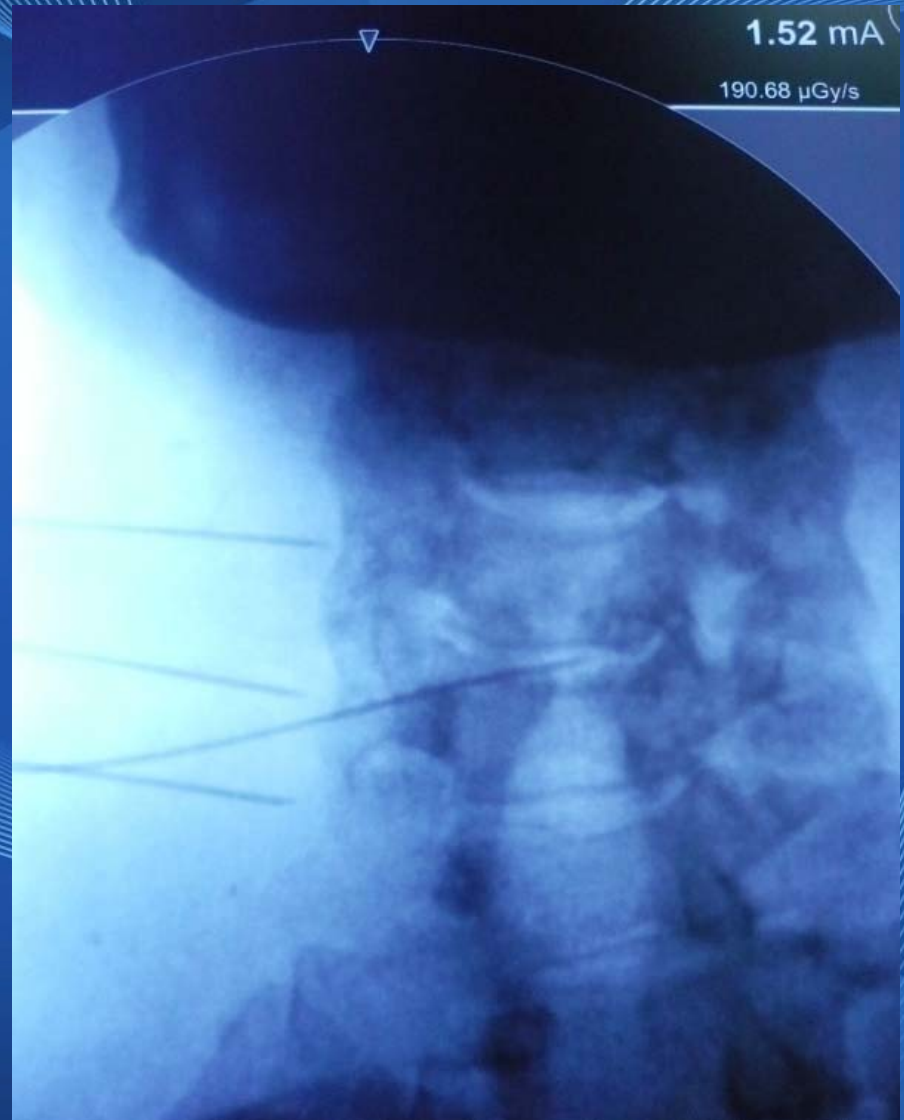
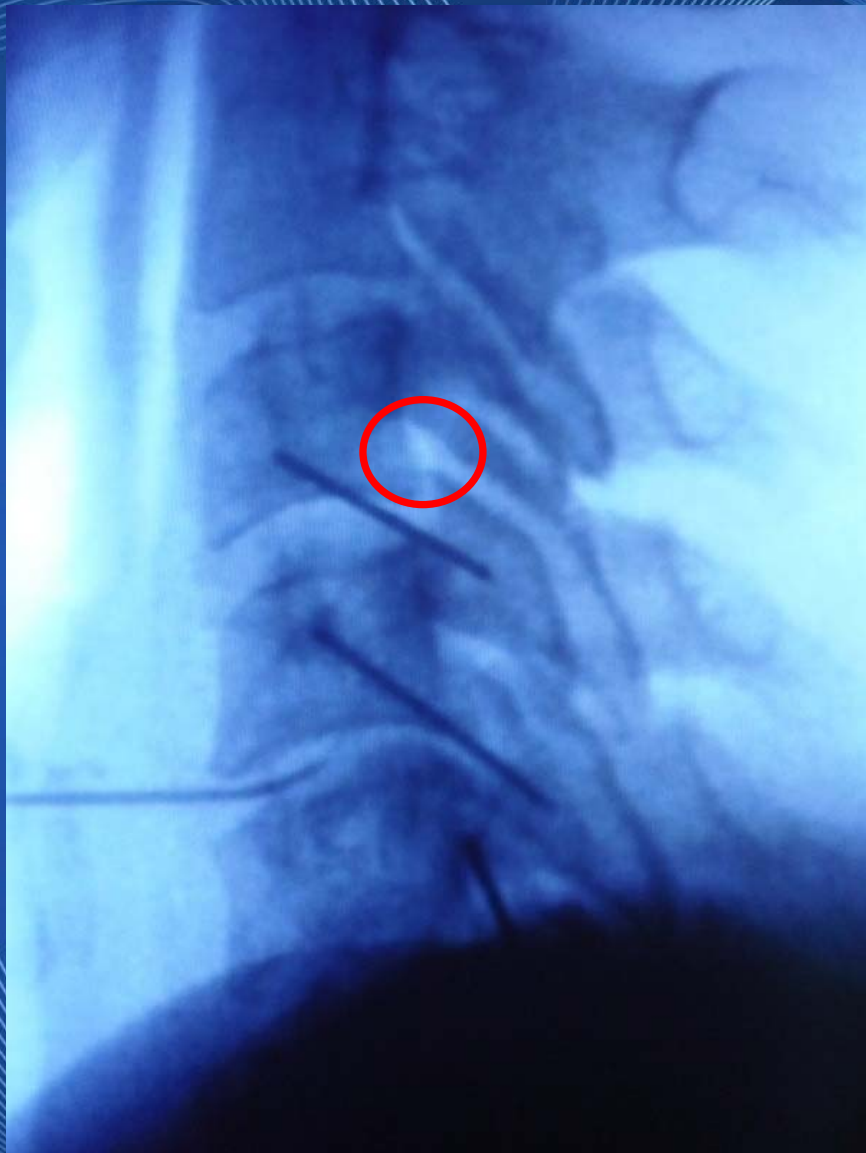

Inyección Paravertebral Lateral Profunda Cervical

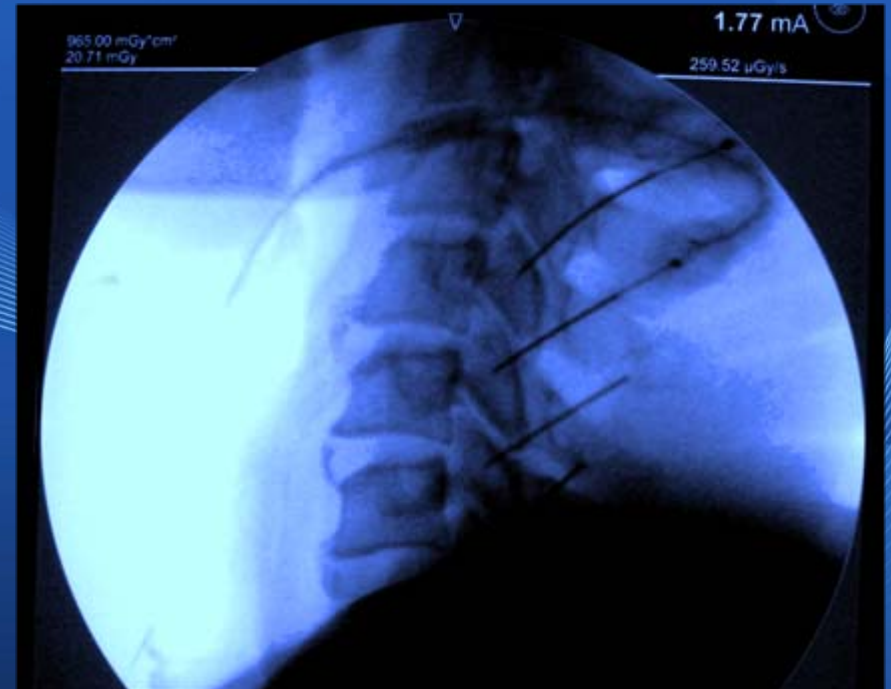
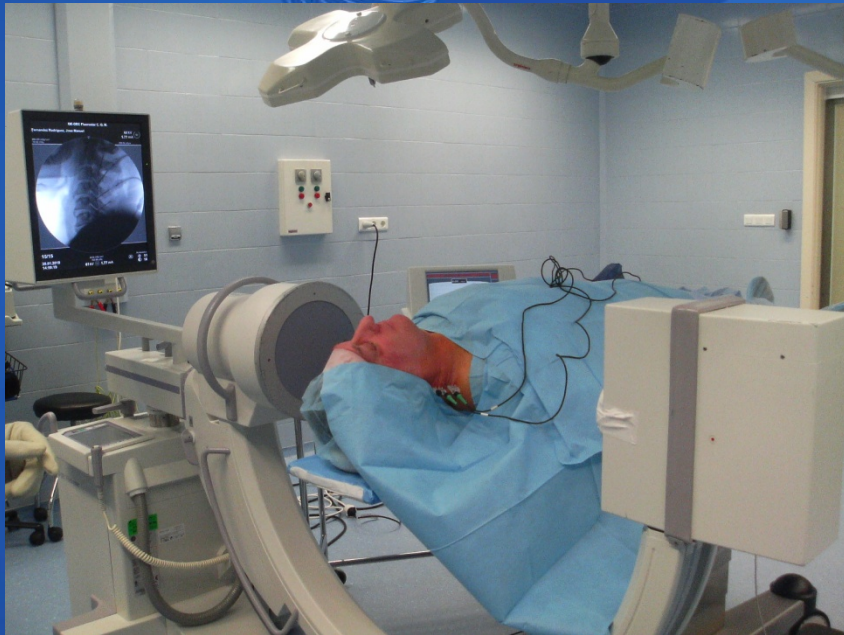
Agujeros de Conjunción para emergencia Raíces

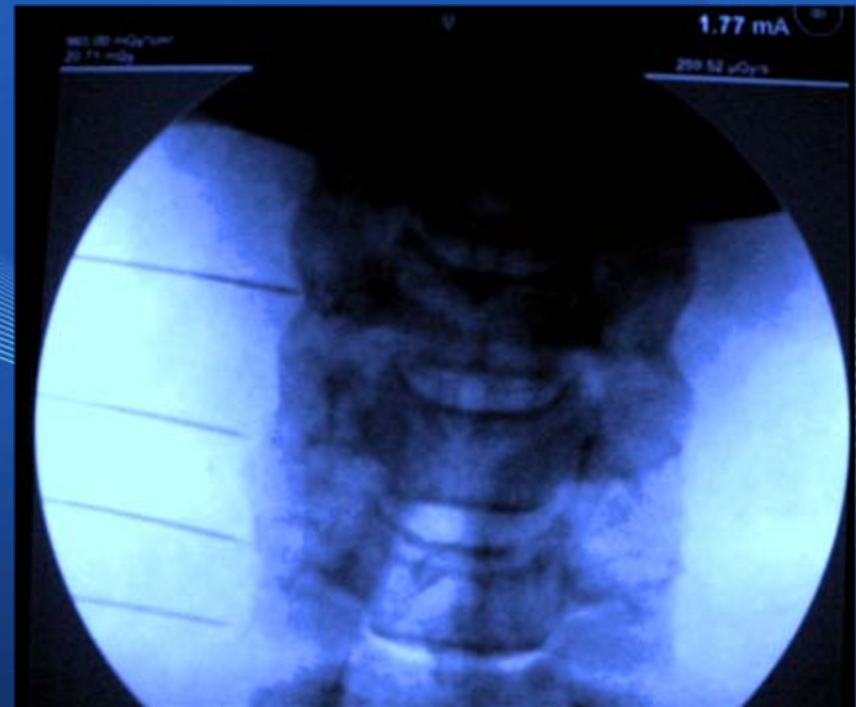
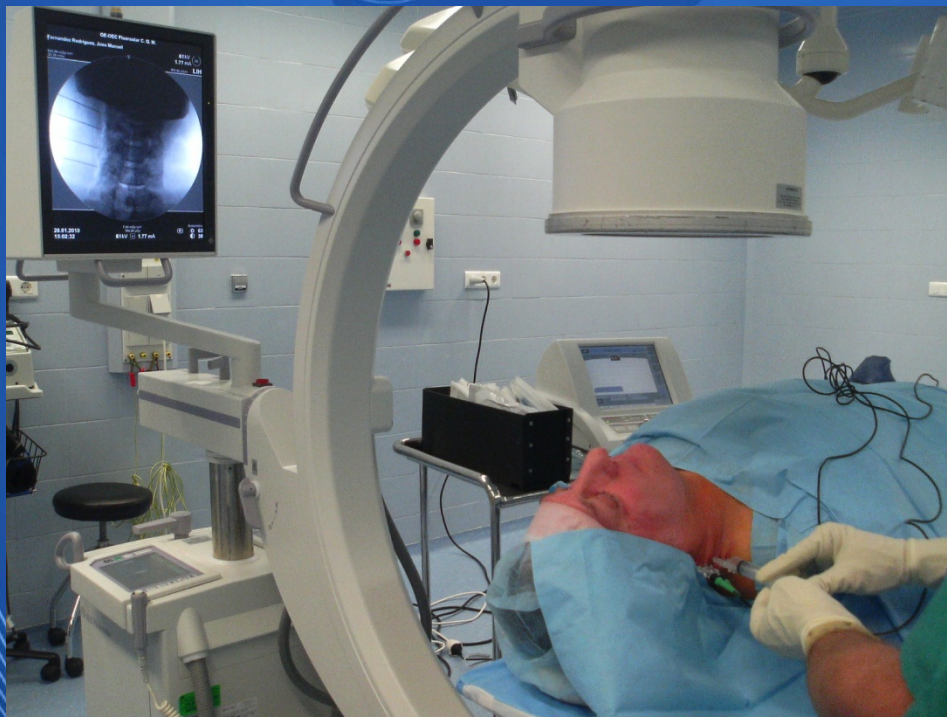


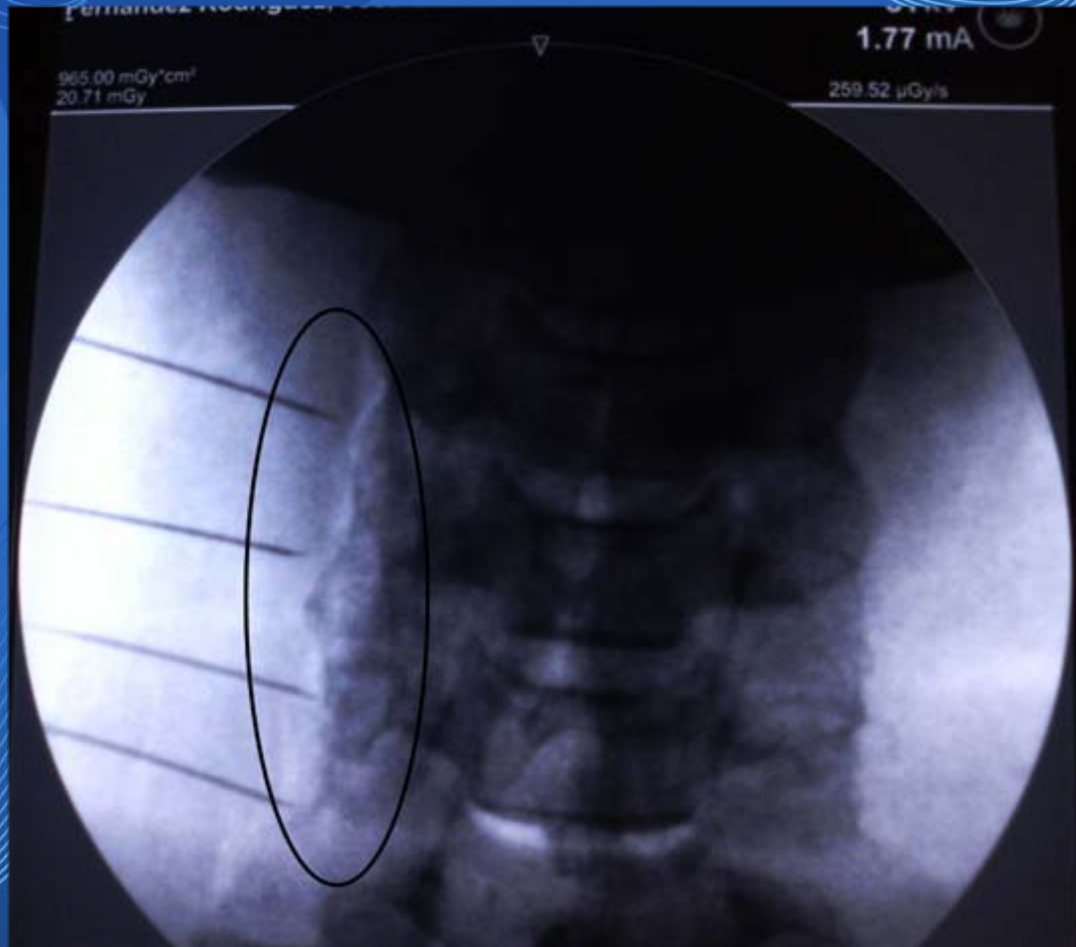
Vista de Perfil para Inyección Lateral Profunda Cervical



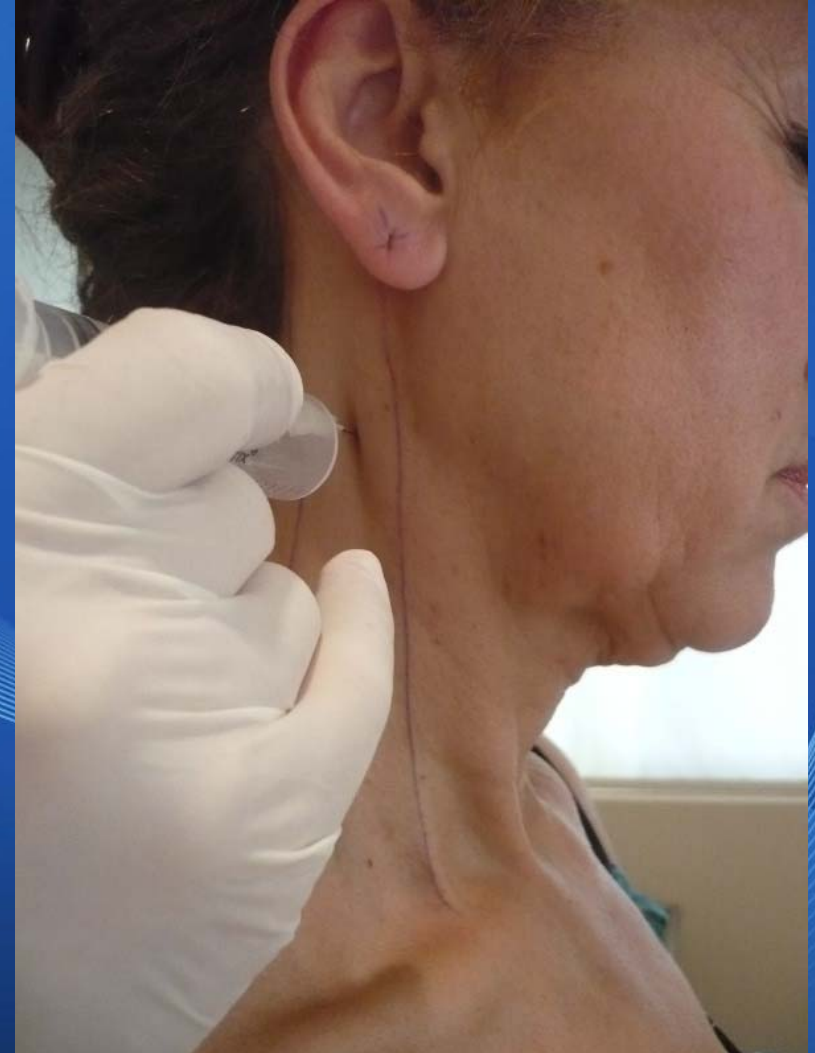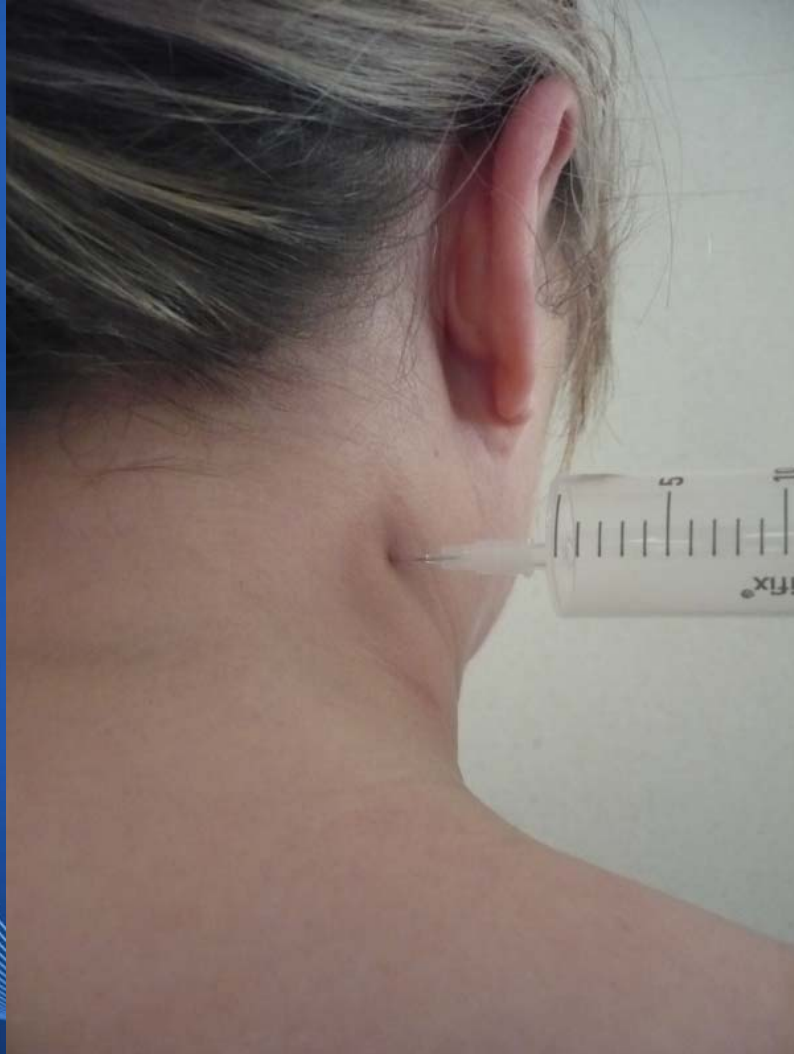Vista Antero-posterior Radiológica para Inyección Lateral Profunda Cervical

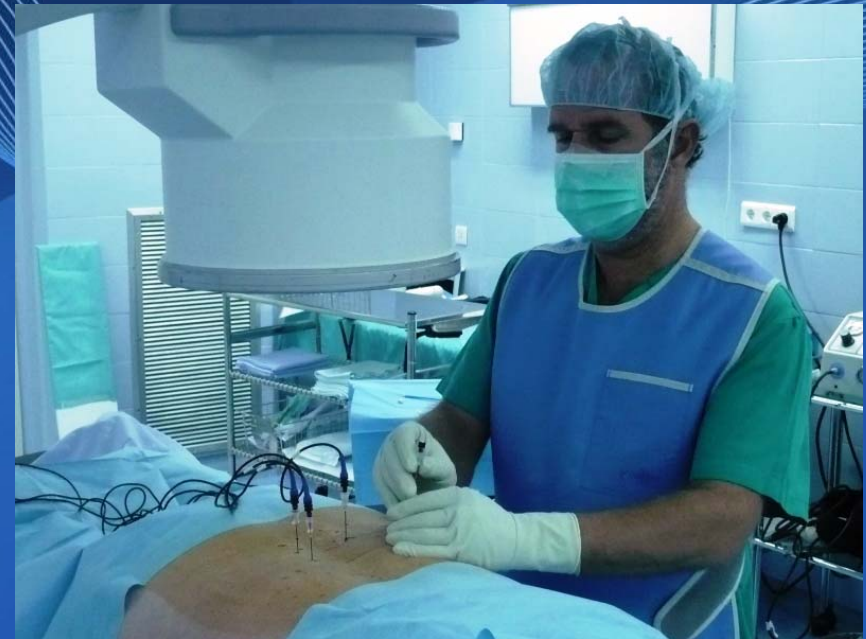
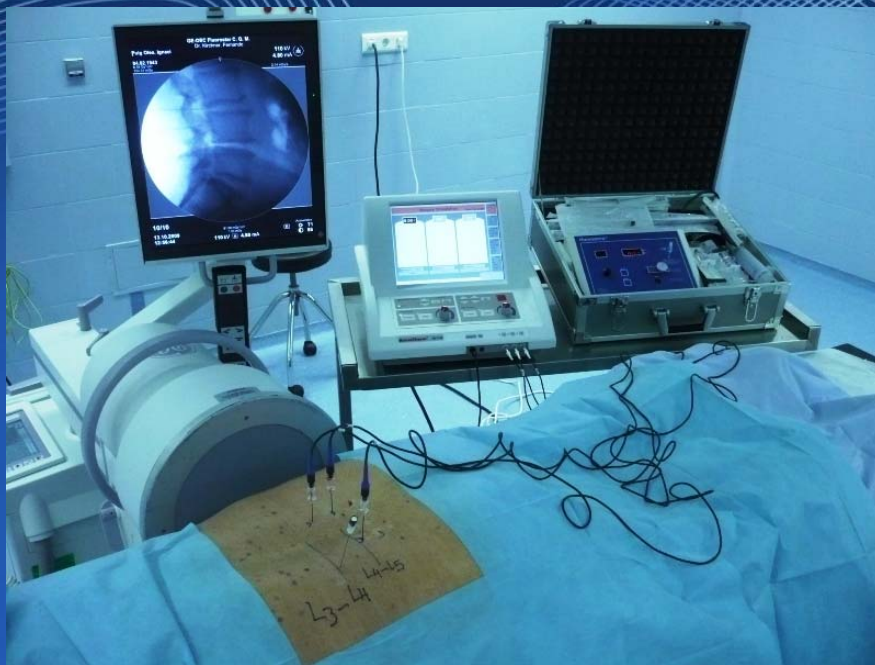
Vista Antero-posterior Radiológica para Inyección Lateral Profunda Cervical

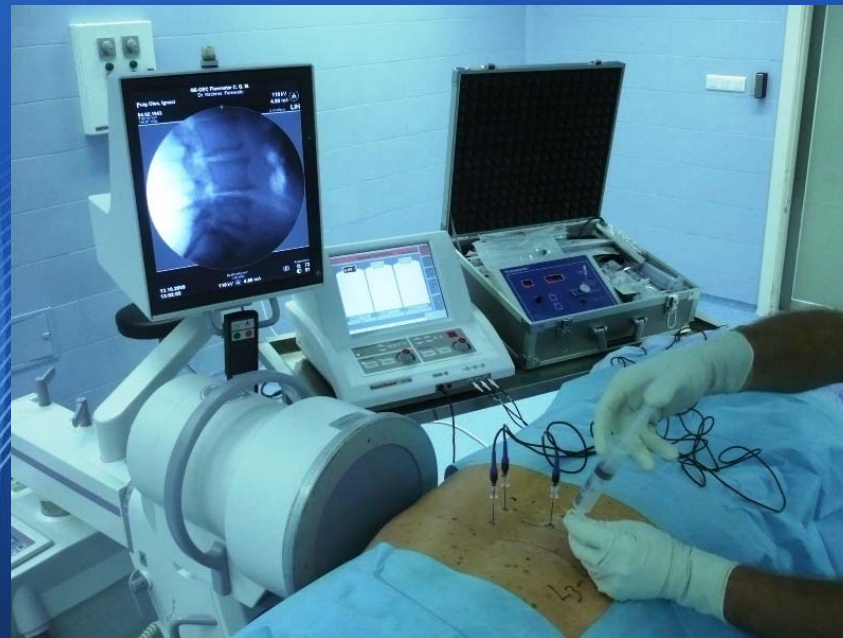

Inyección Lateral Profunda Paravertebral en Consulta

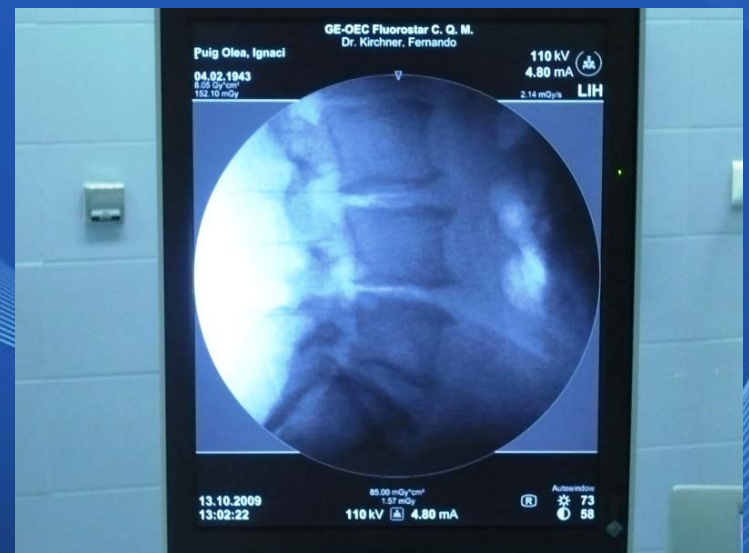
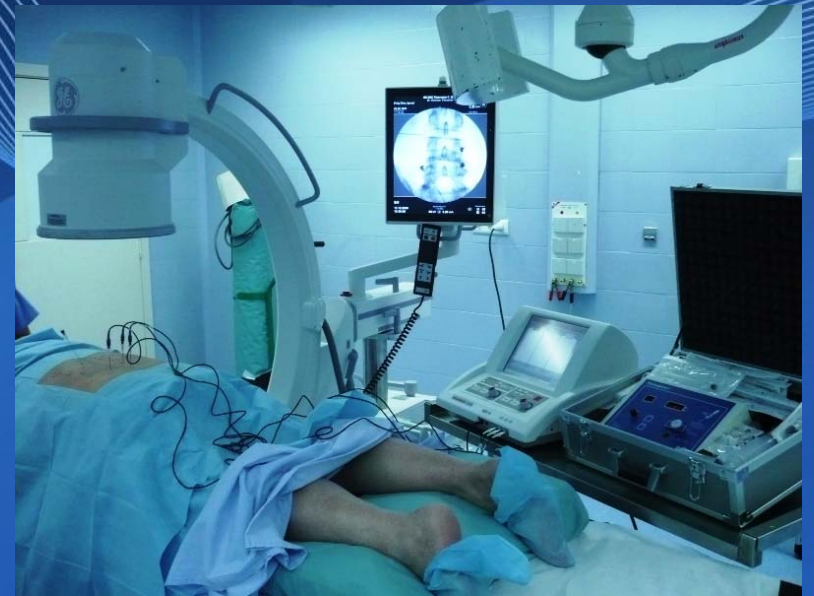
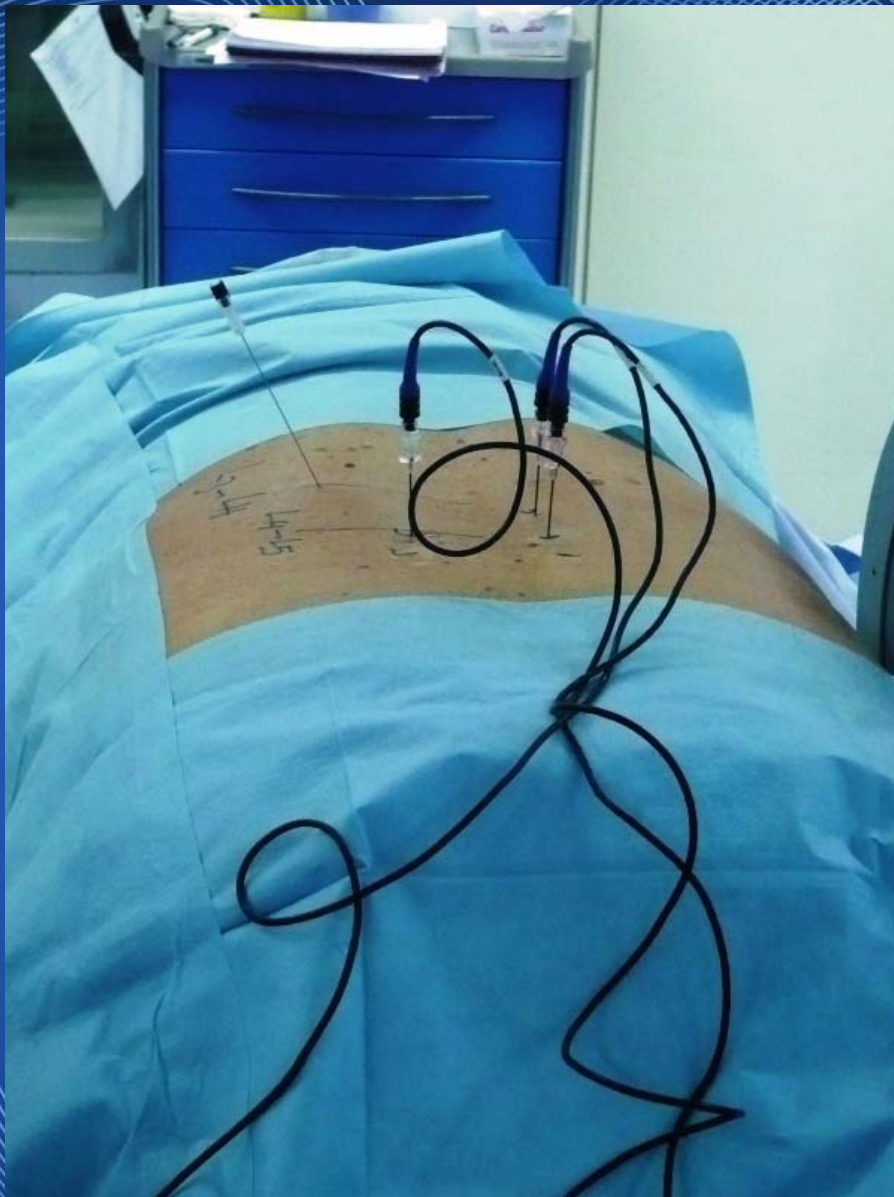

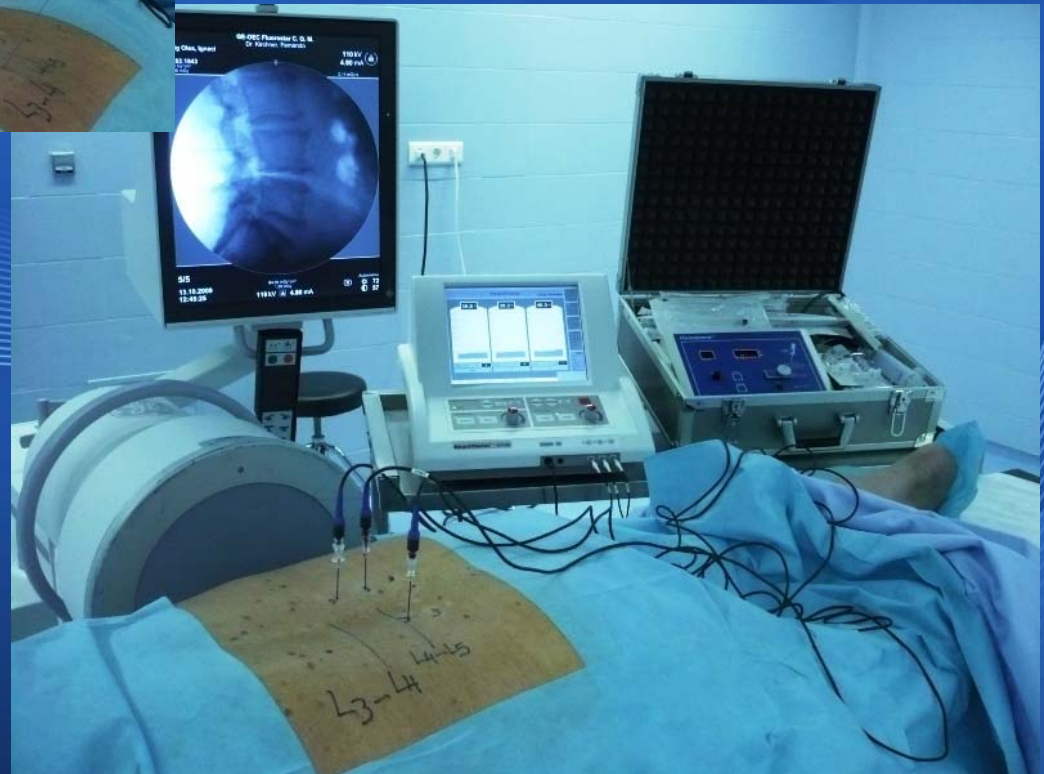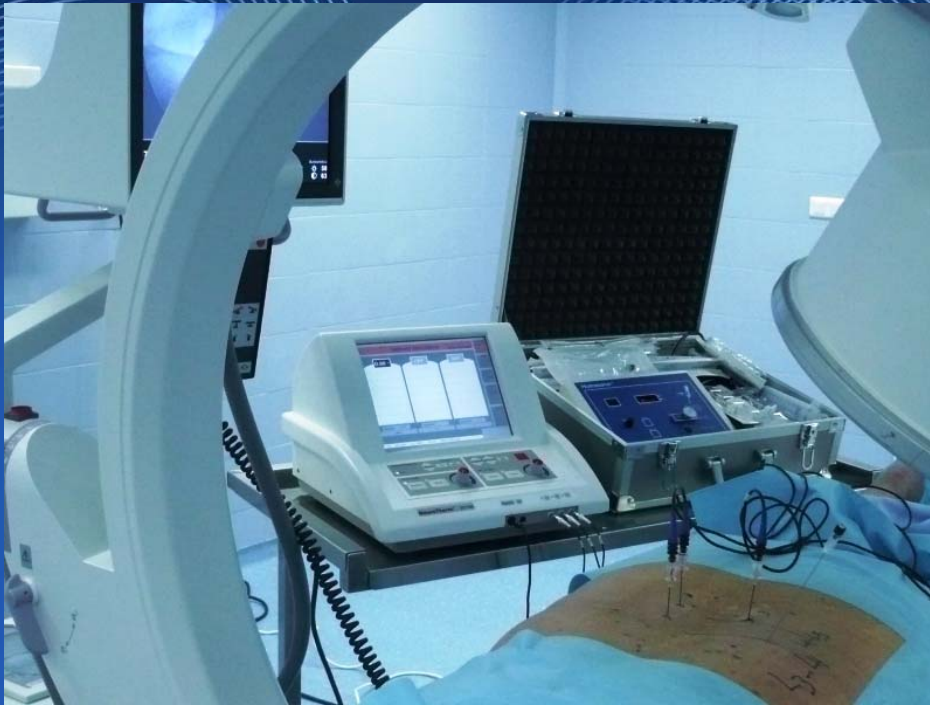Asepsia
-
Orden

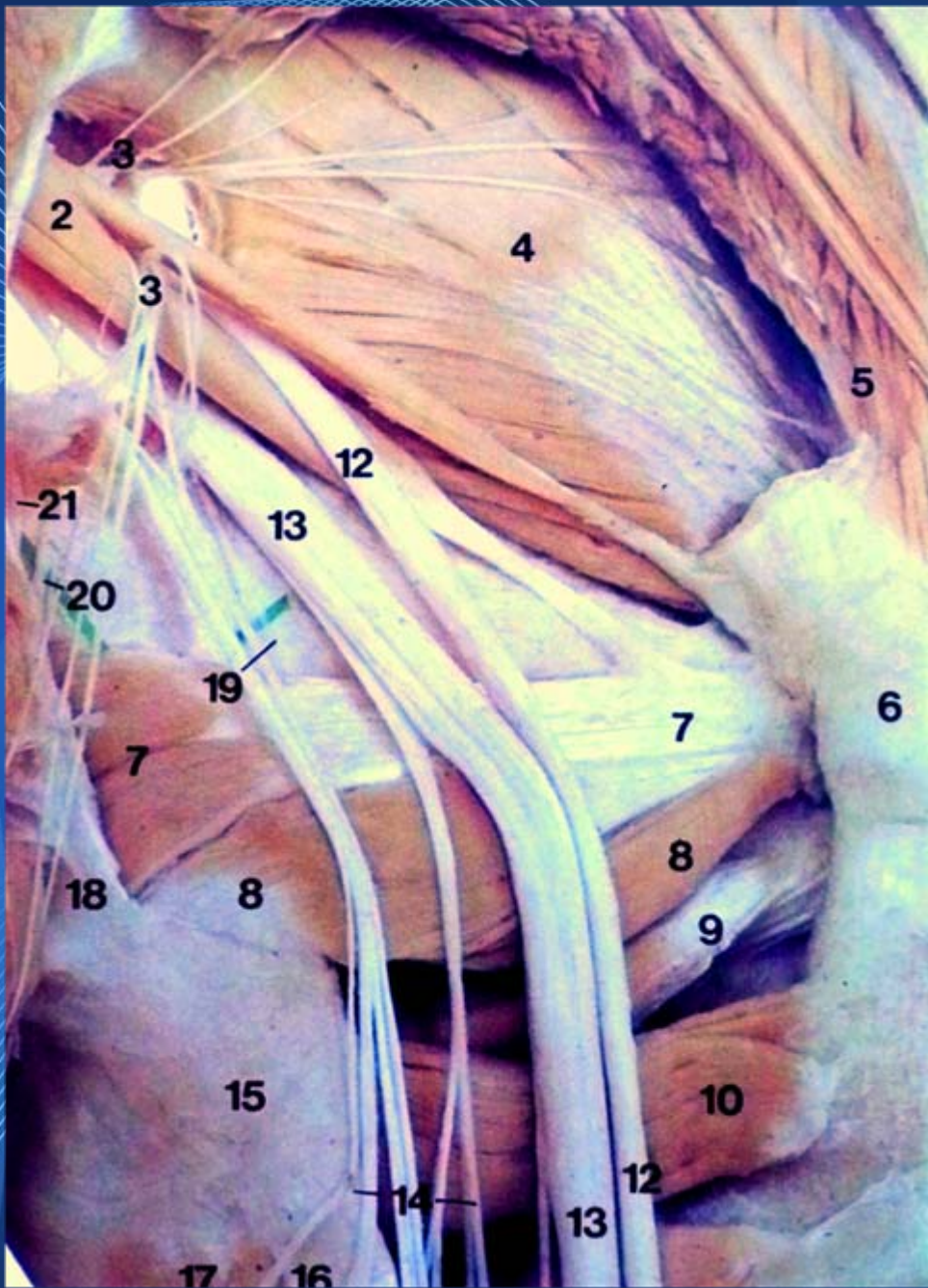


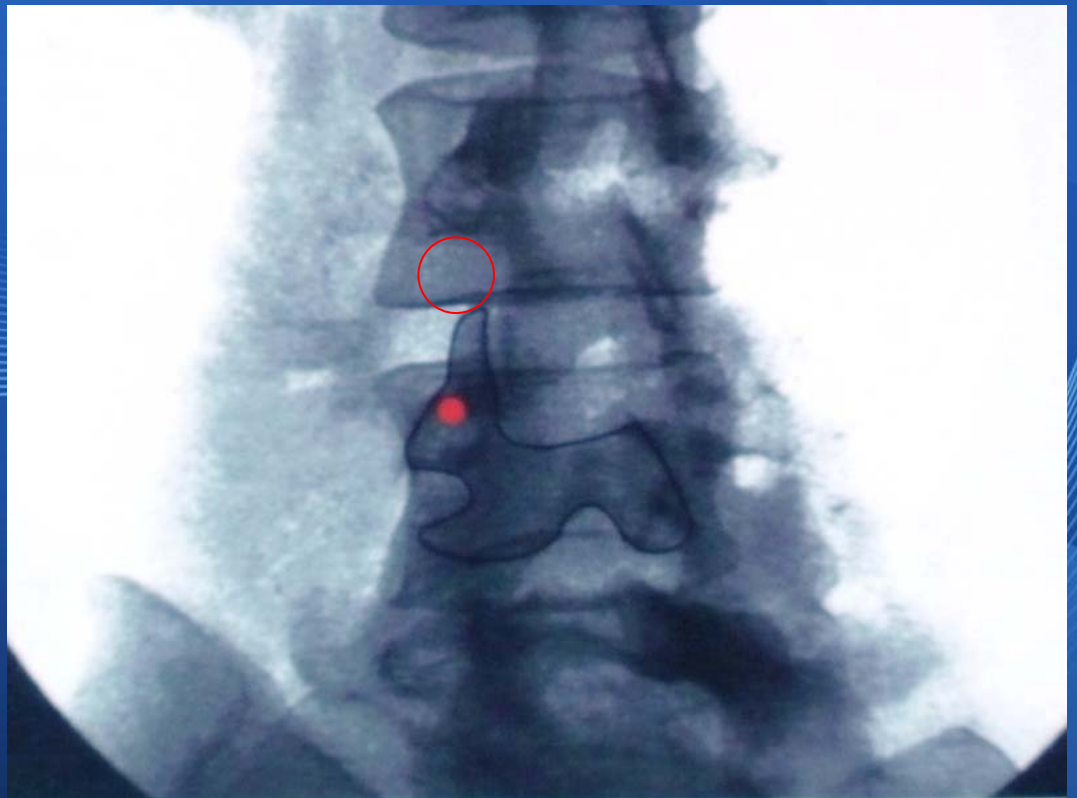
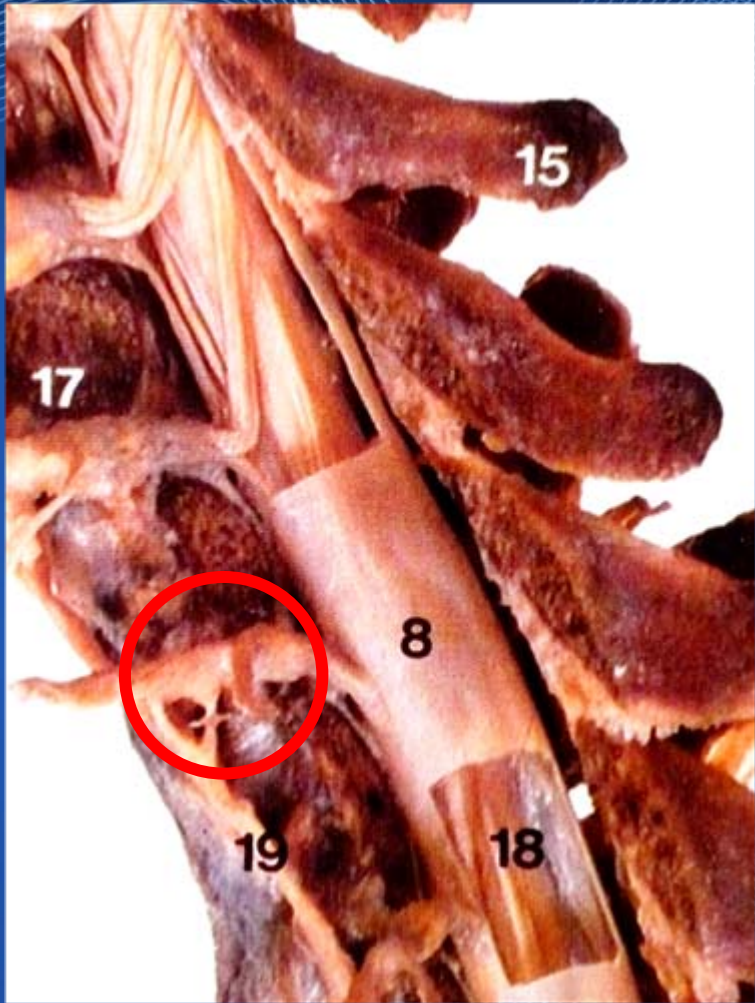
Buen
Equipamiento

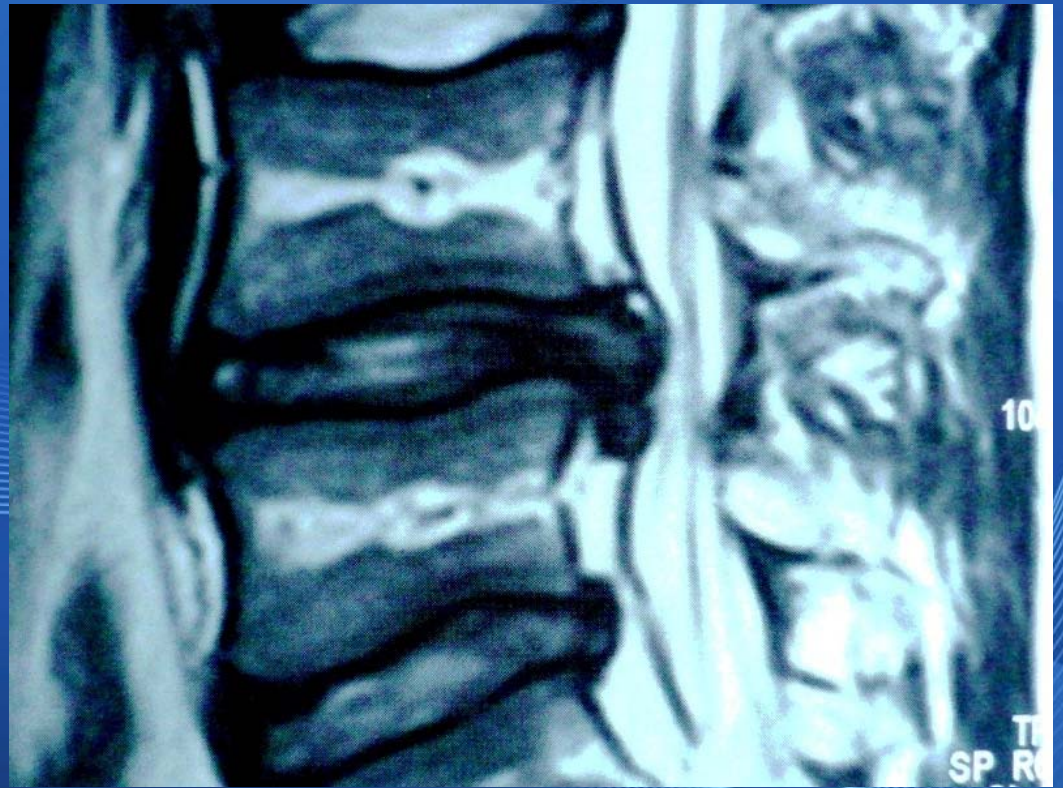
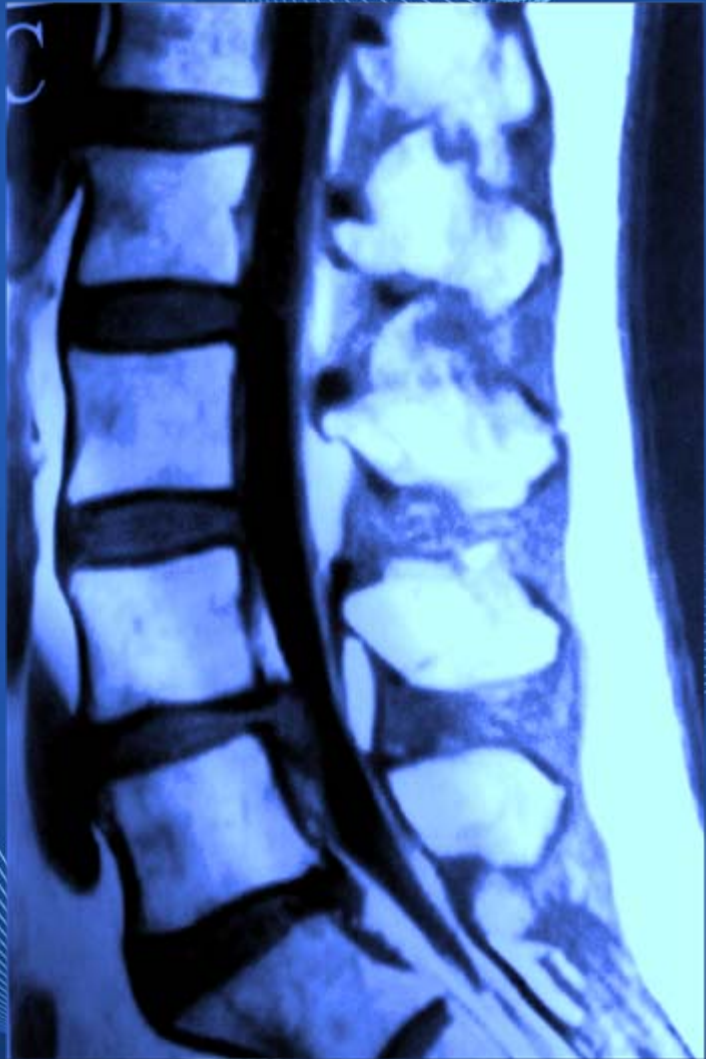


Técnicas Combinadas

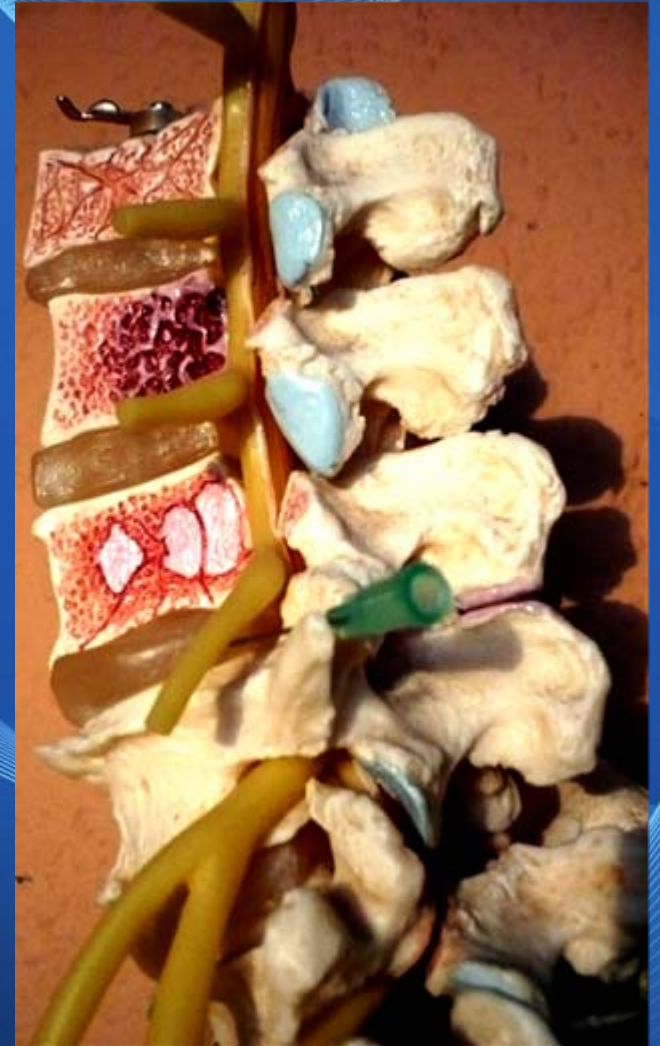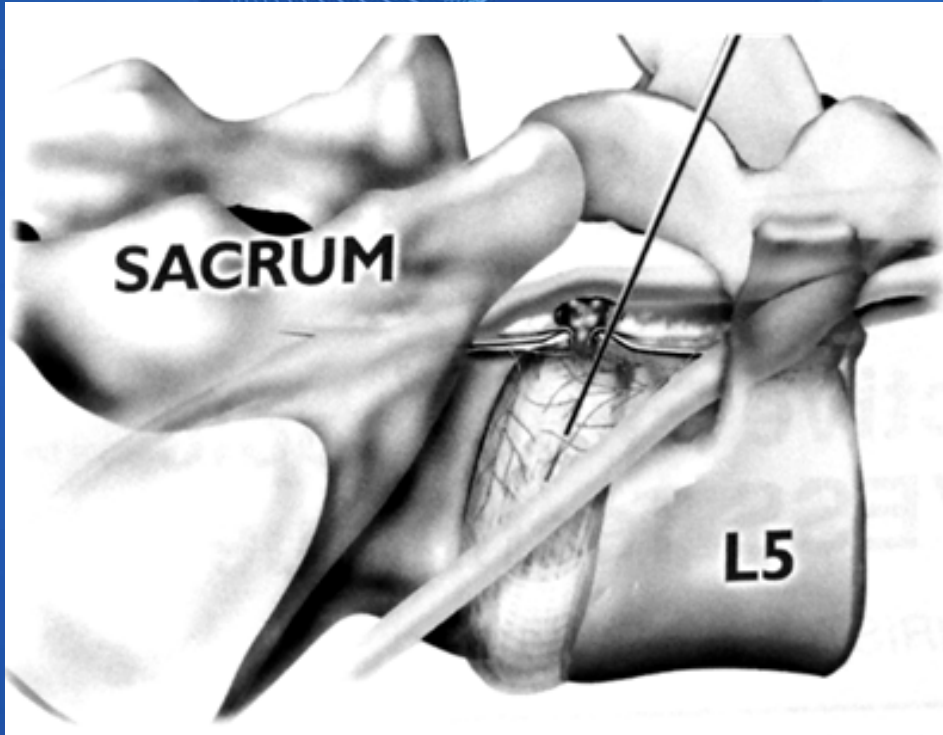




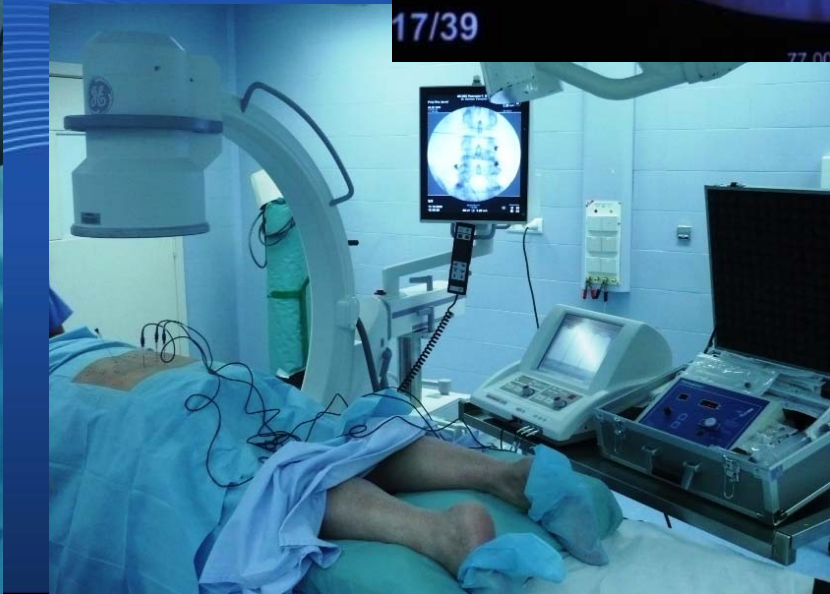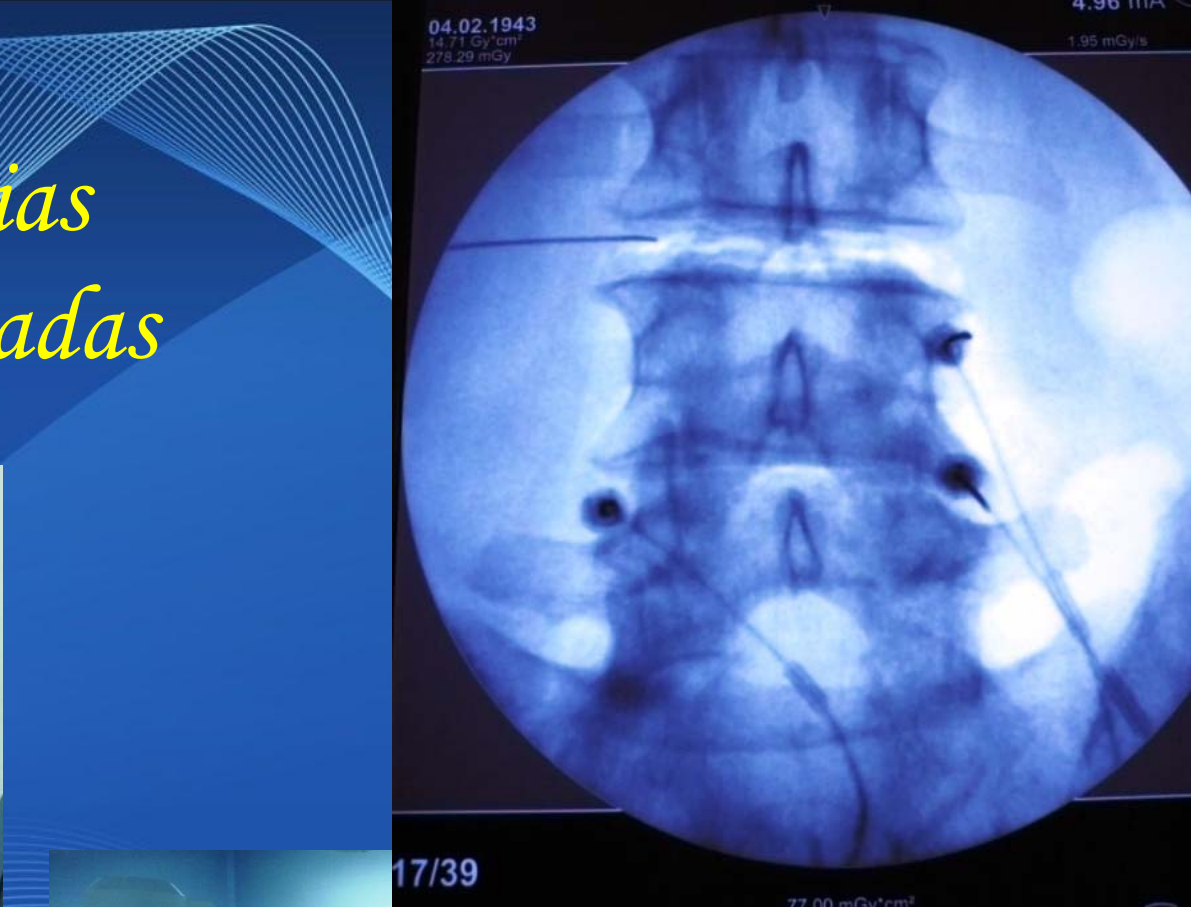


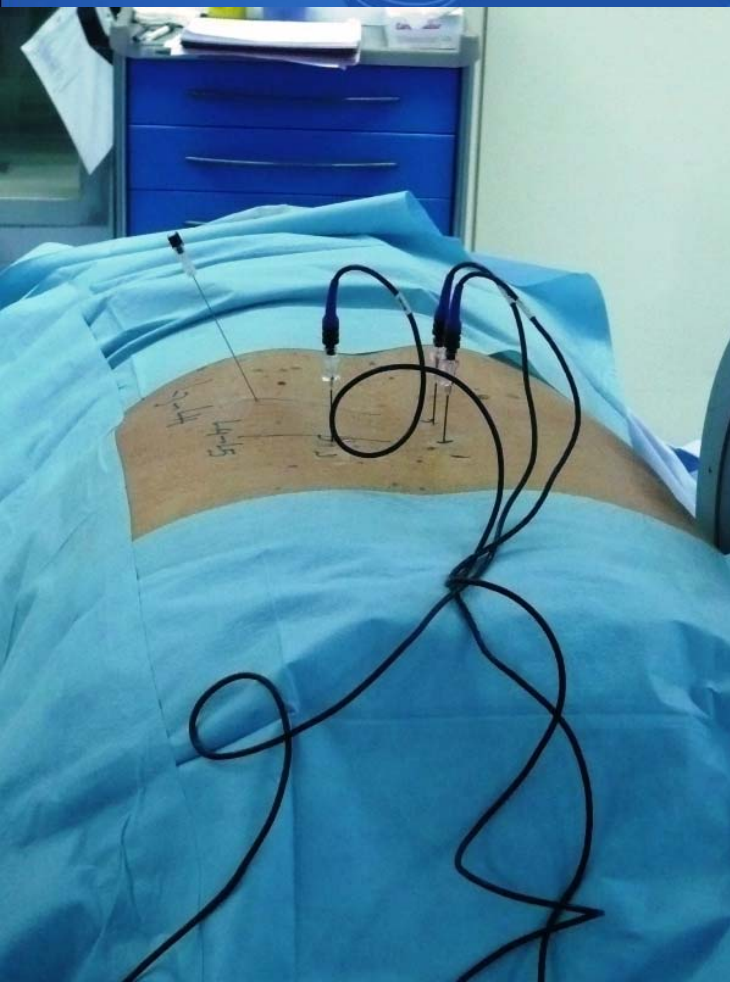

Anatomía Tridimensional



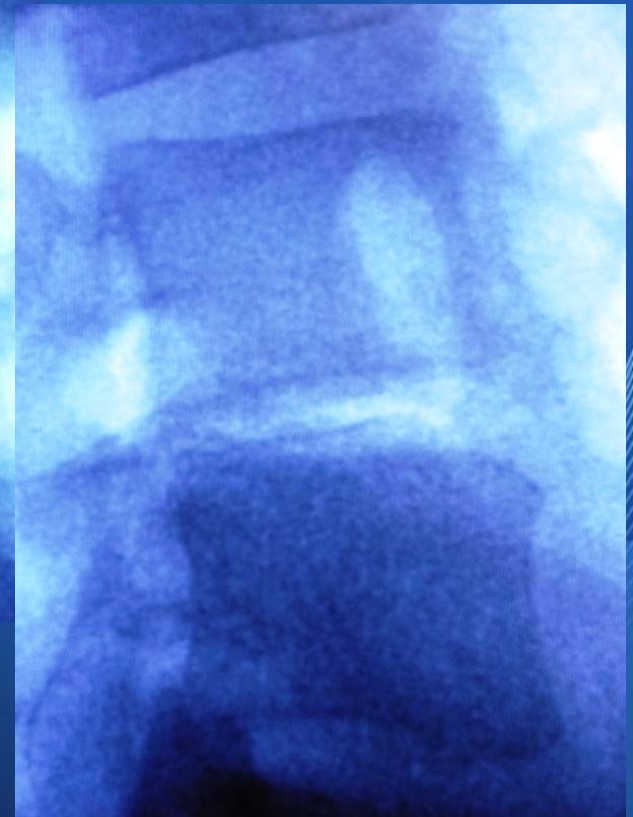
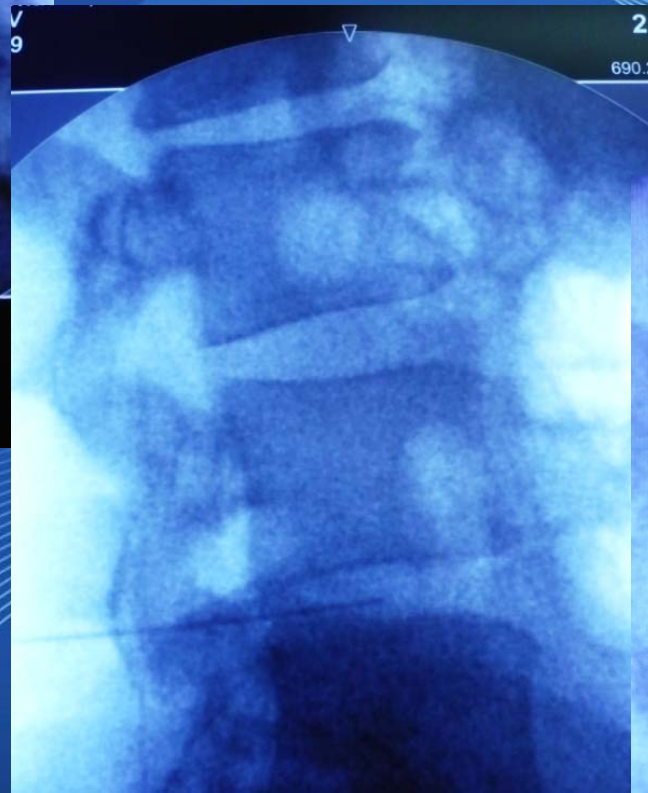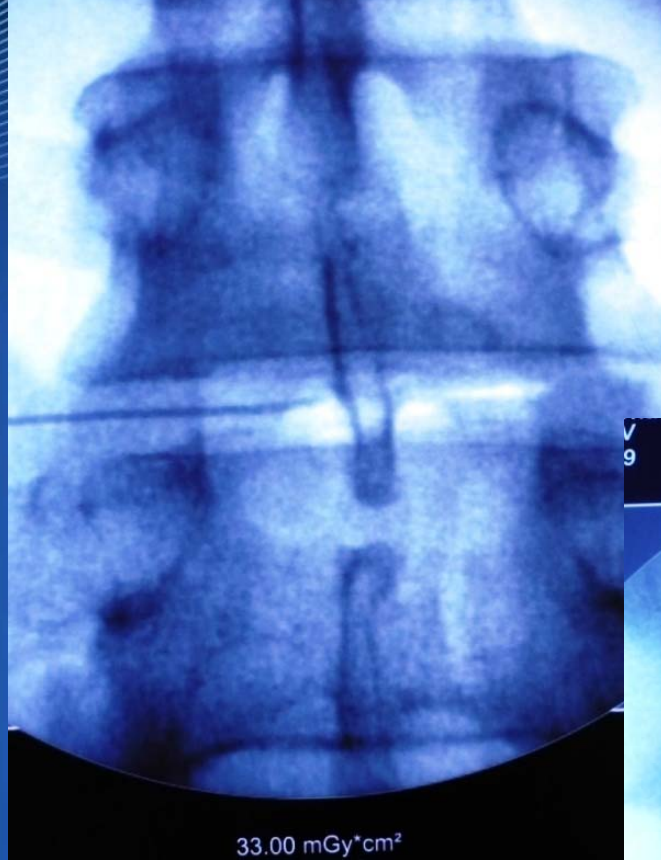
Terapias Combinadas



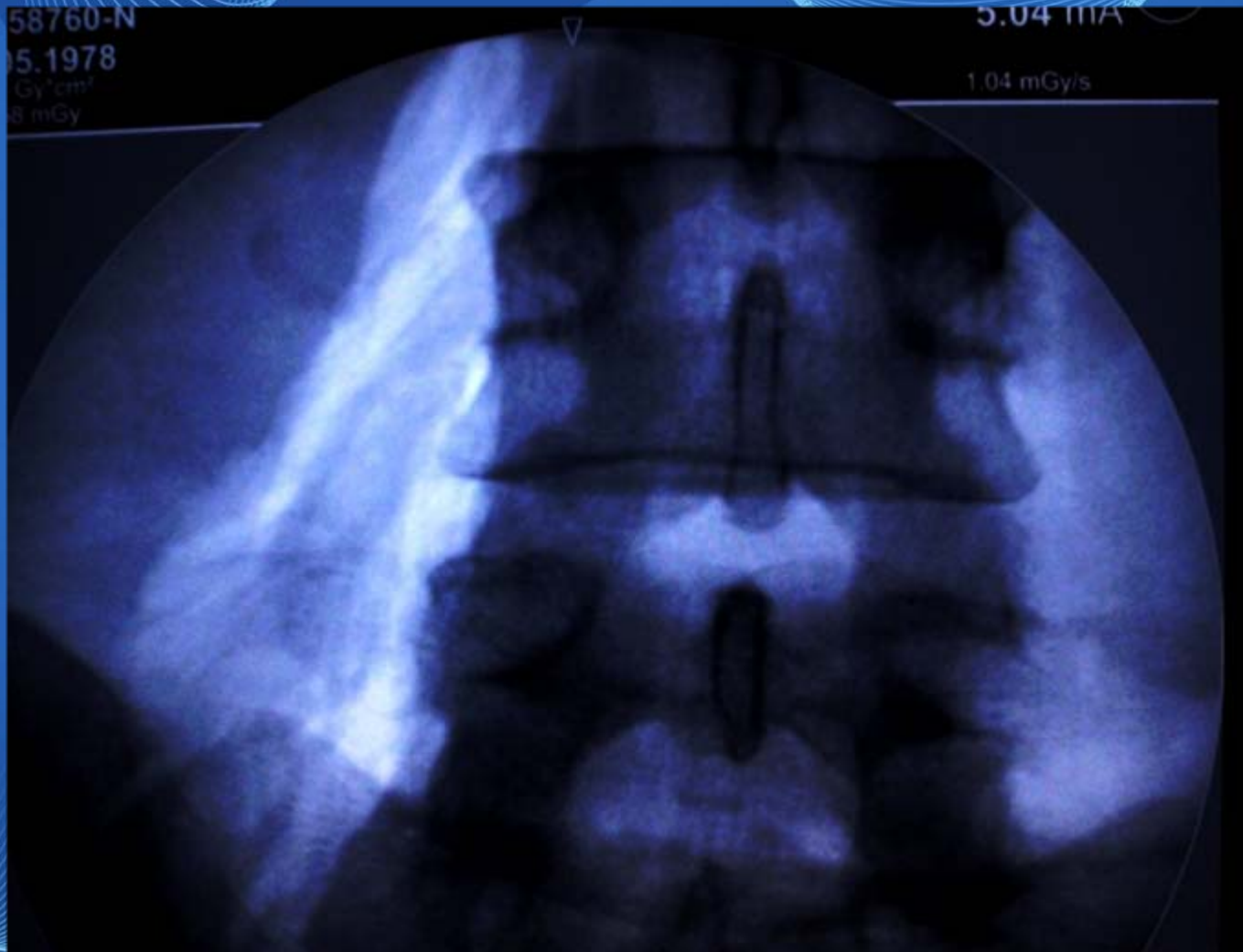17/39

77.00 mGy/cm²

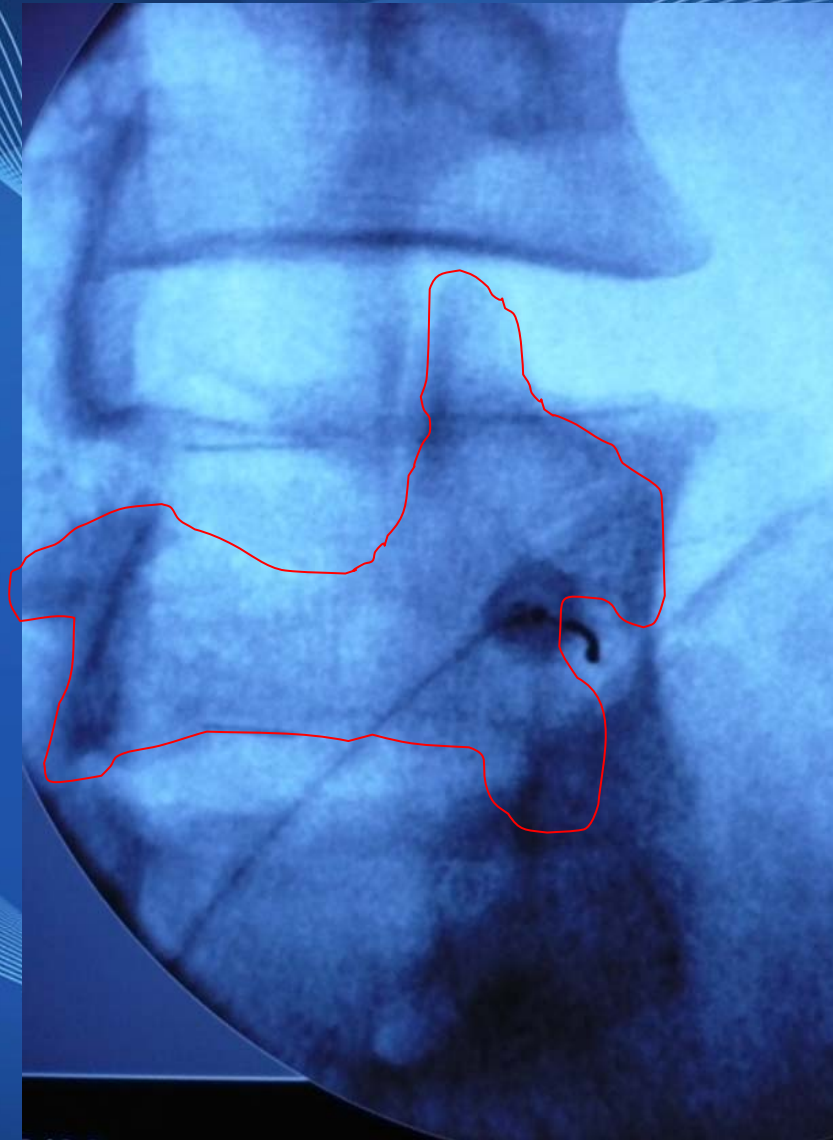
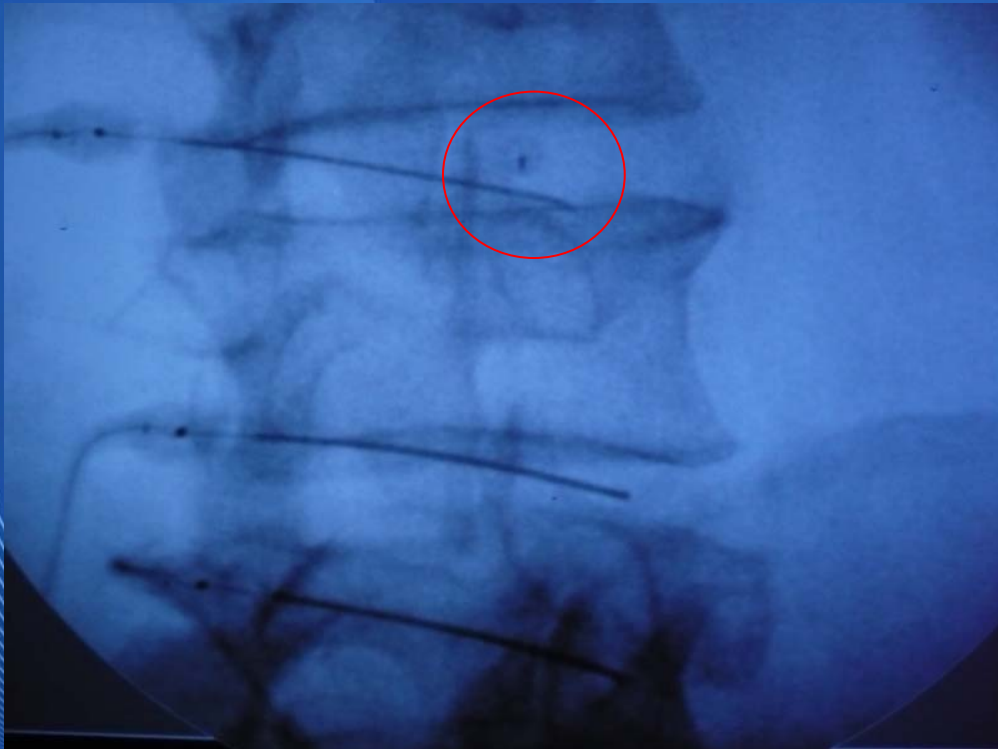
*Discolisis [4 – [5
con O2-O3*



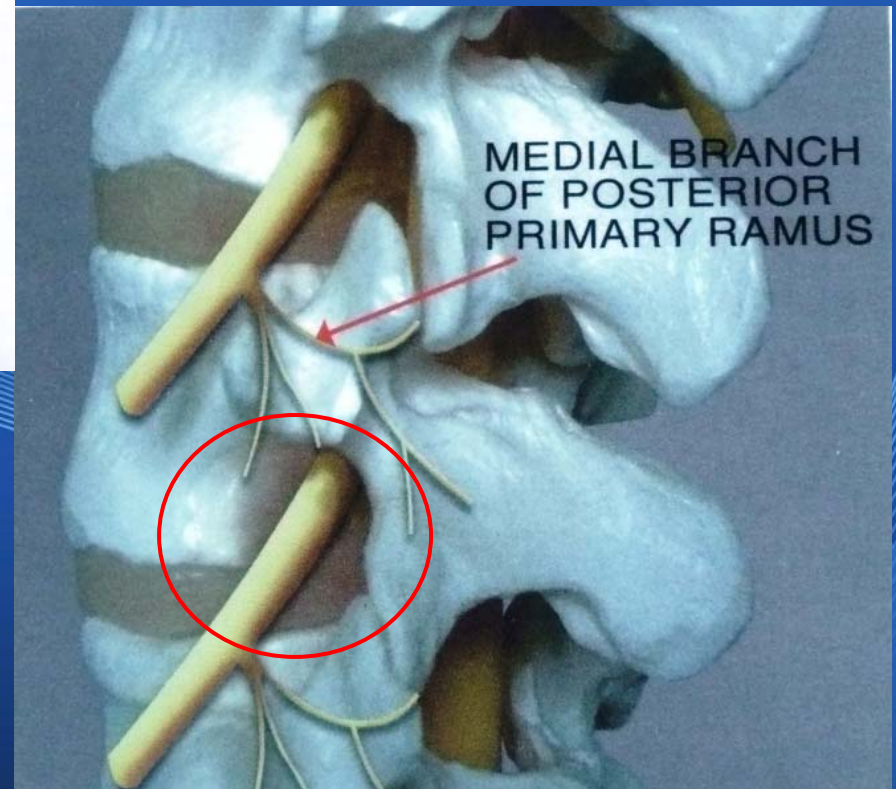
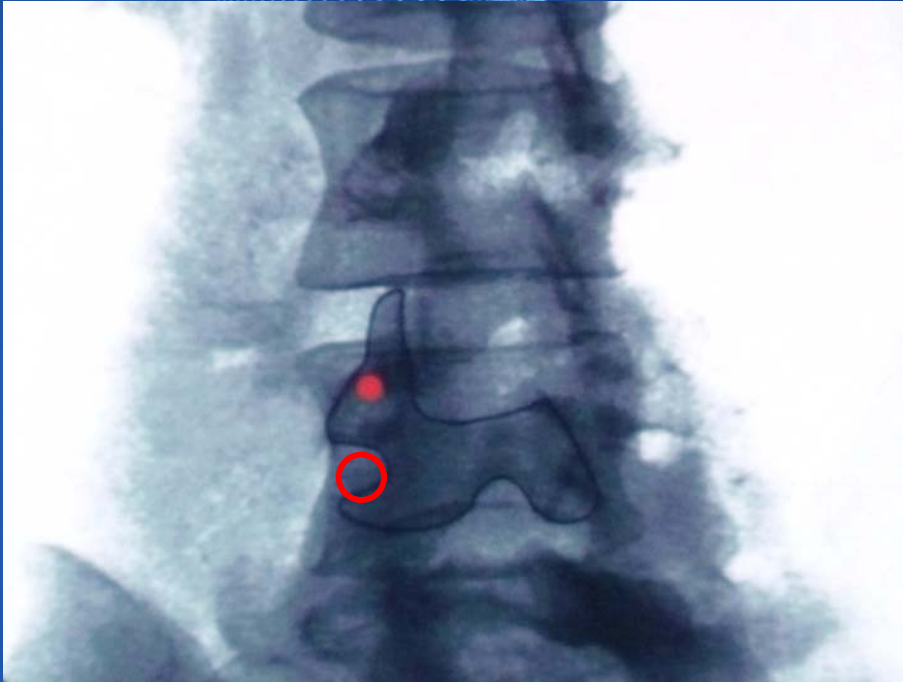
Rizonofisis



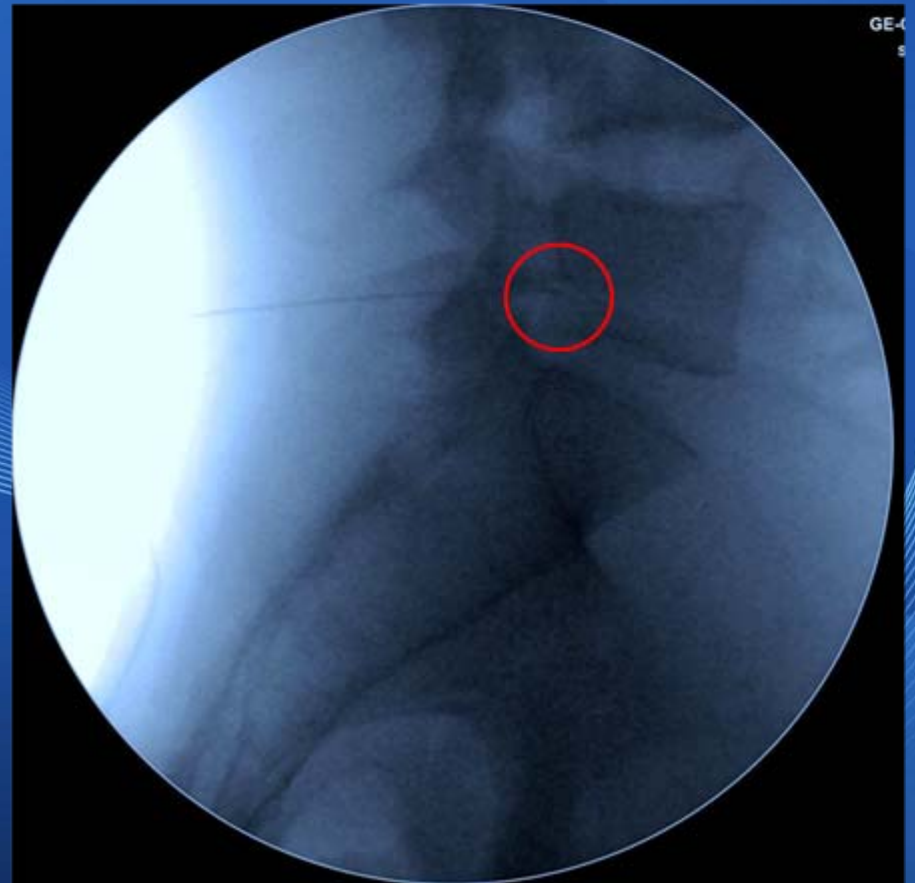
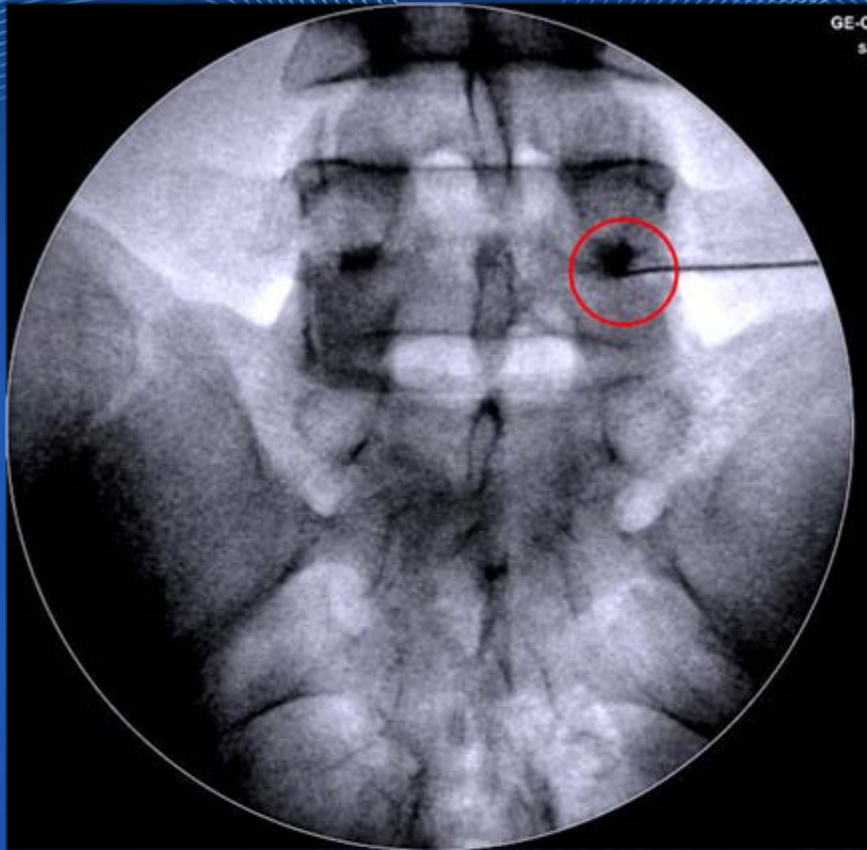
Marcación Previa a Rizonolisis



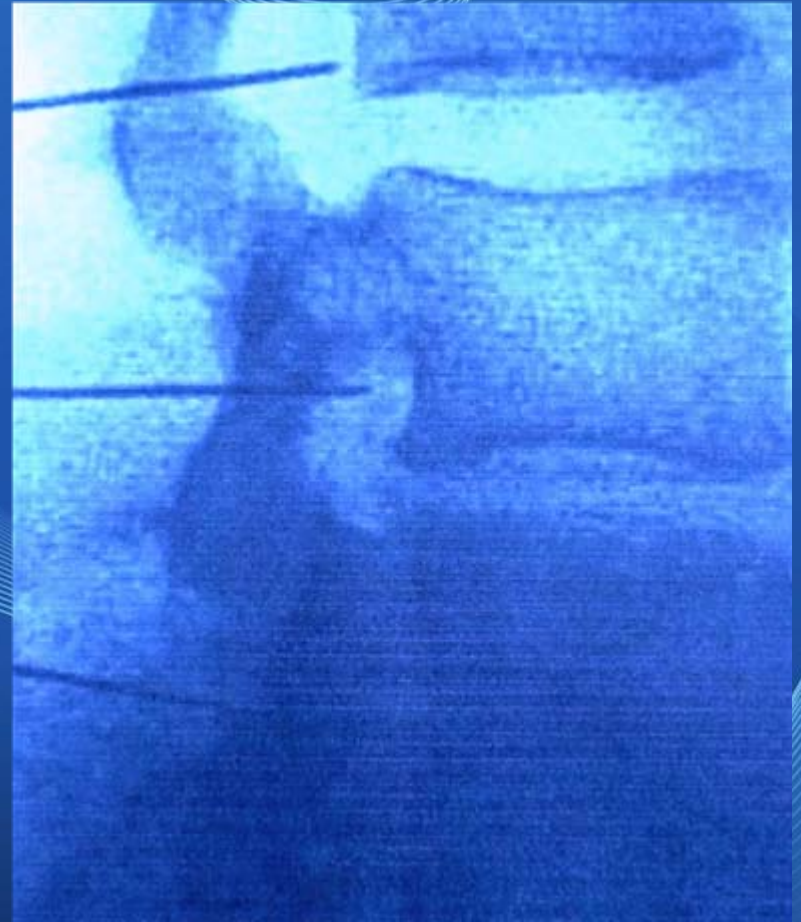
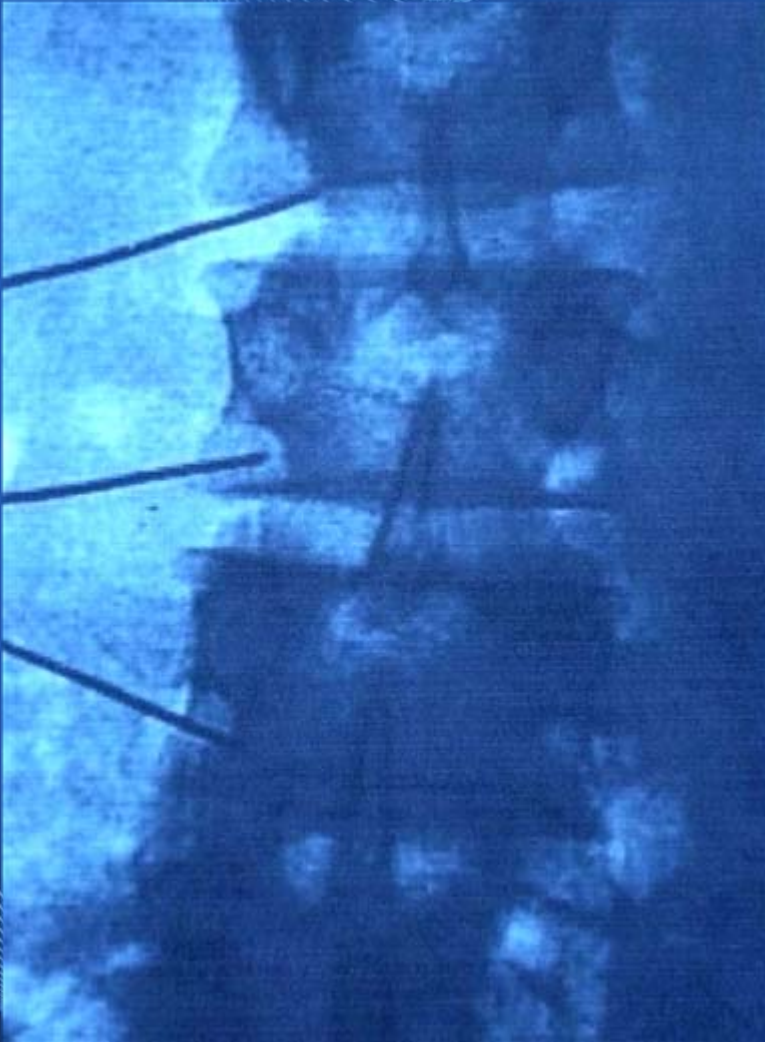Perrito de "La Chapelle"



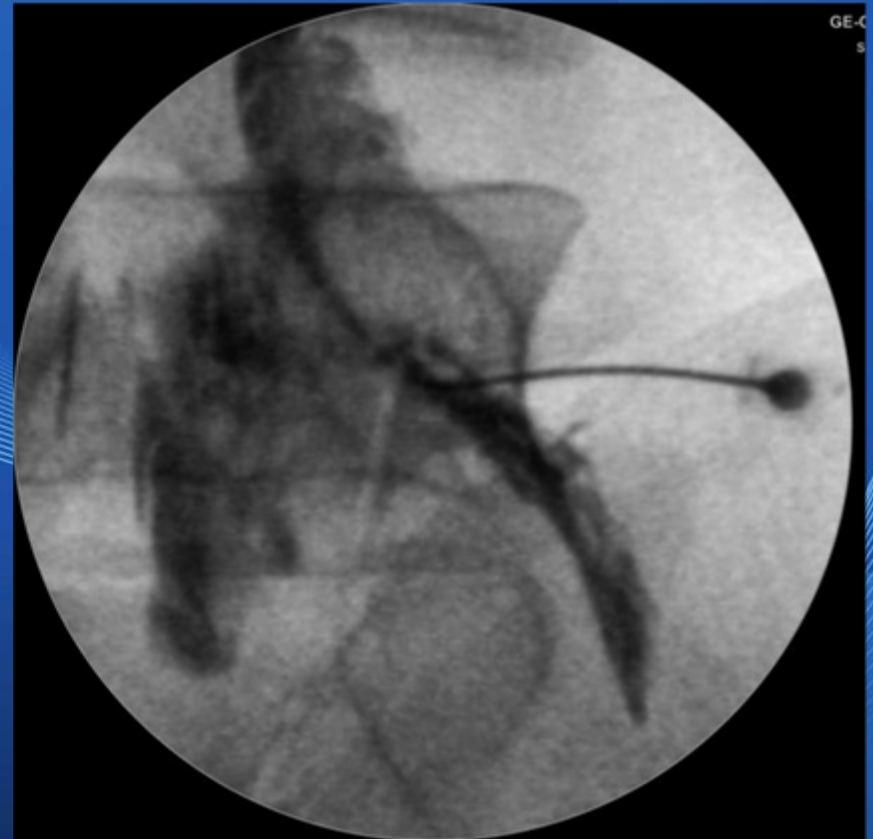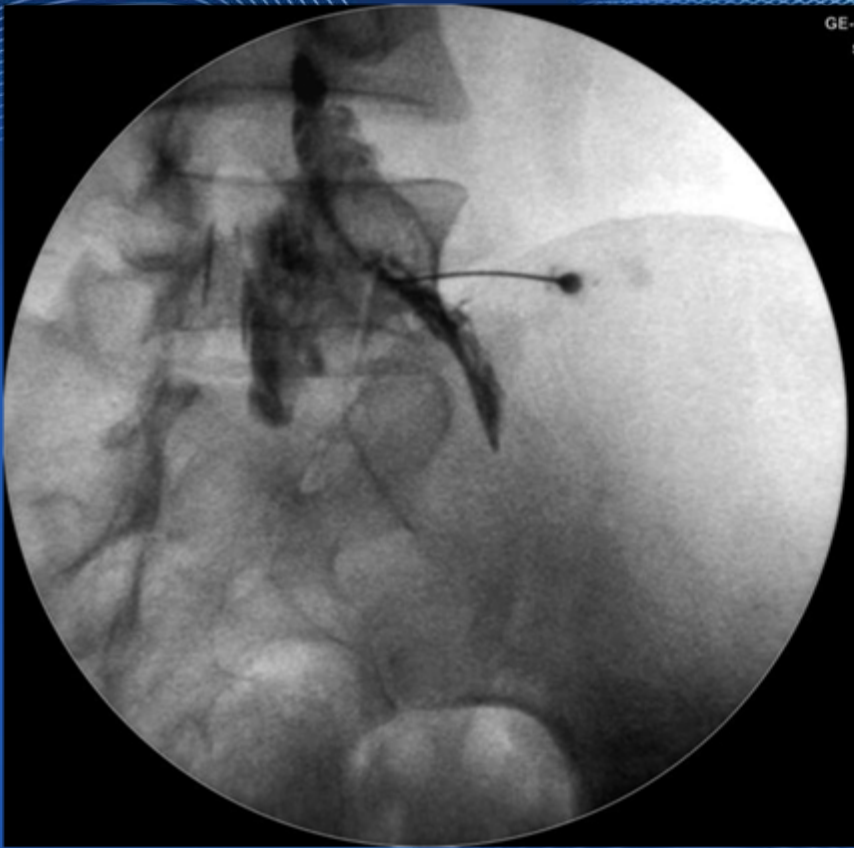
*Abordaje al Foramen
por incidencia Rx A-P*

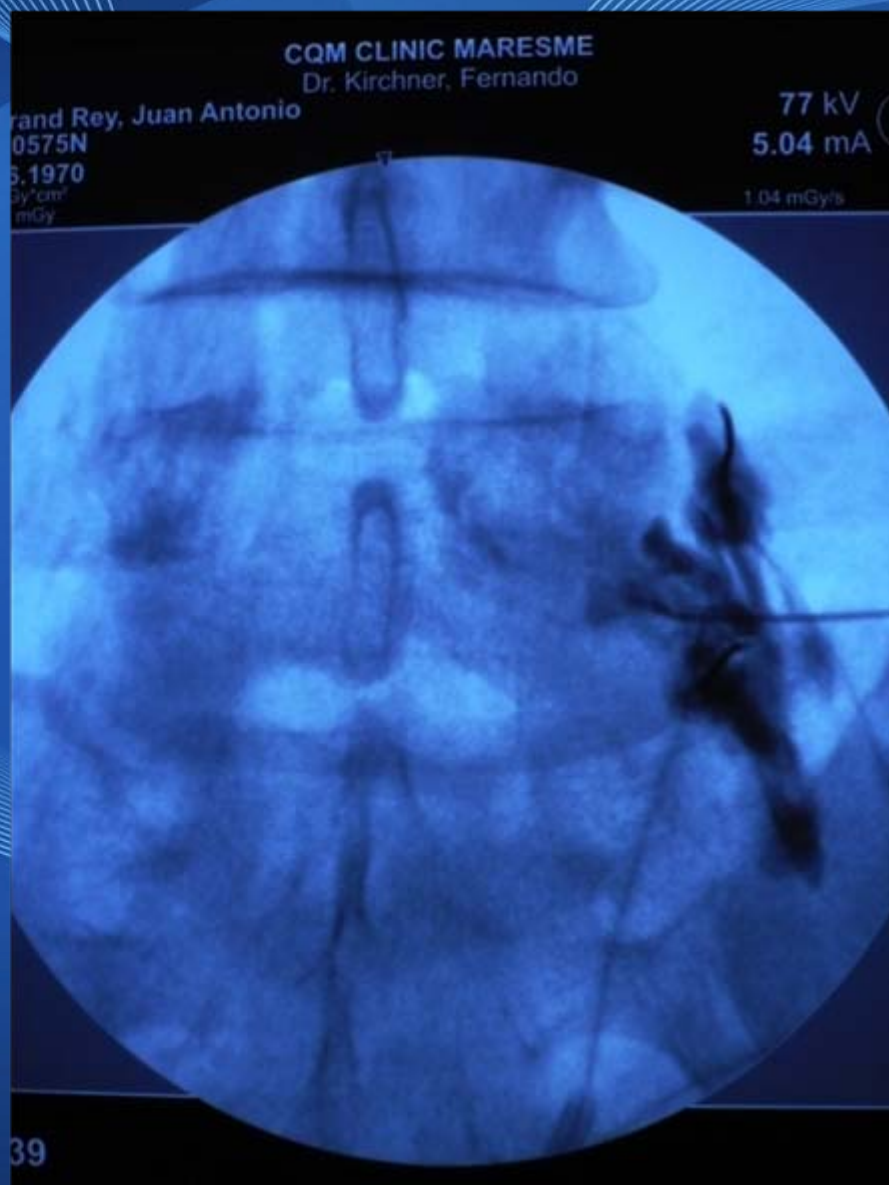
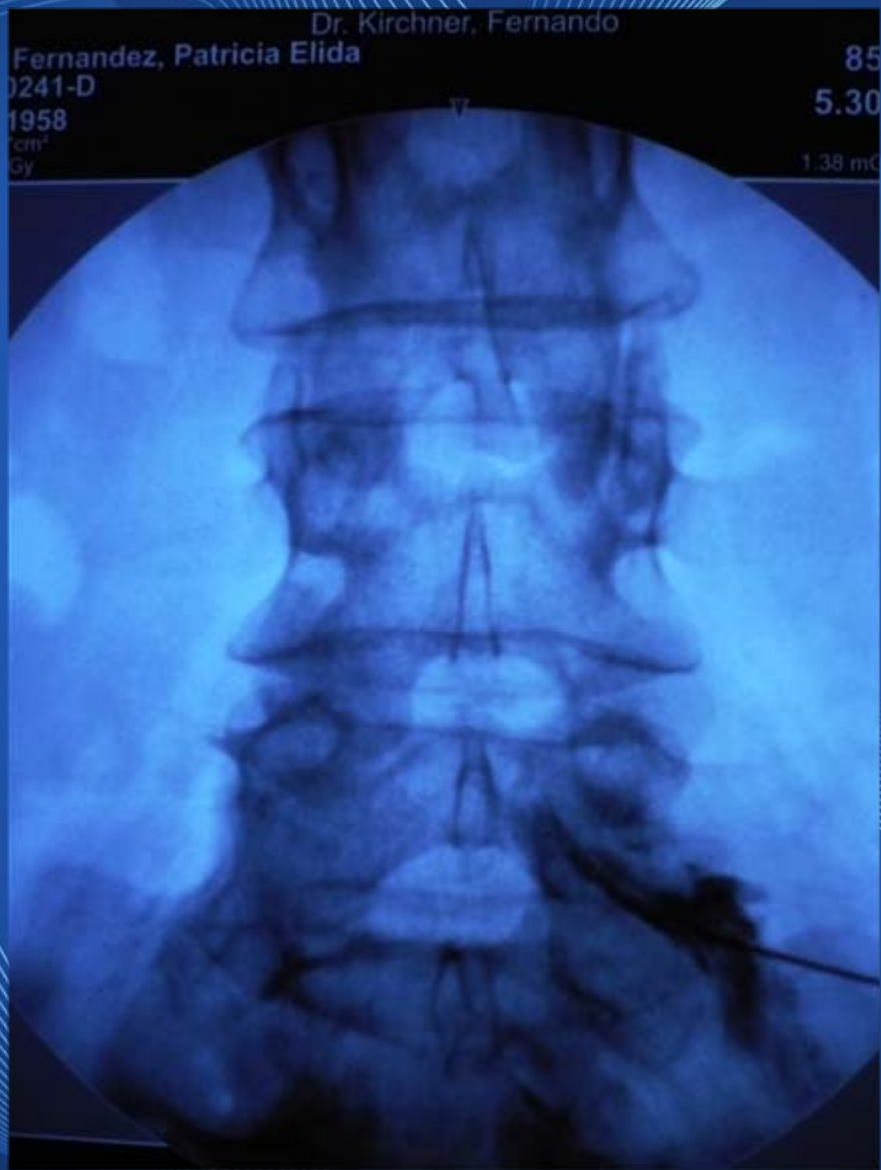

Constatación Radiológica Frente y Perfil

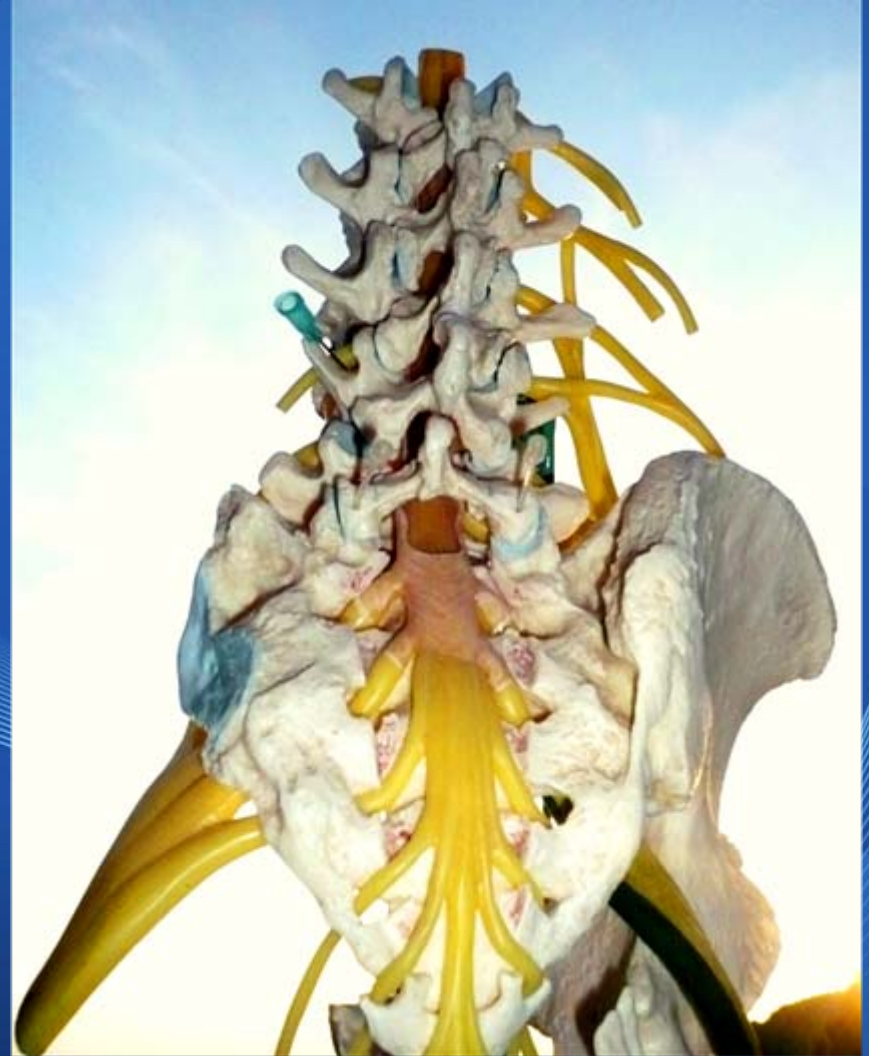
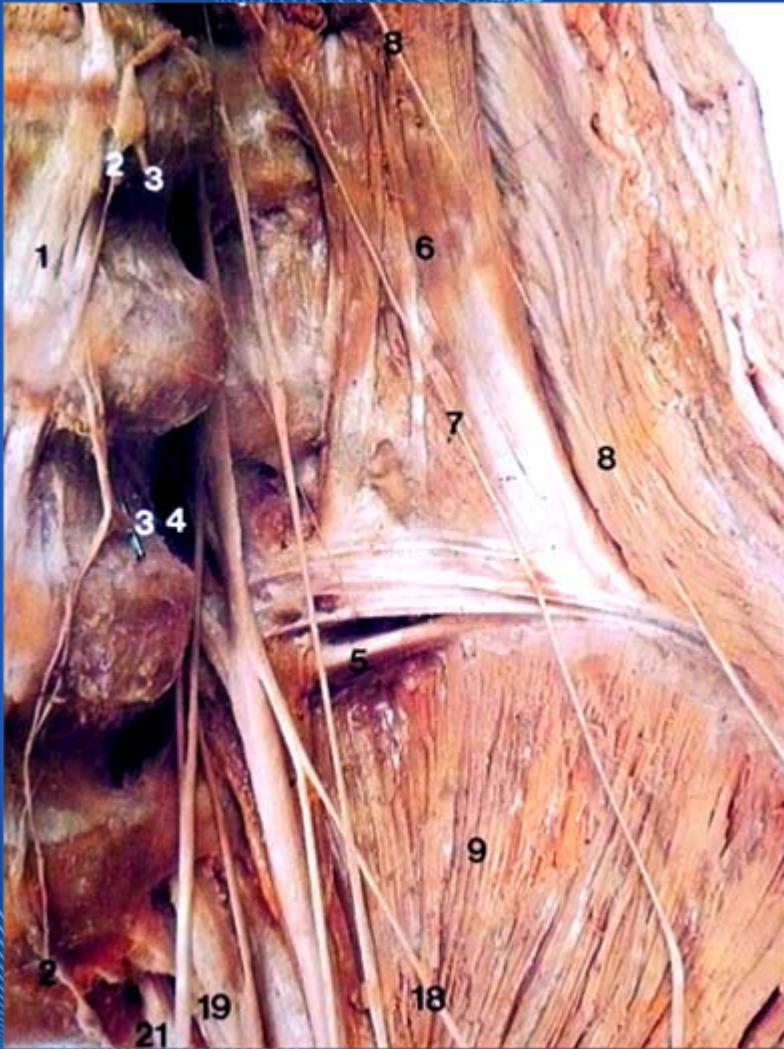
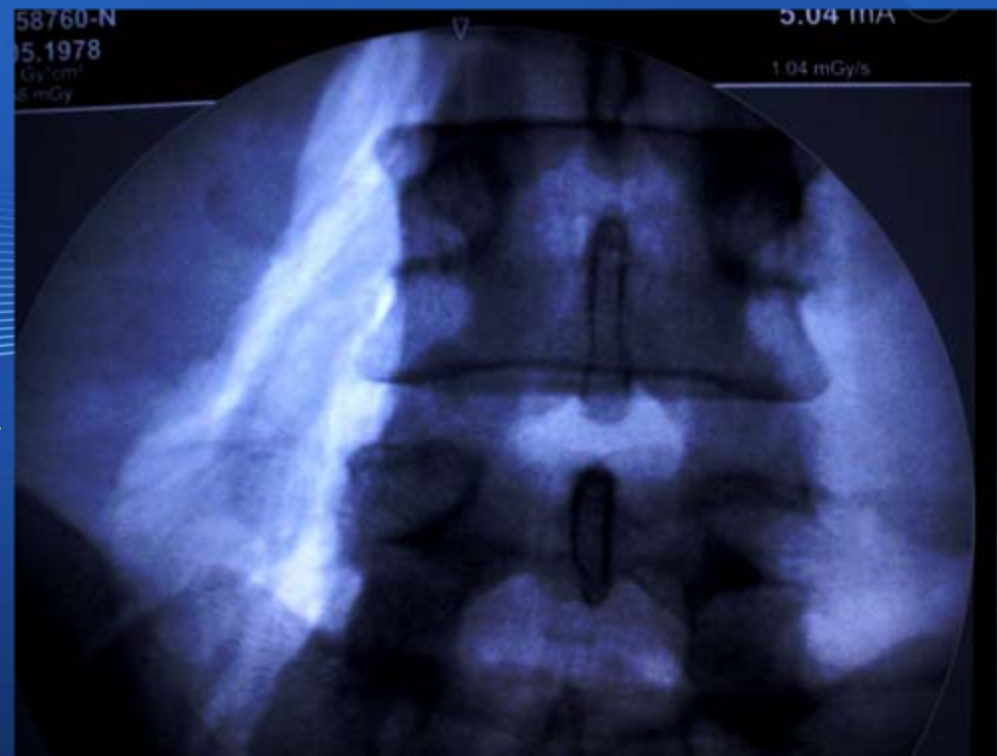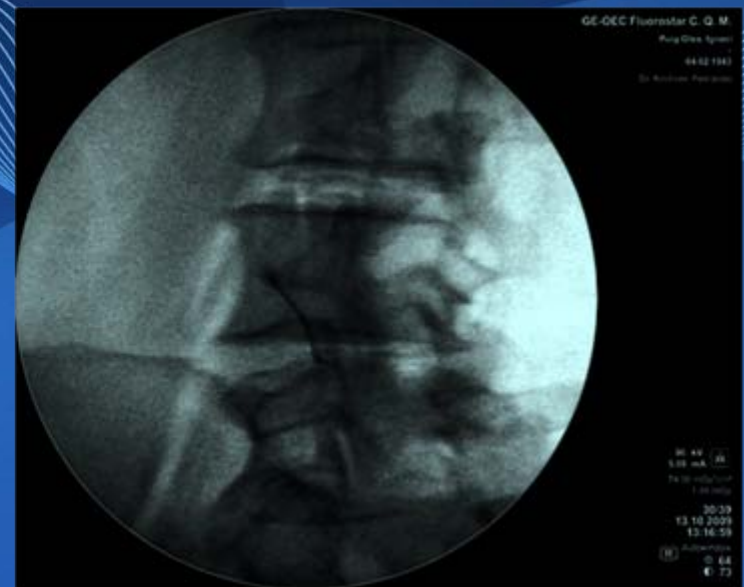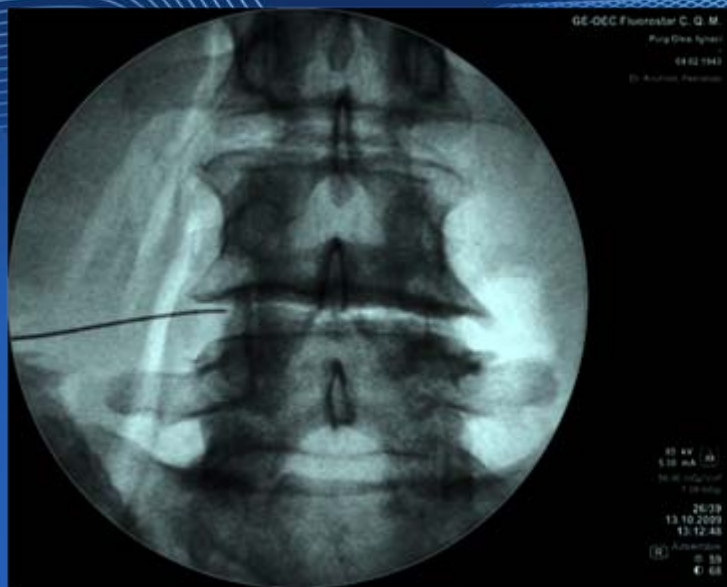*Contraste Previo a la
Rizonolisis*





Raíces

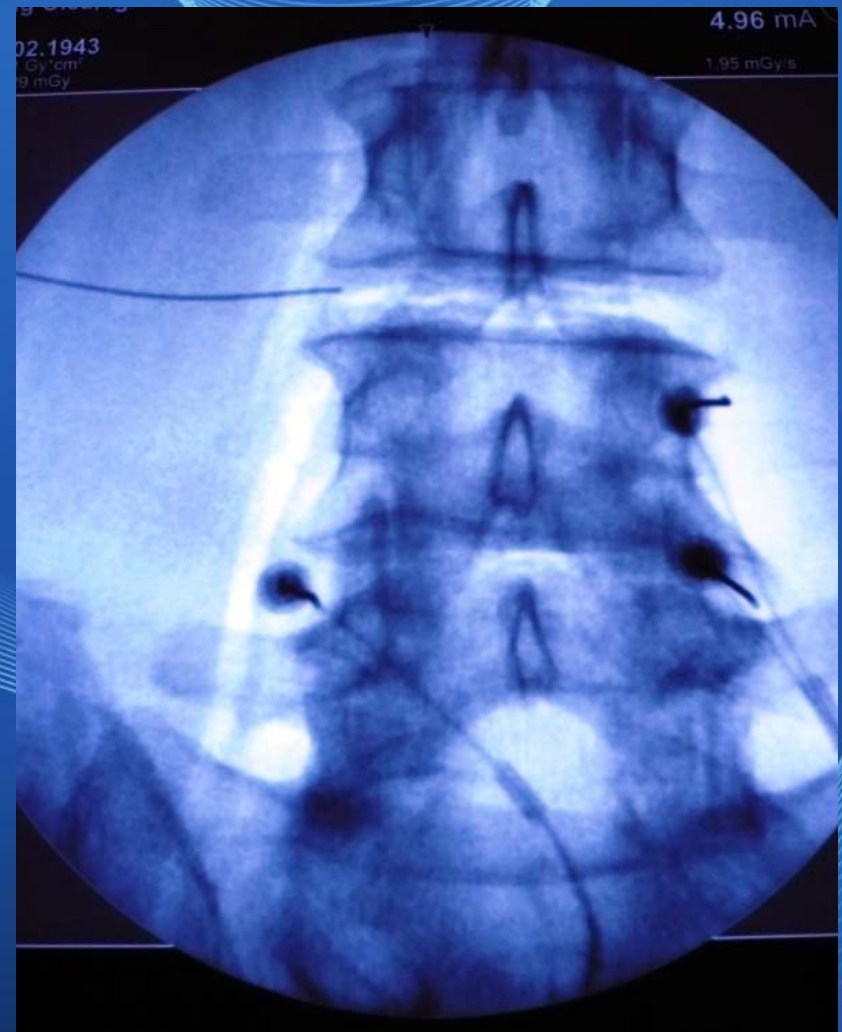
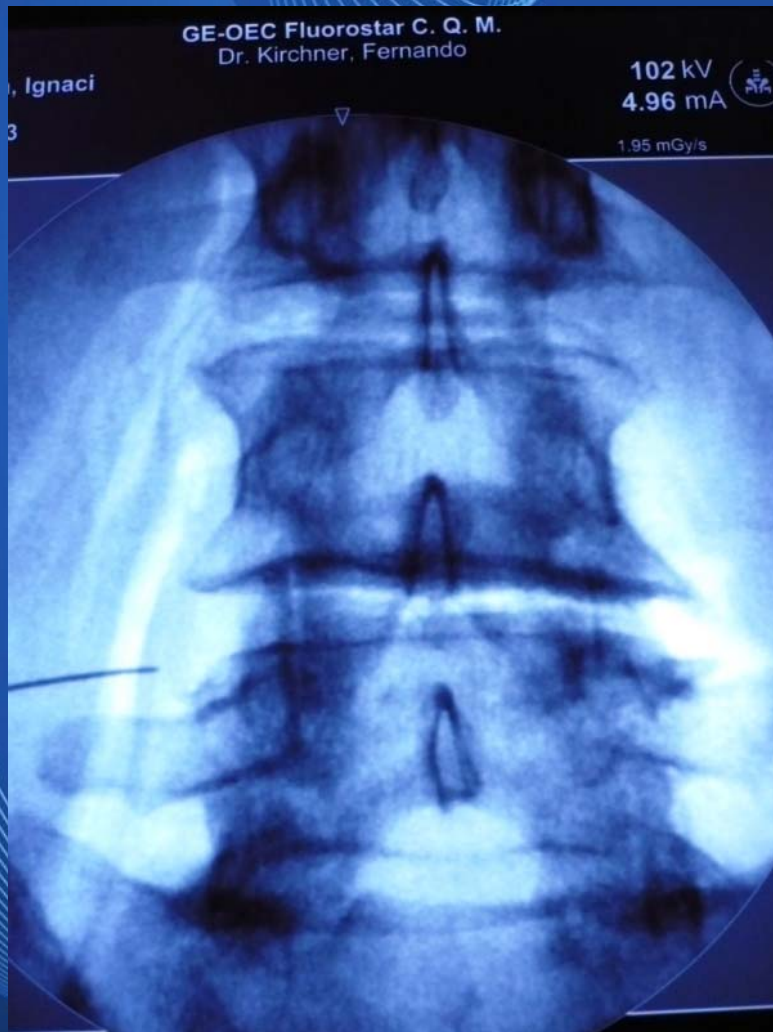


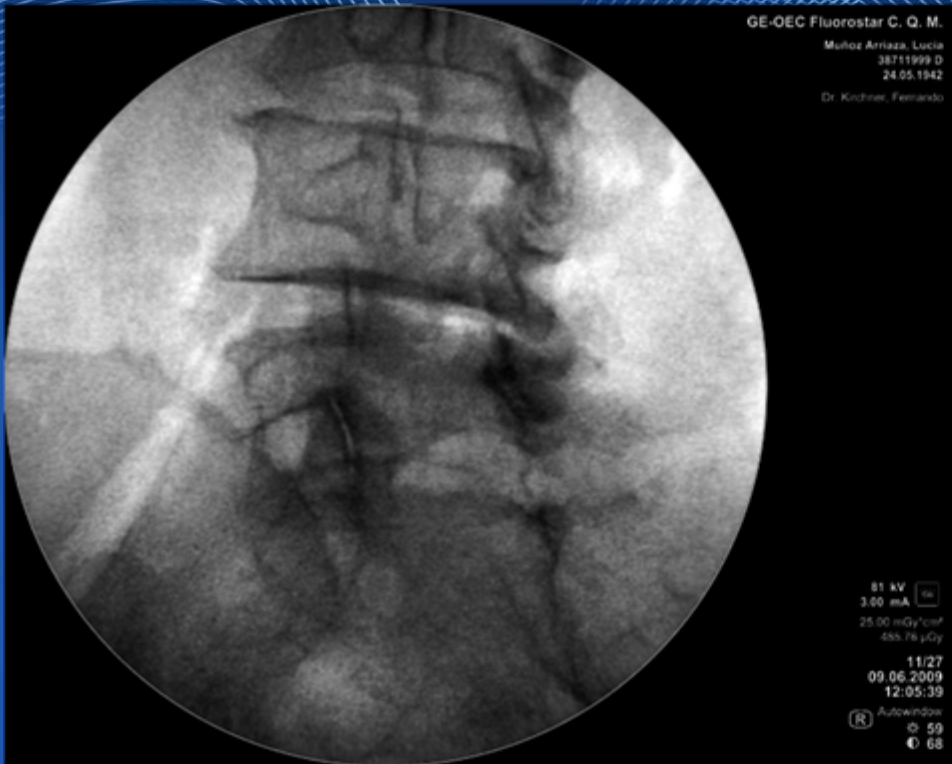

Rizonolisis

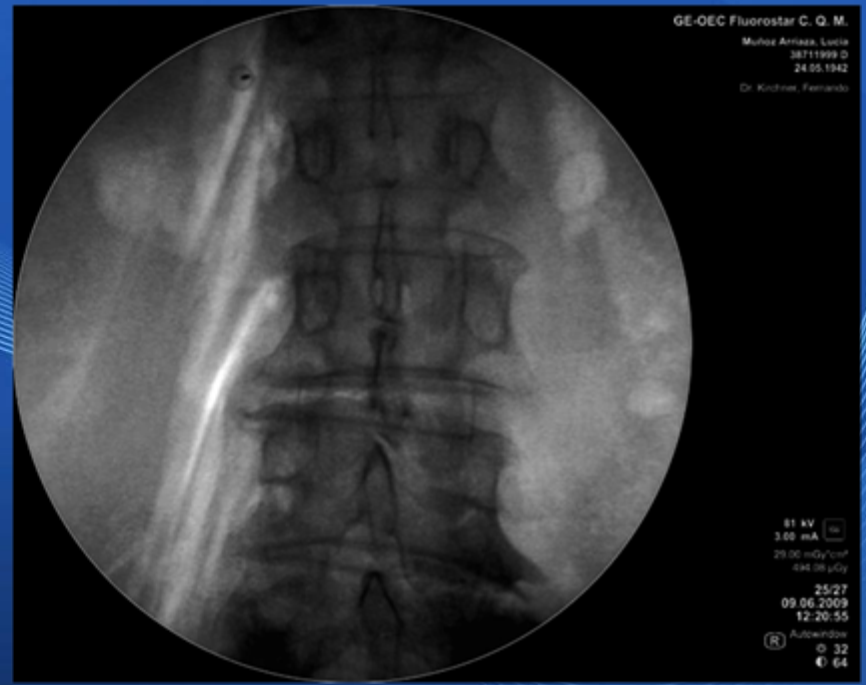
Dos casos Clínicos

Neurorrizolisis con RFP + Discolisis con Ozono + Ozono Foraminal y Raíces



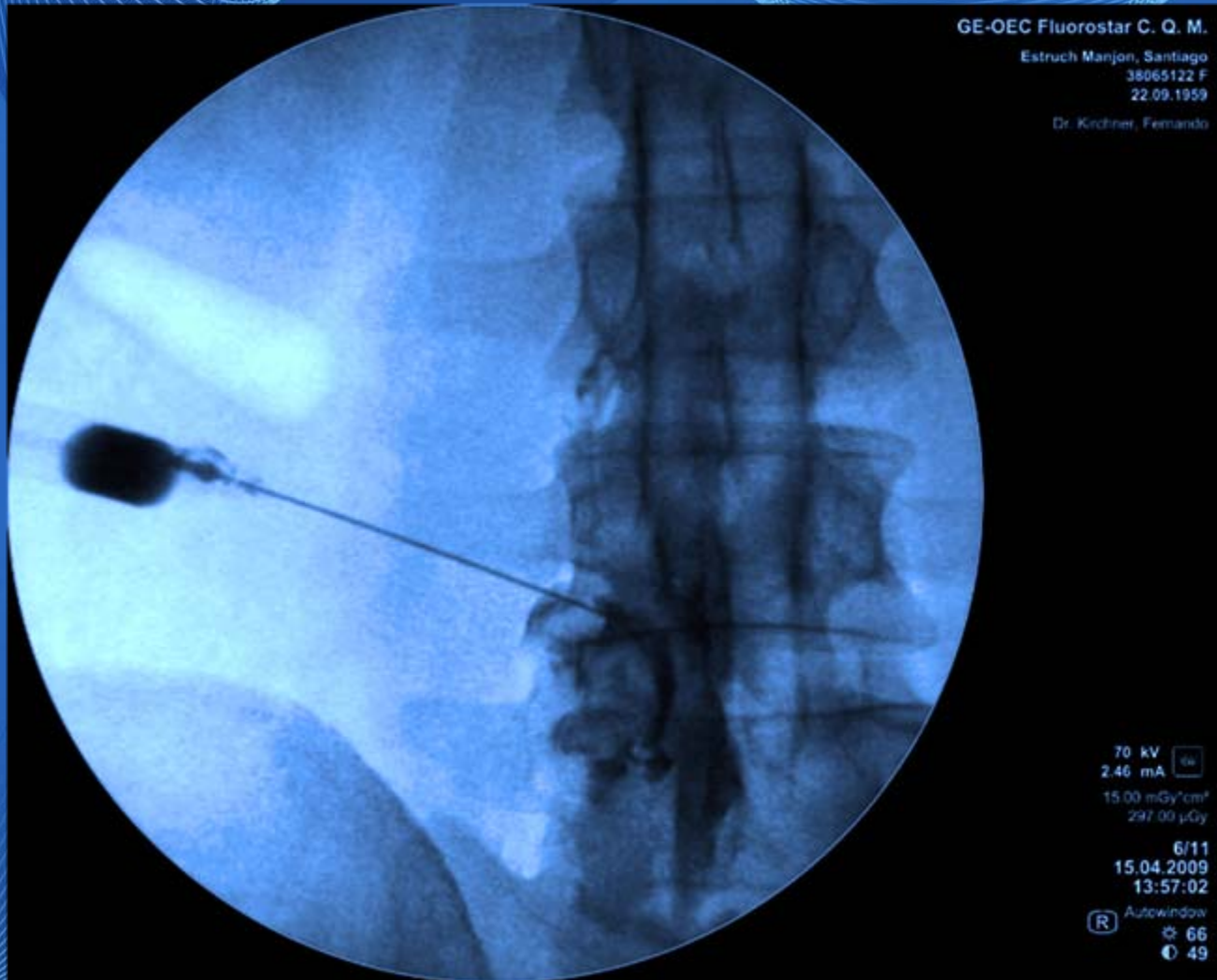


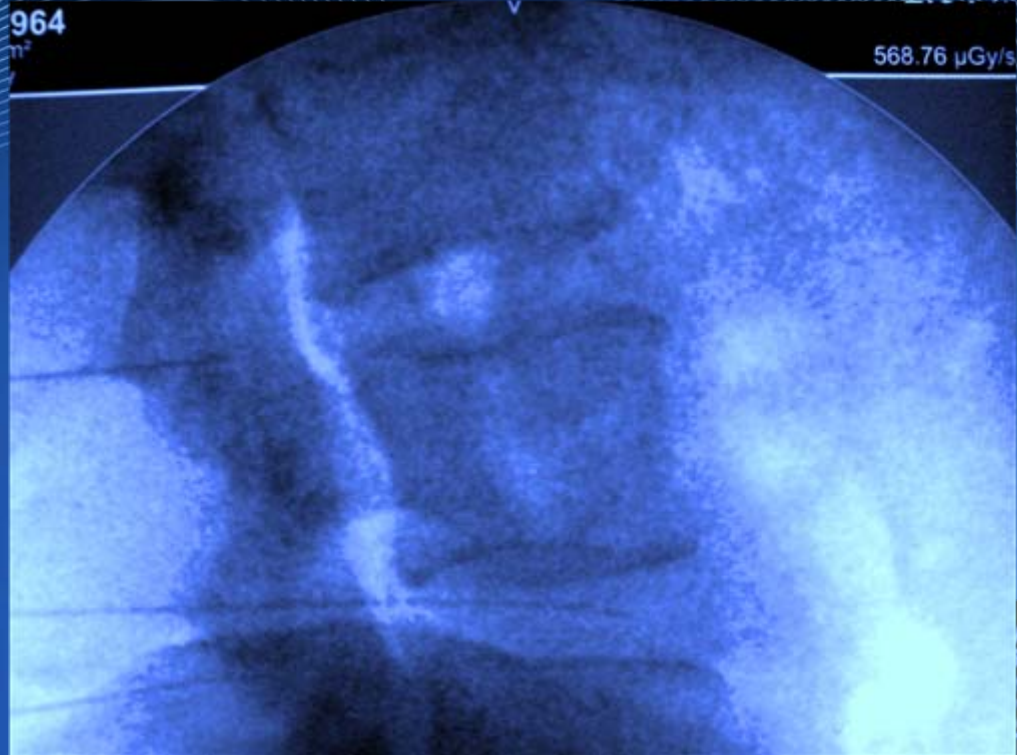
Vista Radiológica – Perfil y Frente Rizonolisis



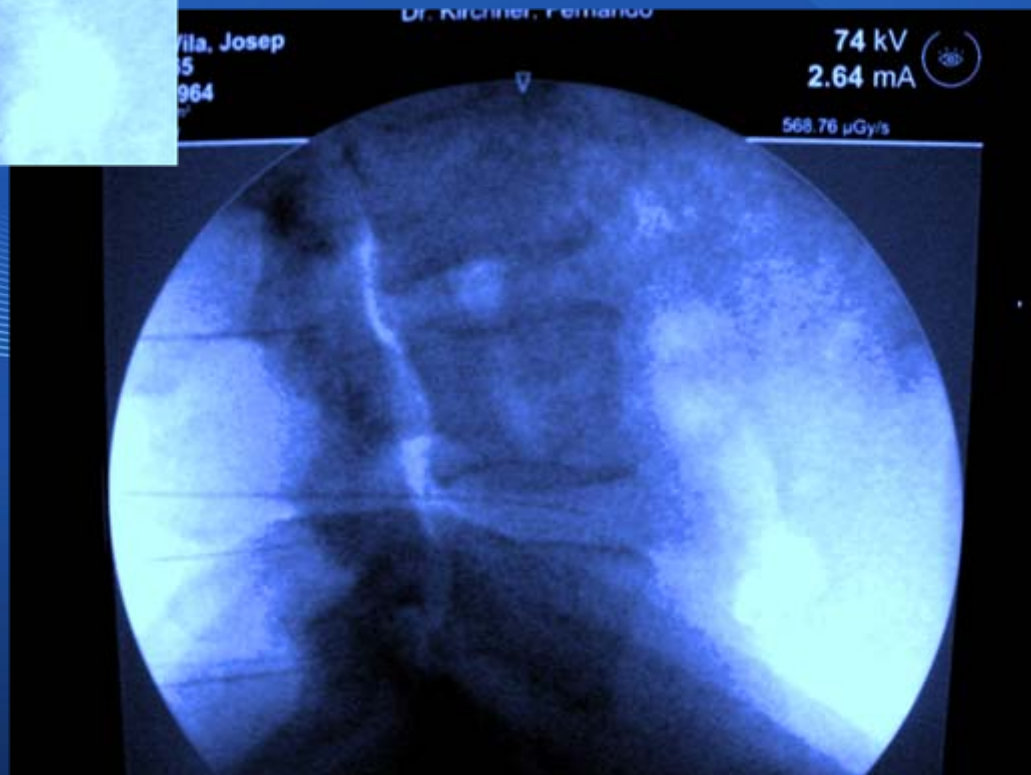
Epidural con Ozono

-Contraste Previo-

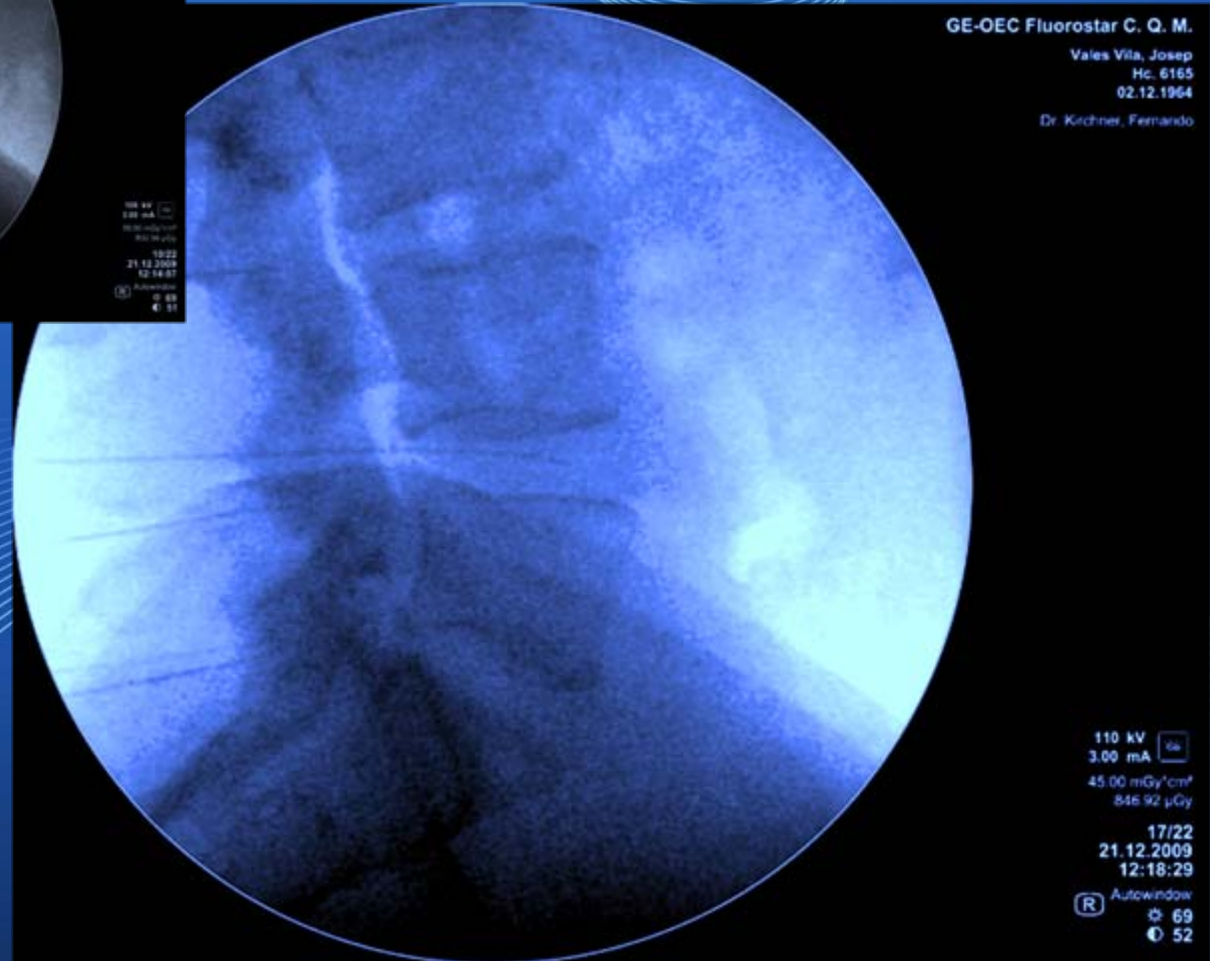
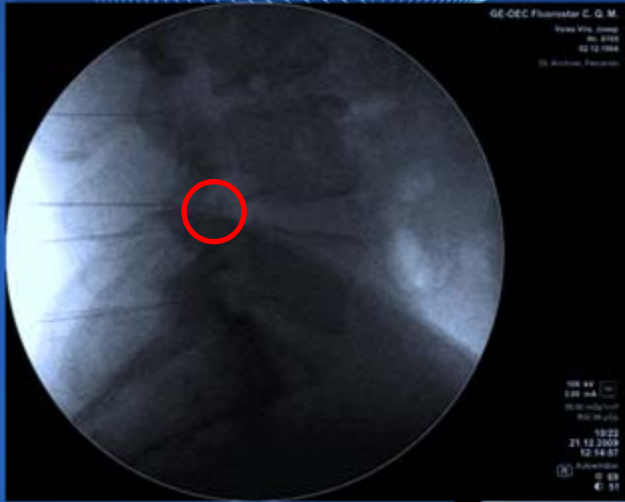



Epidural con Ozono



Epidural con Ozono



CQM CLINIC MARESME

Dr. Kirchner, Fernando

Portabella, Mercedes

96V

936

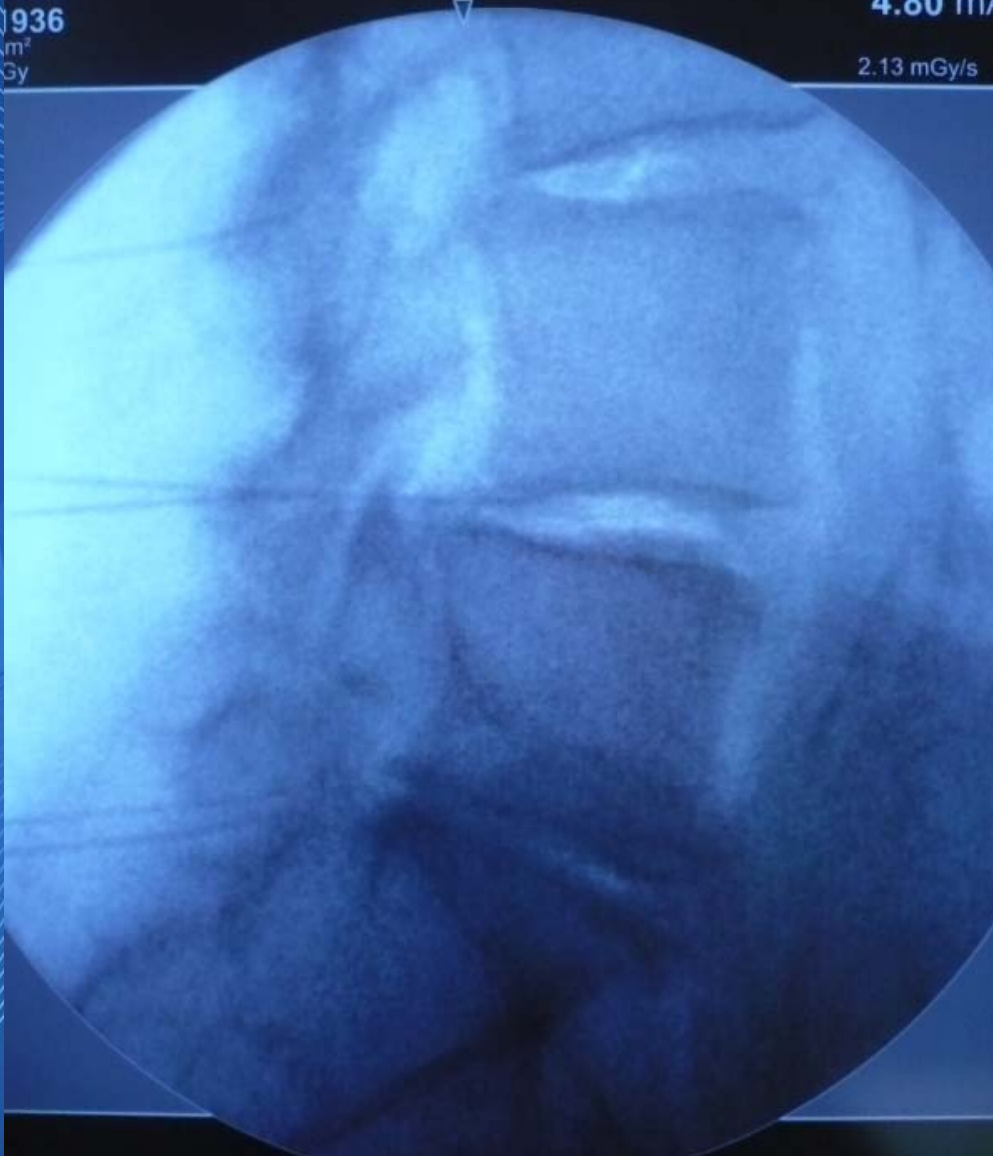m²

Gy

110 kV

4.80 mA

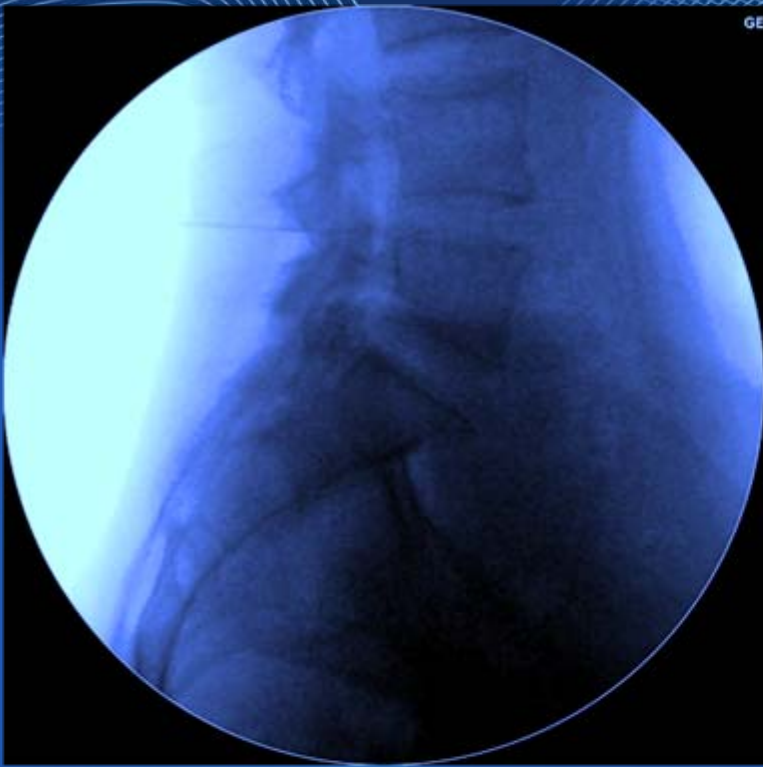2.13 mGy/s



GE-OEC Fluorostar C. Q. M.

Salan Artigas, Vanesa
38149587 Q
18.03.1981

Dr. Kirchner, Fernando
Discos Lumbares



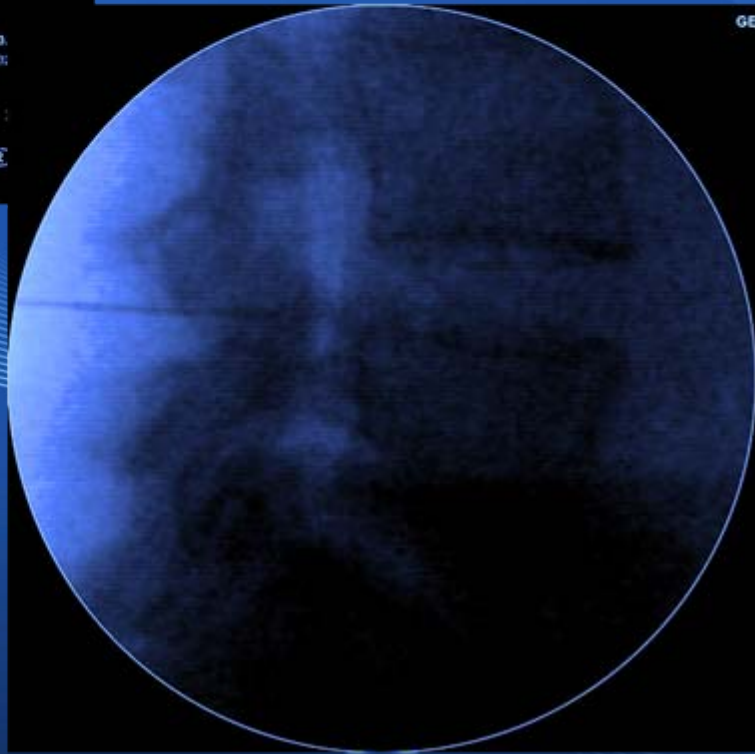
3
3
:
R

Epidural con Ozono

GE-OEC Fluorostar C. Q. M.

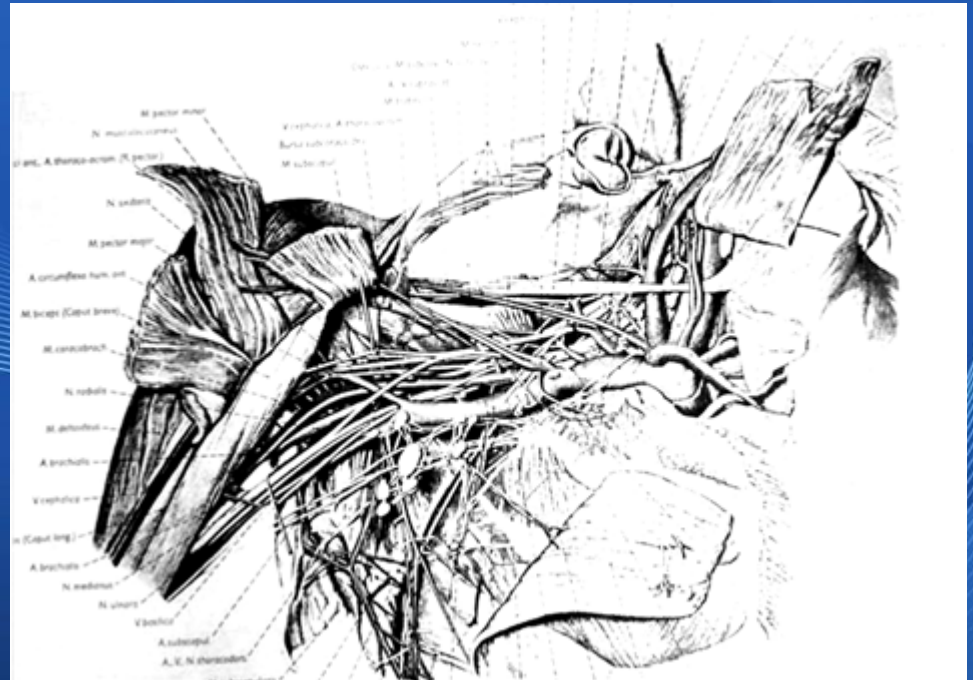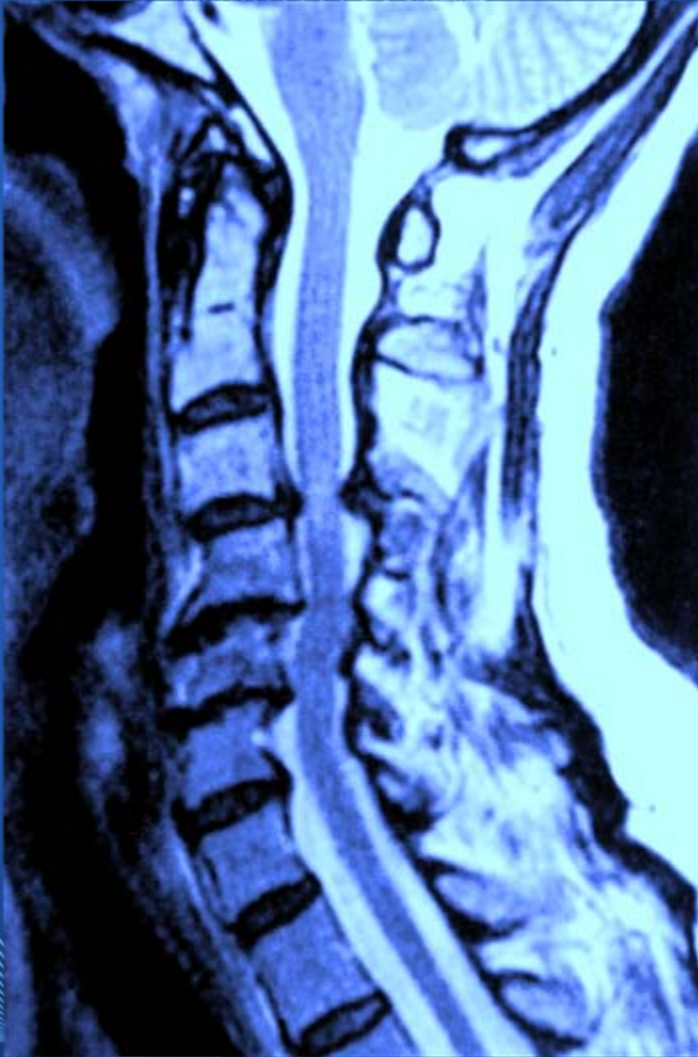Salan Artigas, Vanesa
38149587 Q
18.03.1981

Dr. Kirchner, Fernando
Discos Lumbares

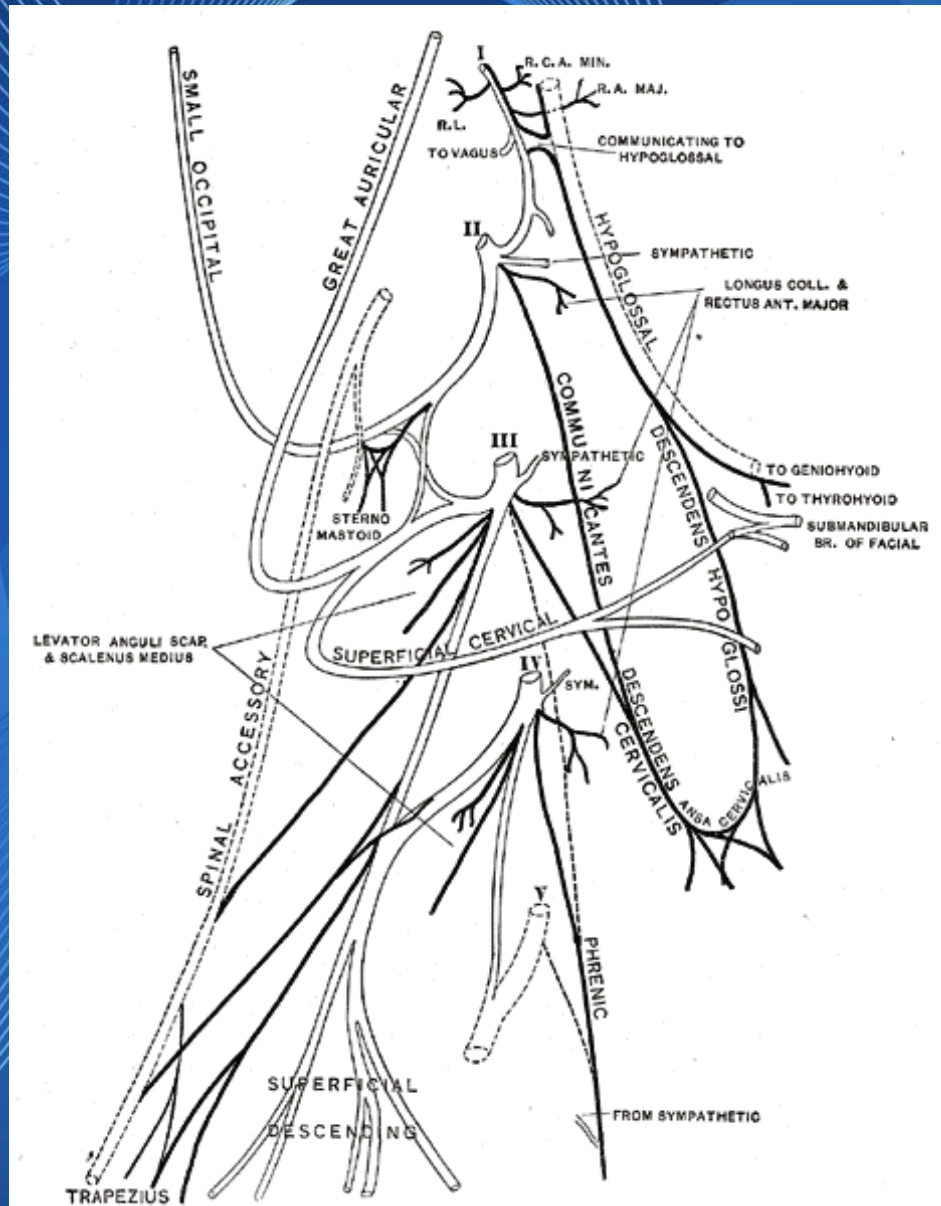


82 kV
3.00 mA
19.00 mGy/cm²
472.84 µGy
22/26
21.09.2009
10:09:44
Autowindow
R 52
16

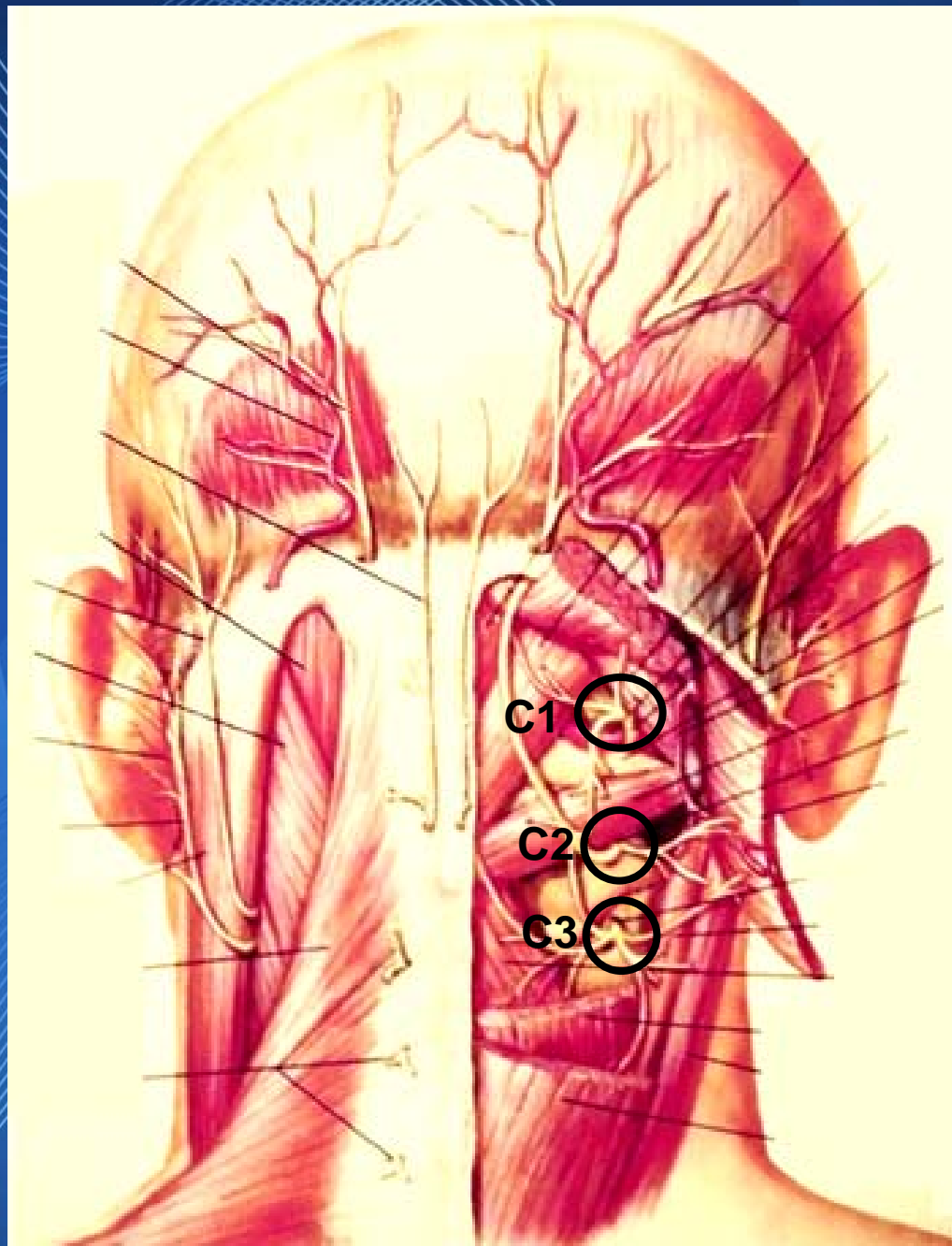
Cervicalgias y Cervicobraquialgias

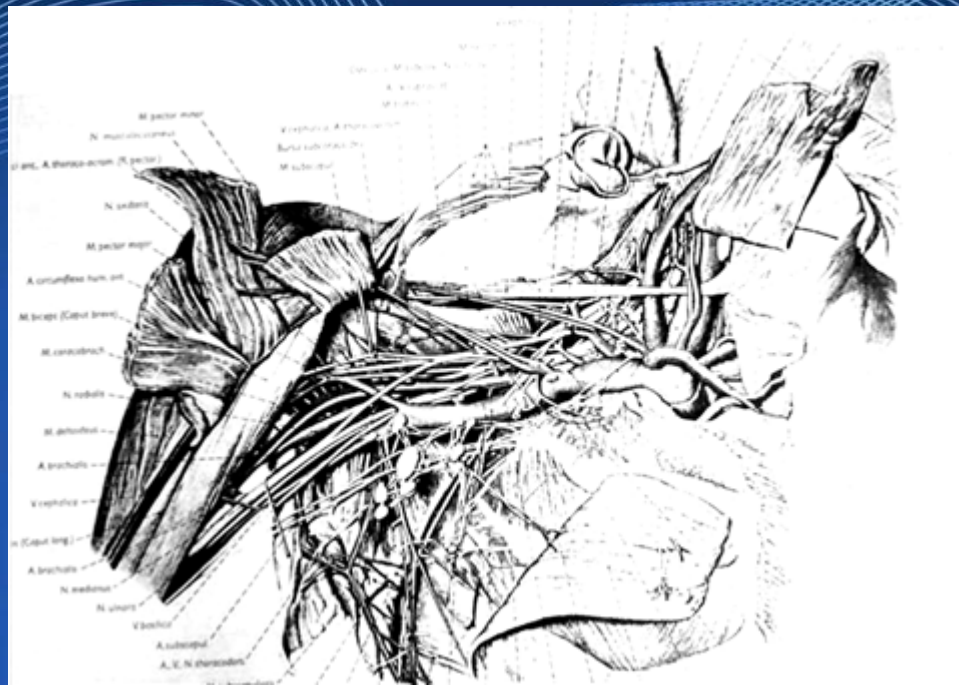

Plexo Cervical

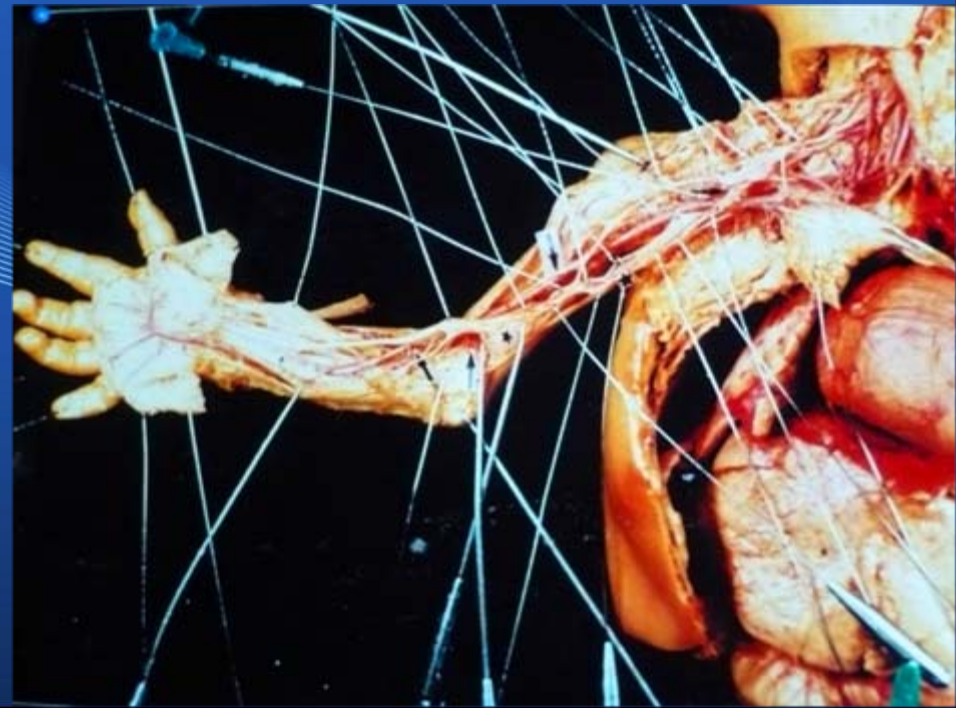


- *El plexo cervical tiene dos tipos de ramos, los superficiales que serán sensitivos, y los profundos que serán motores largos, que están organizados de la siguiente forma:*
- *Superficiales*
 - *Occipital menor: Se origina en C2, e inerva la piel de la parte posterior del cuero cabelludo.²*
 - *Auricular mayor: Se origina de C2 y C3, inerva la piel que va del ángulo de la mandíbula a la apófisis mastoides, la glándula parótida y la piel que la cubre, y la cara posterior del pabellón auricular.*
 - *Cervical transverso: Se origina de C2 y C3, inerva la piel del triángulo anterior del cuello.*
 - *Supraclavicular: Se origina de C3 y C4, inervan la piel del hombro.*
- *Profundos*
 - *Asa cervical: Se origina por ramos de C1, C2 y C3, inerva los músculos infrahioideos del triángulo anterior del cuello.*
 - *Frénico: Se origina principalmente de C4 pero tiene ramos de C3 y C5, da la totalidad de la inervación motora del diafragma y la sensibilidad de su porción central.¹*

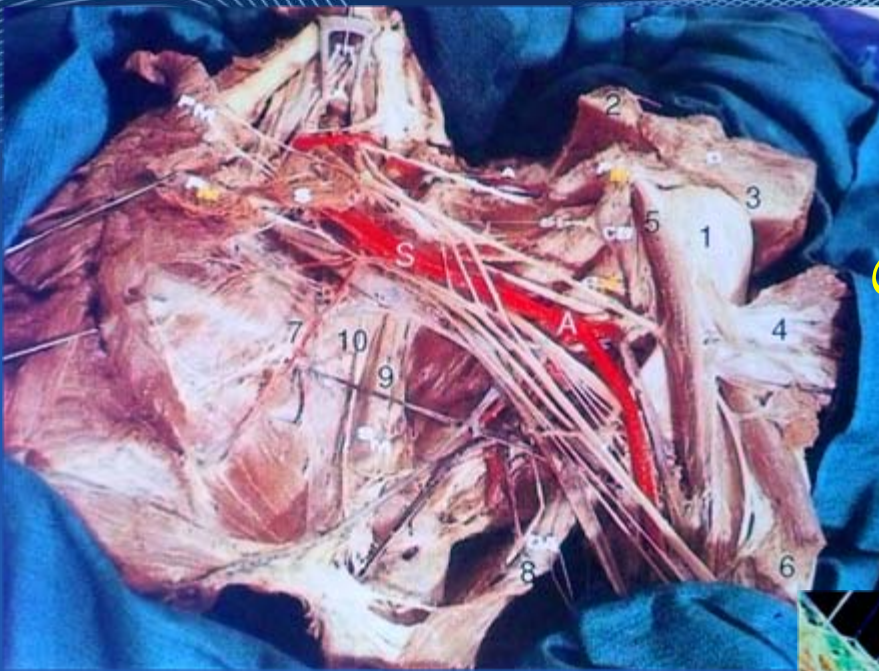




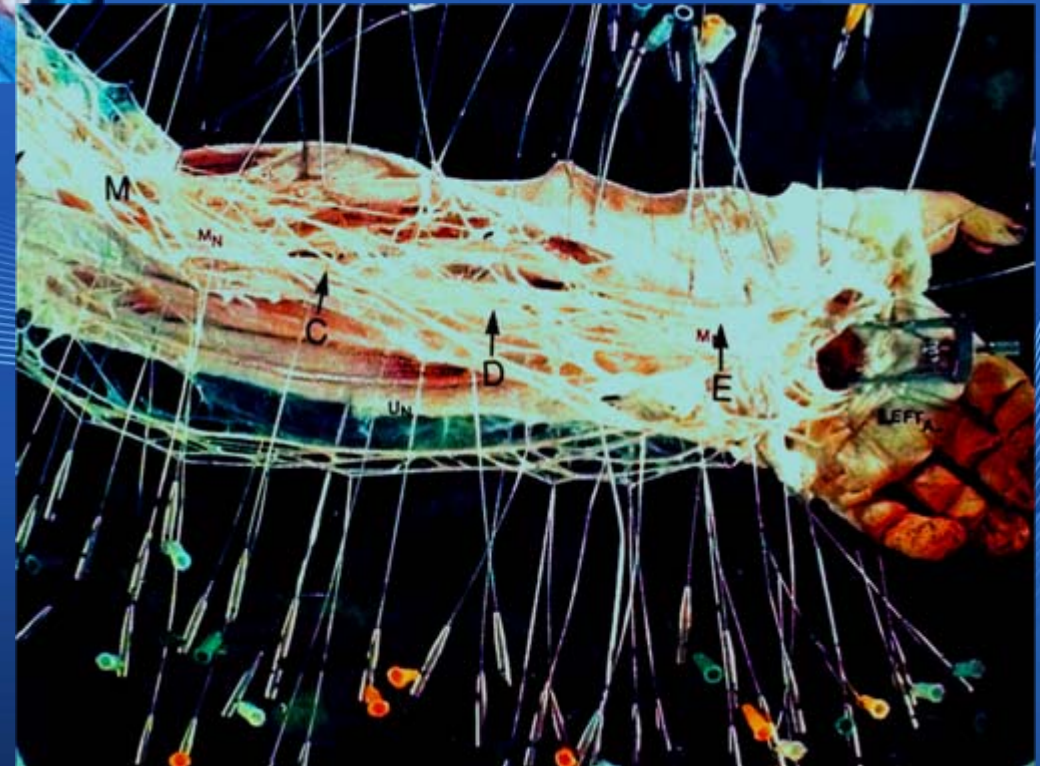C4 – T1



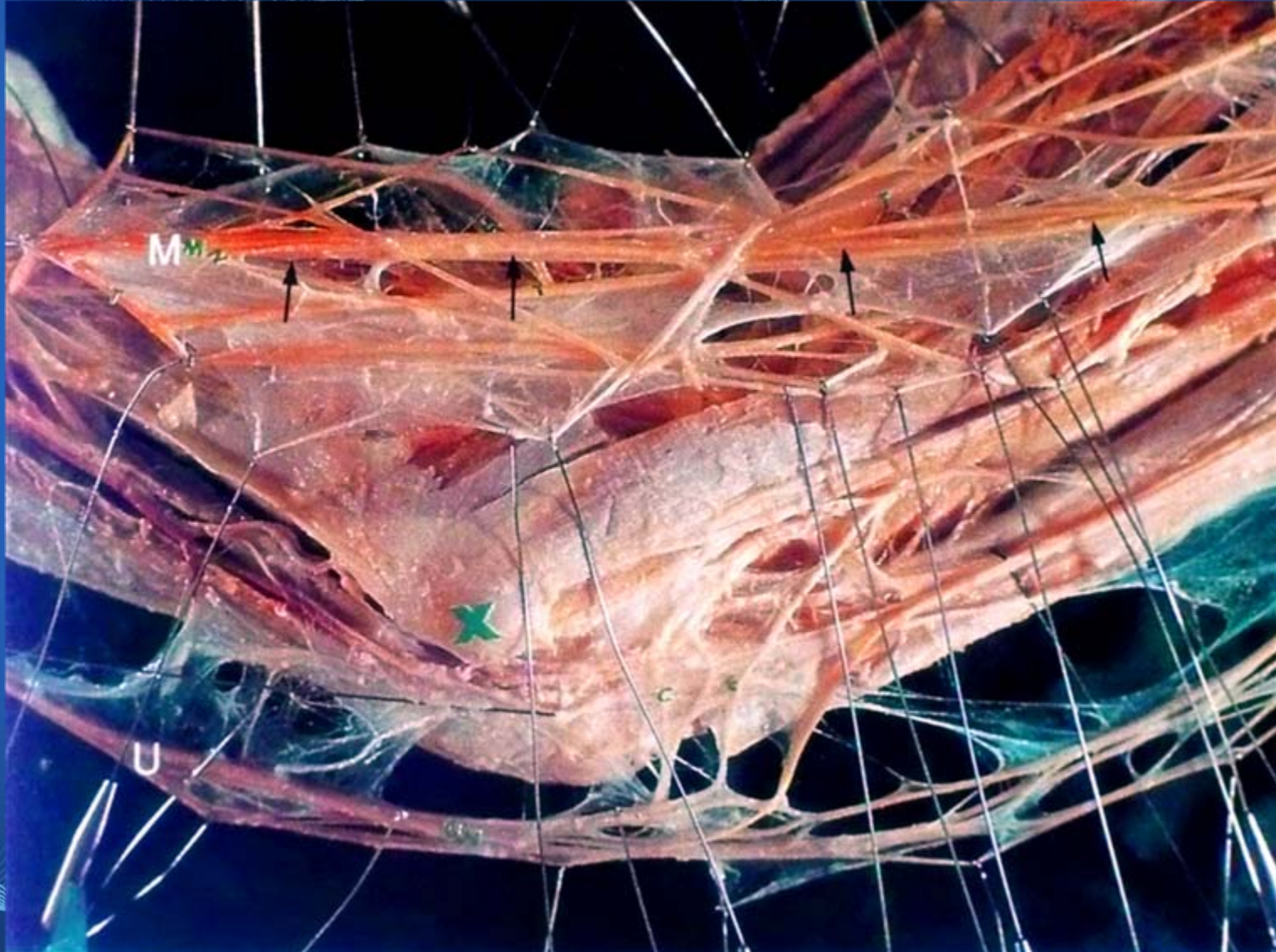*Troncos
Secundarios
Plexo Braquial*



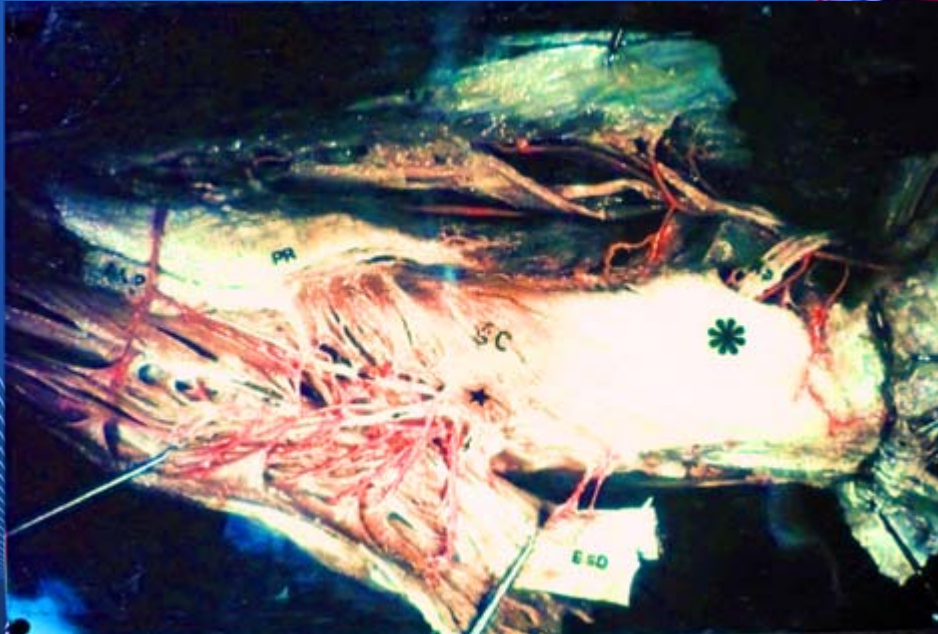
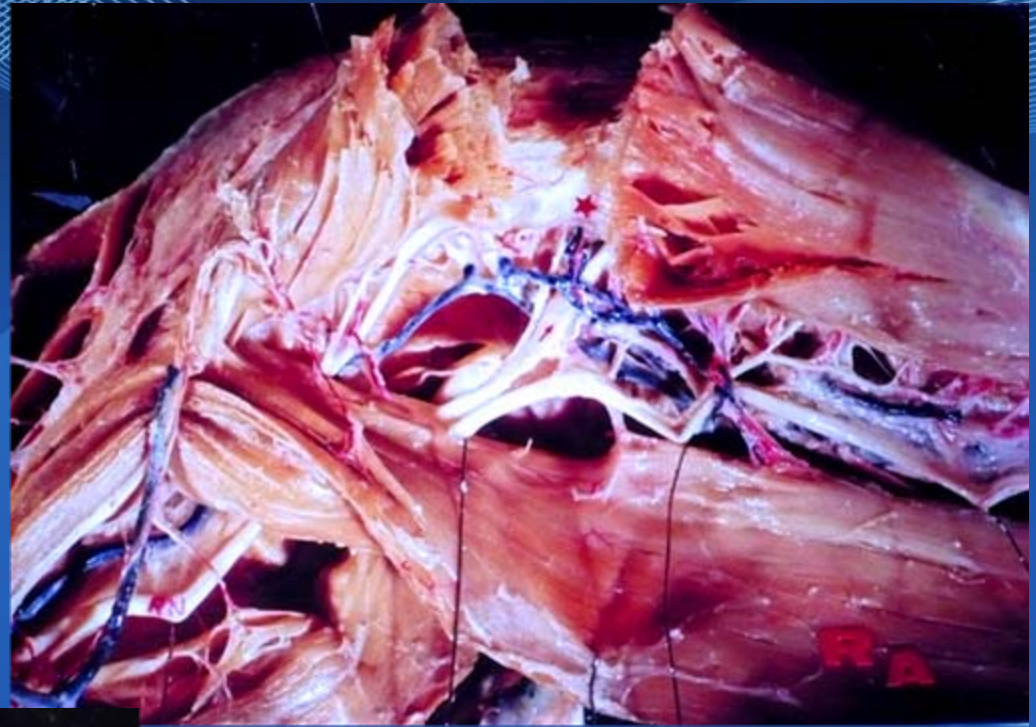
*Nervios
Terminales del
Plexo Braquial*



“Fasciculación nervios mediano y cubital”

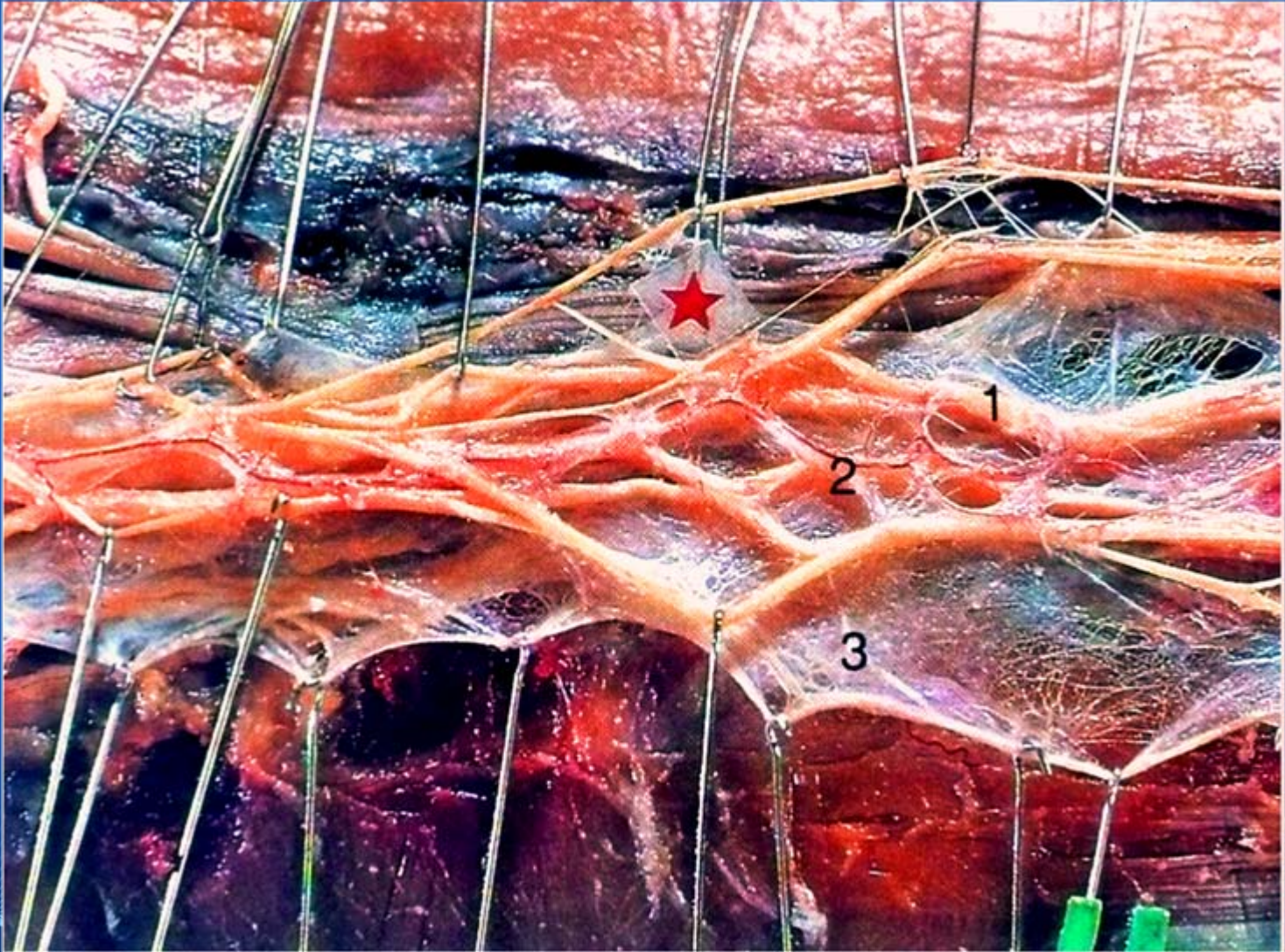

Nervio Radial en Brazo y Codo



** Arcada de Frohse*

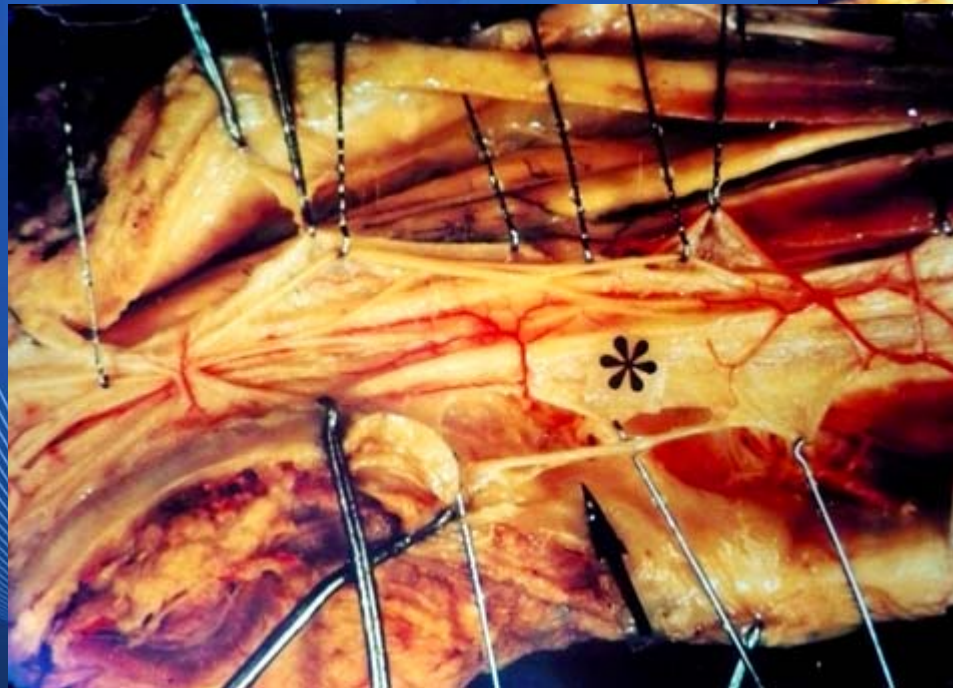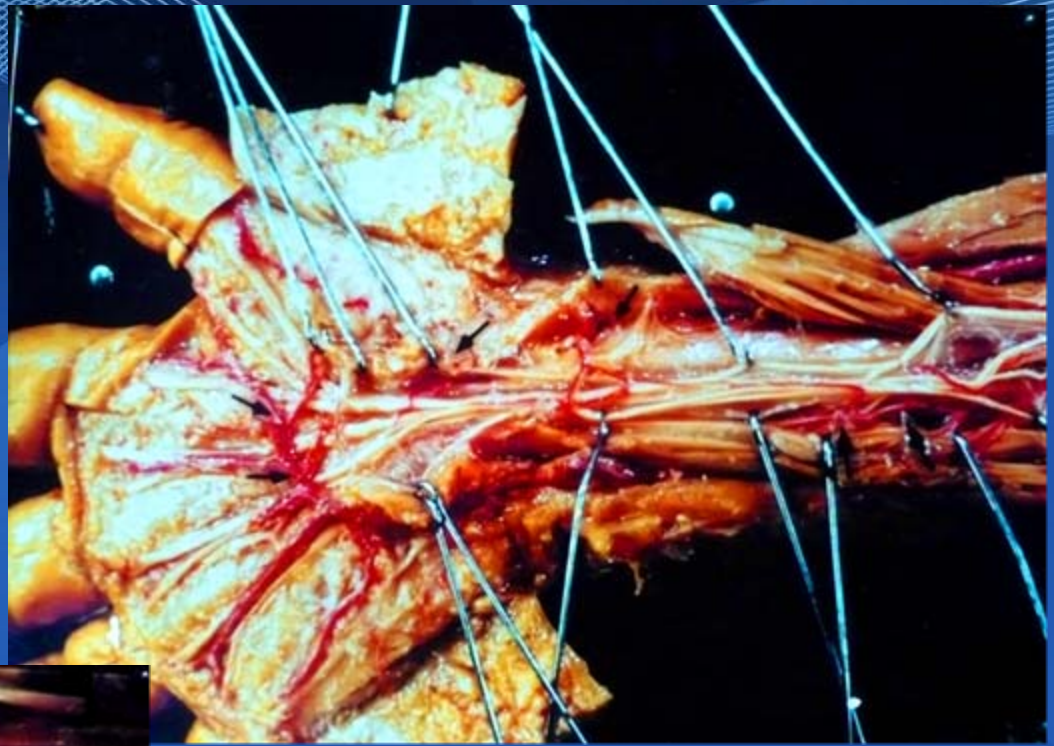
Nervio Mediano en 1/3 medio del Brazo, Fasciculado



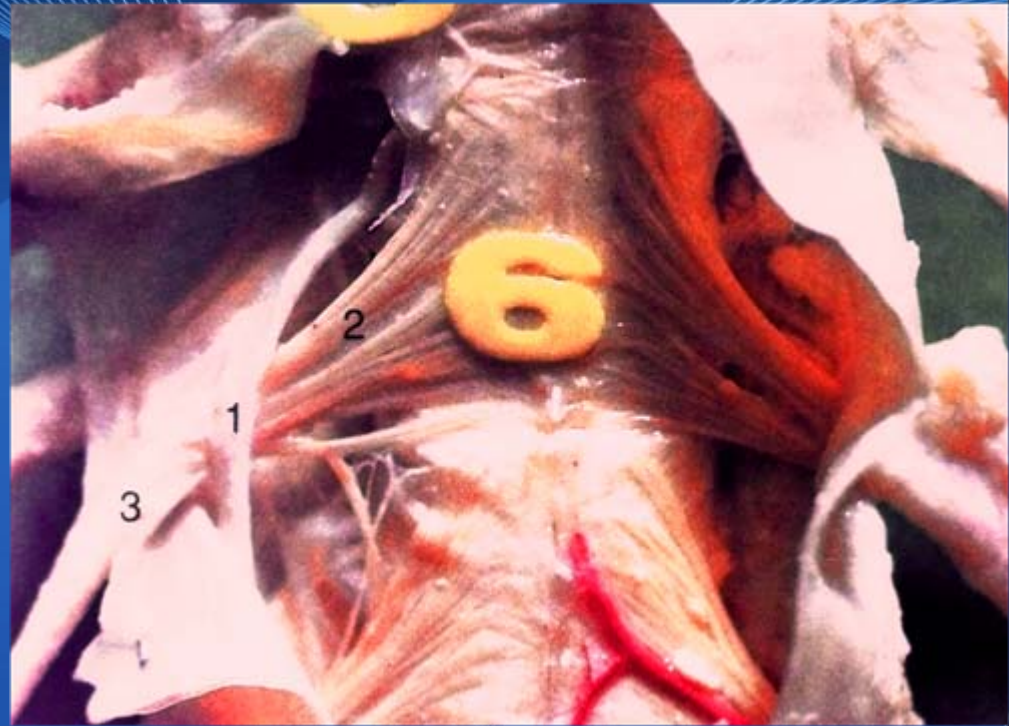Nervio Mediano en Antebrazo, Muñeca y Mano



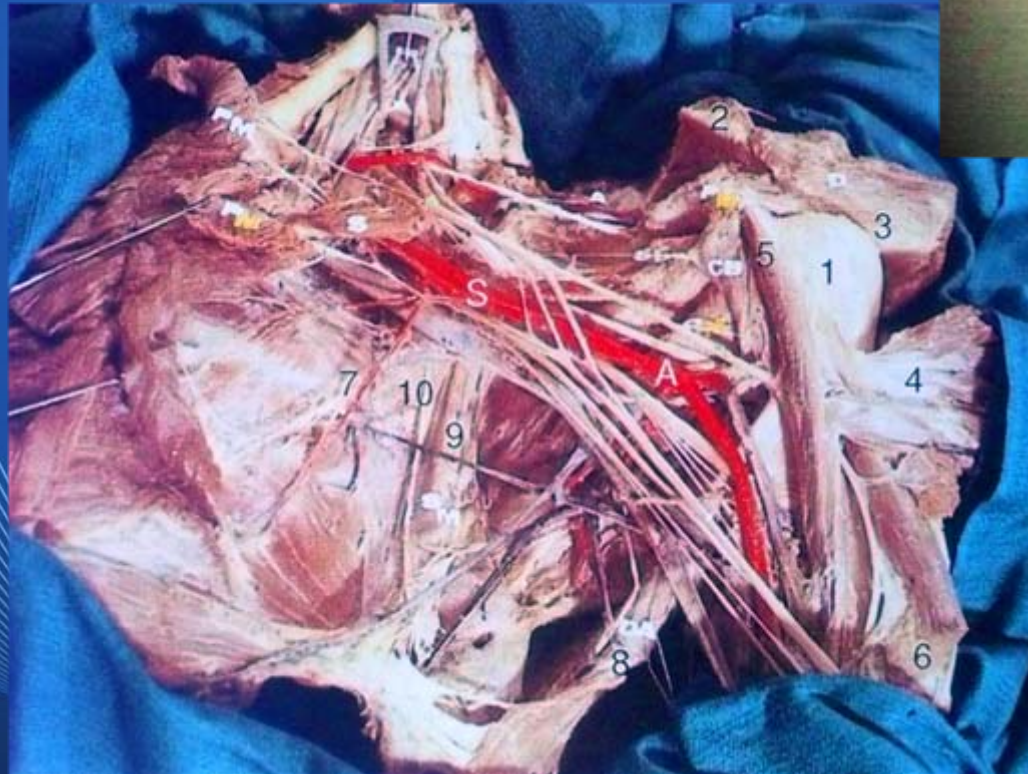
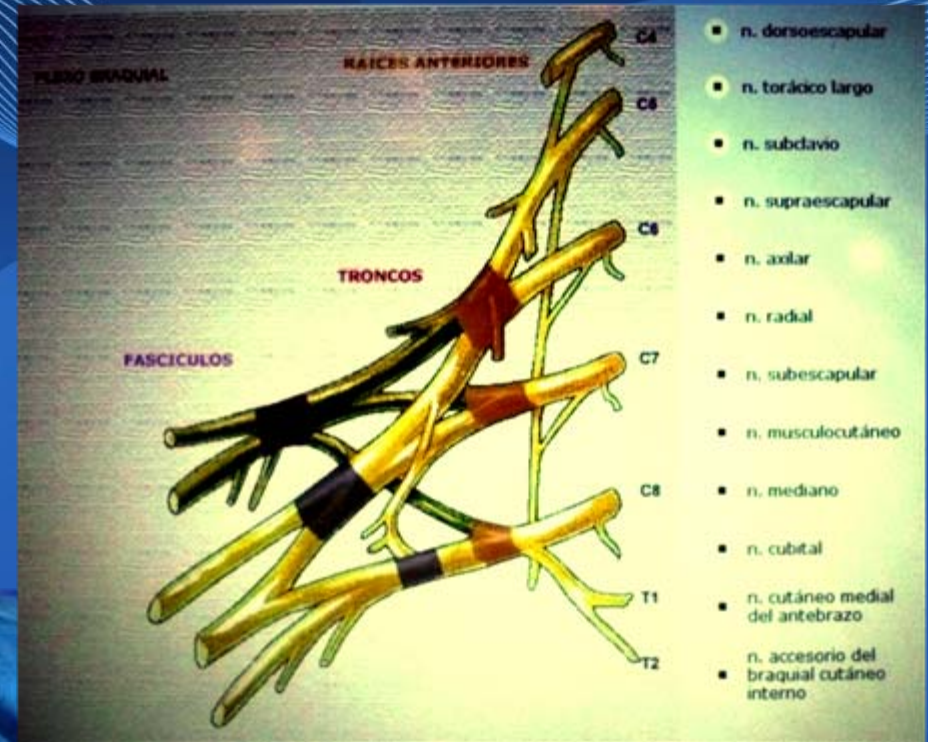
Síndrome del Túnel Carpiano



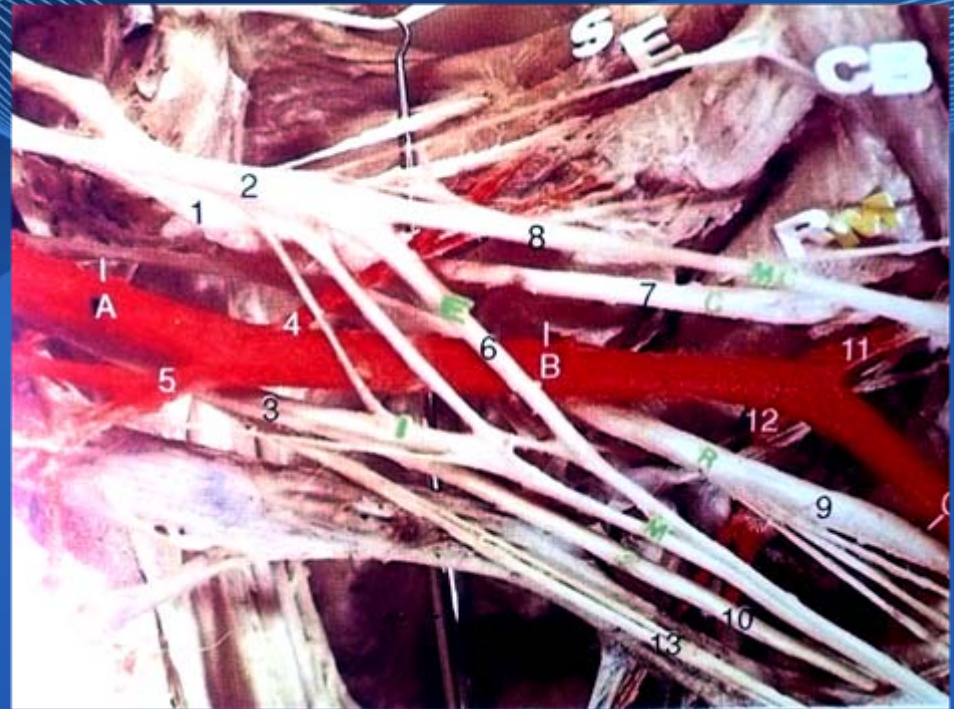
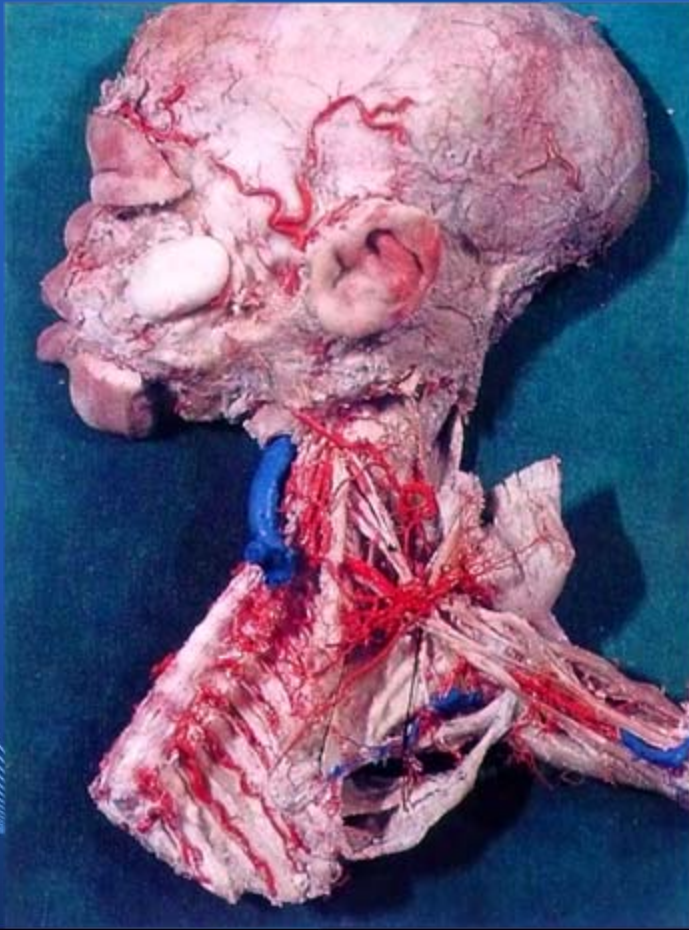
Fibras Preganglionares dentro del canal Neural



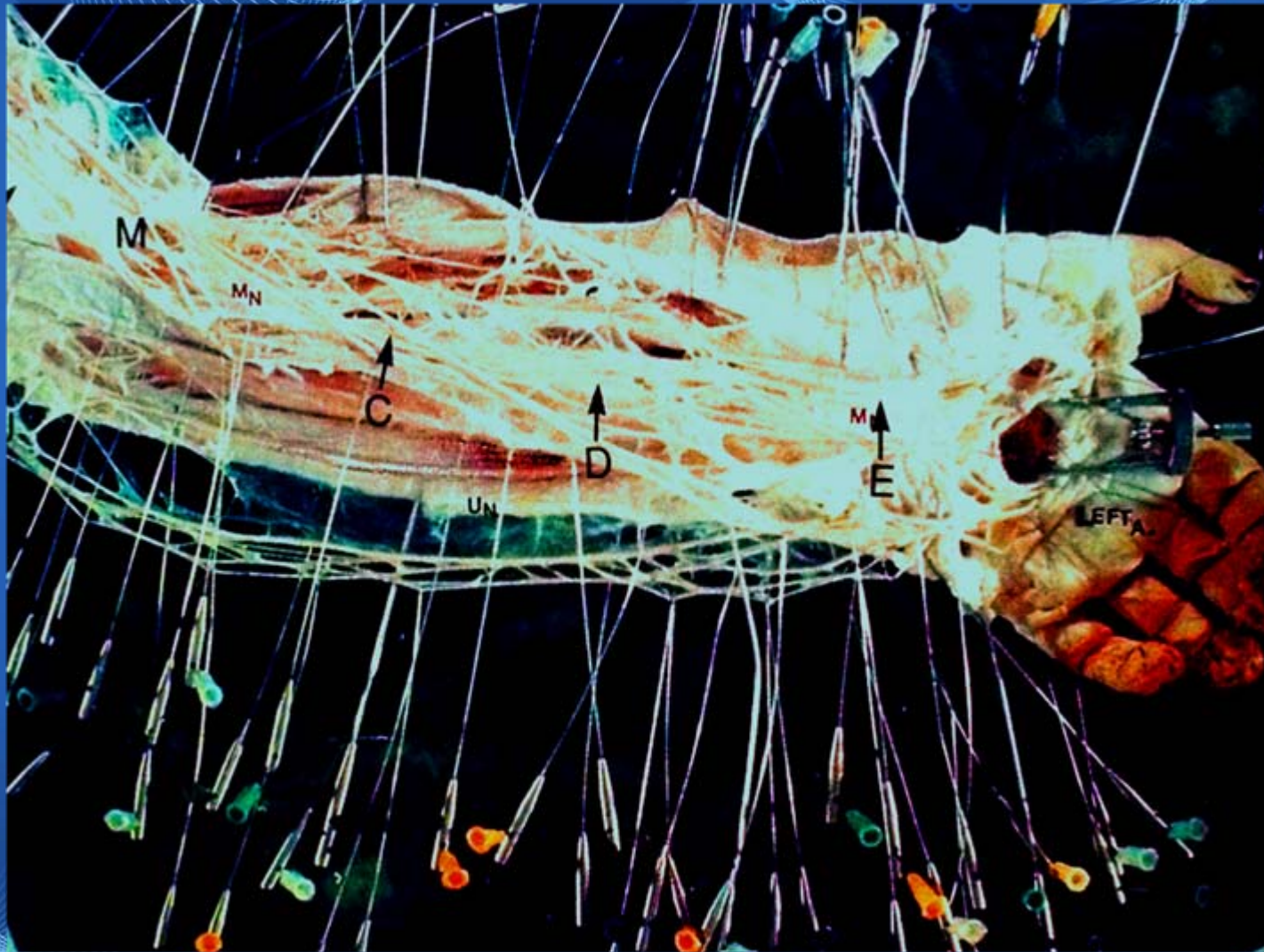
Troncos Primarios



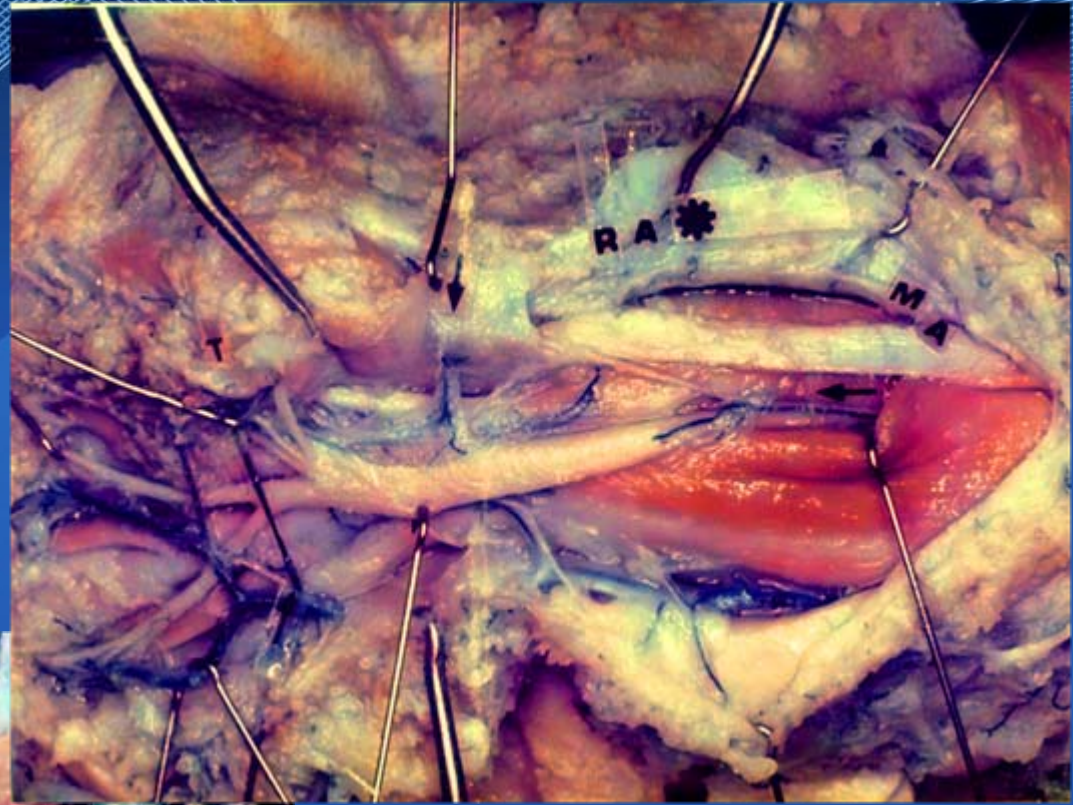Troncos Secundarios y Nervios Terminales



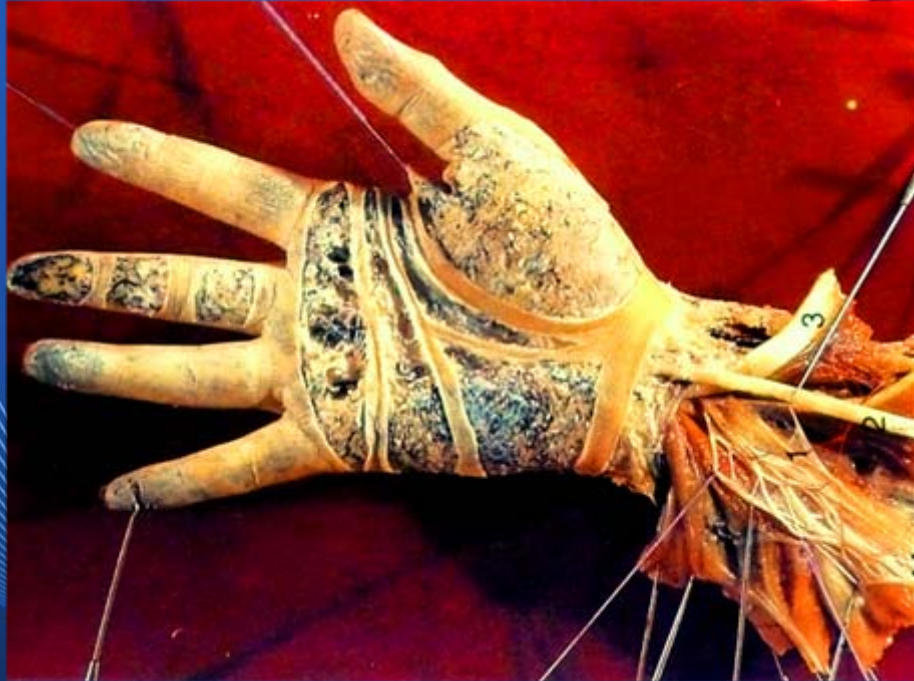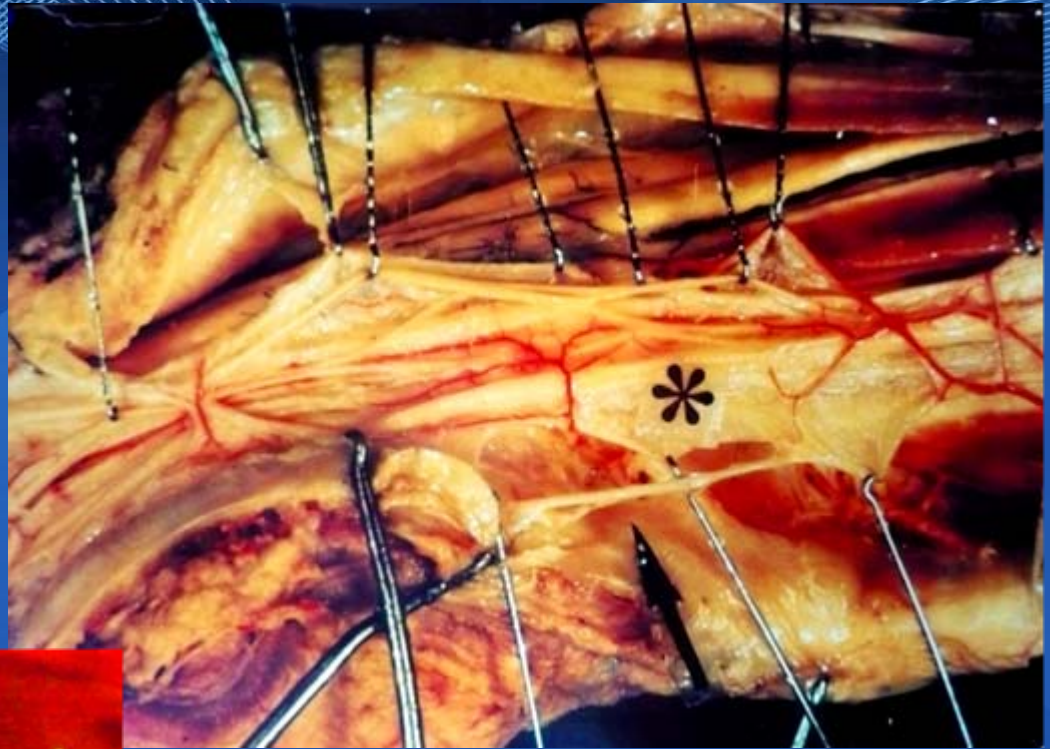Nervios Terminales



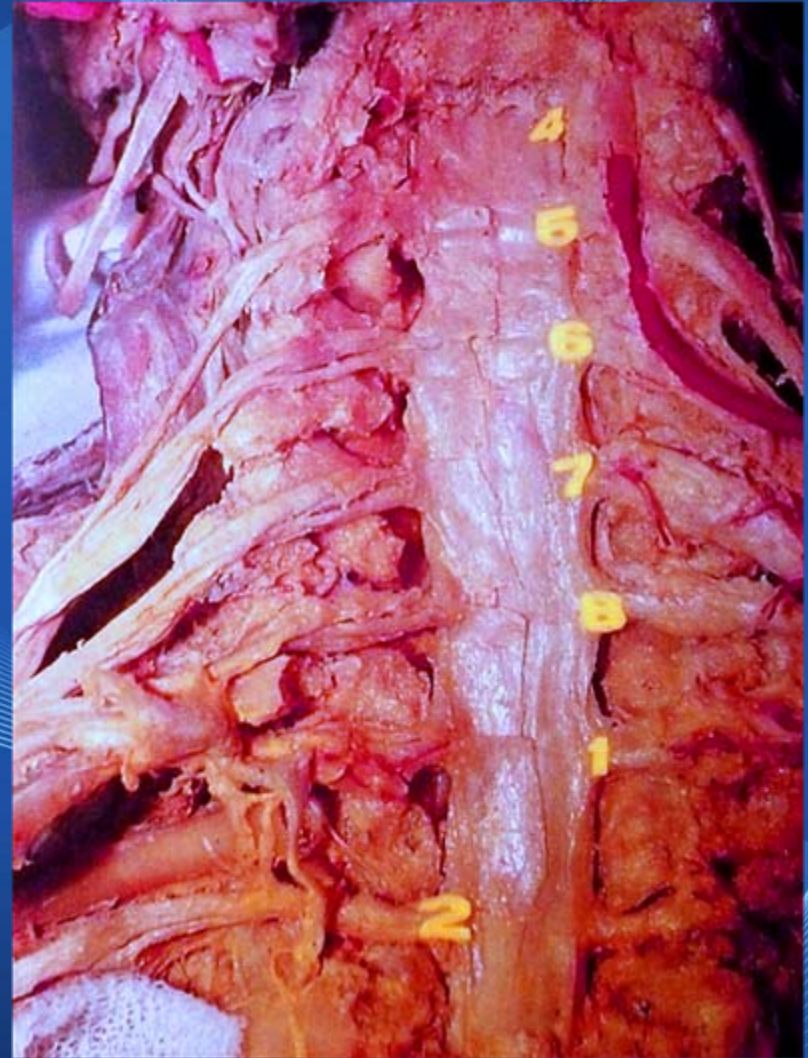
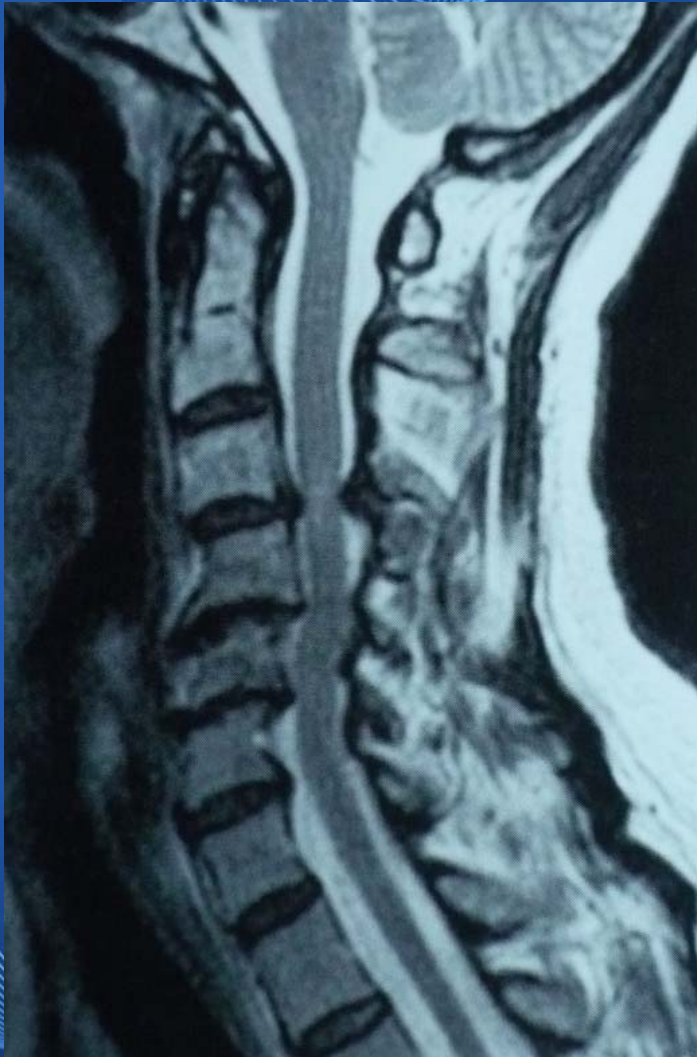Ligamento Anular del Carpo



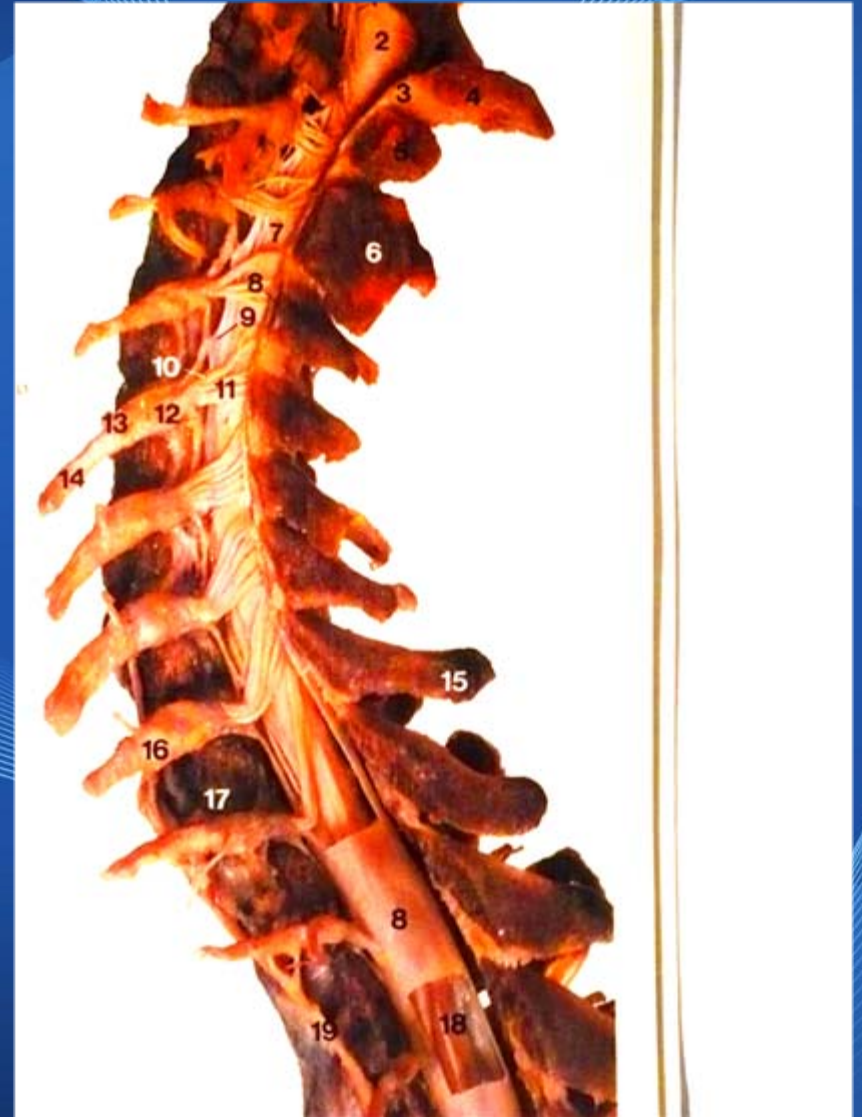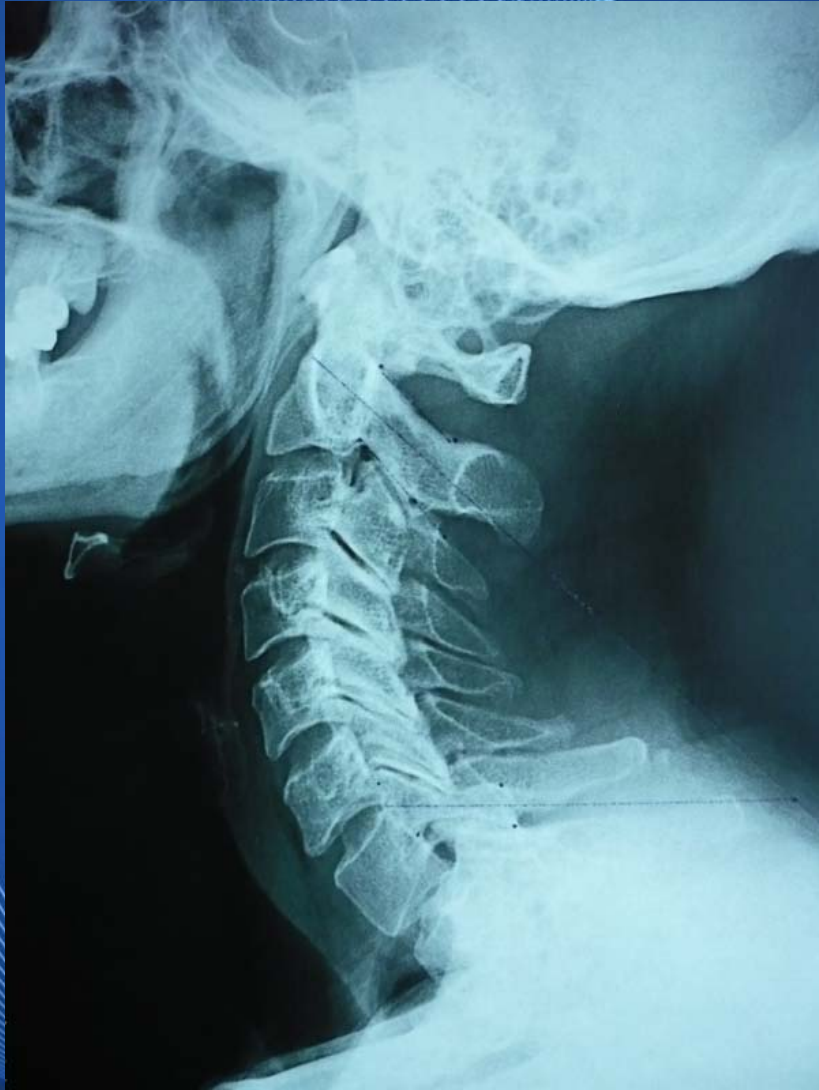*Circulación epi
y perineural*



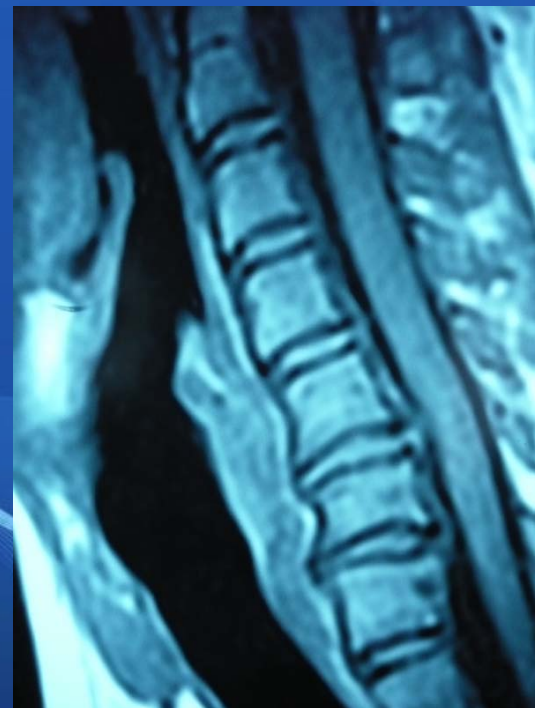
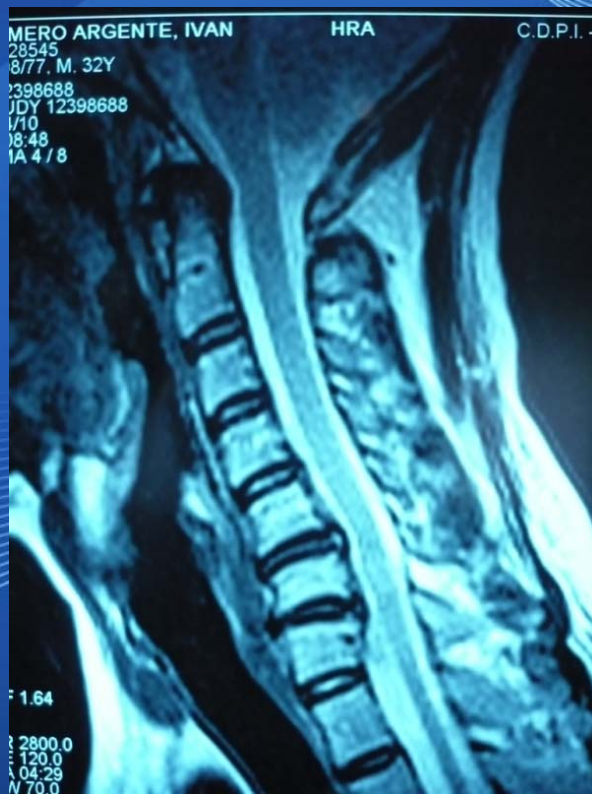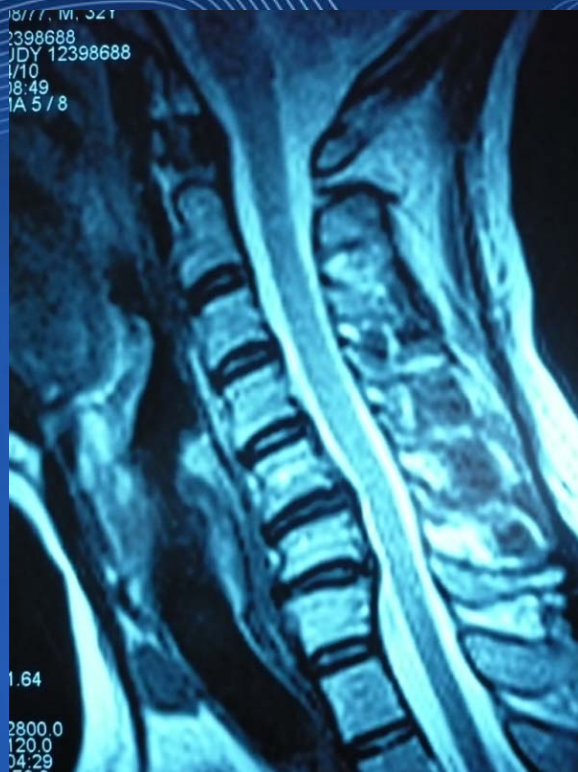
Cervico-Braquialgias



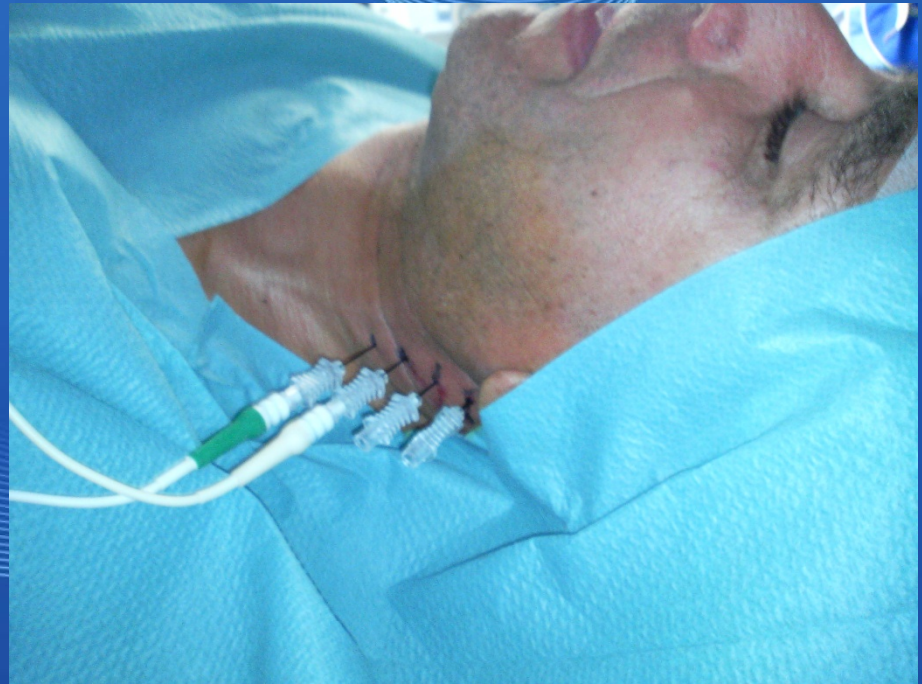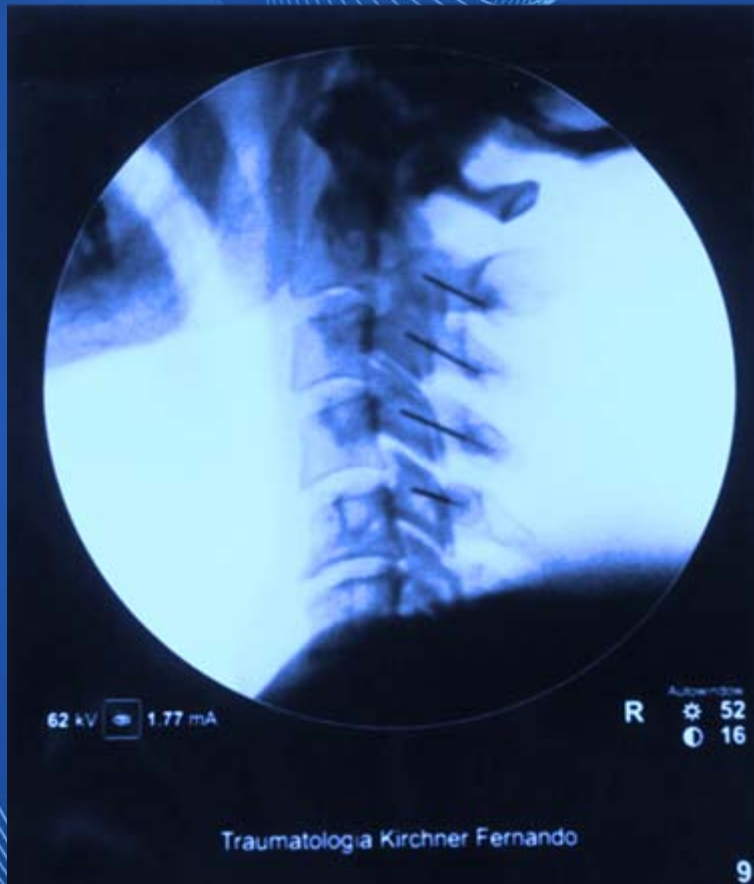Cervicalgia

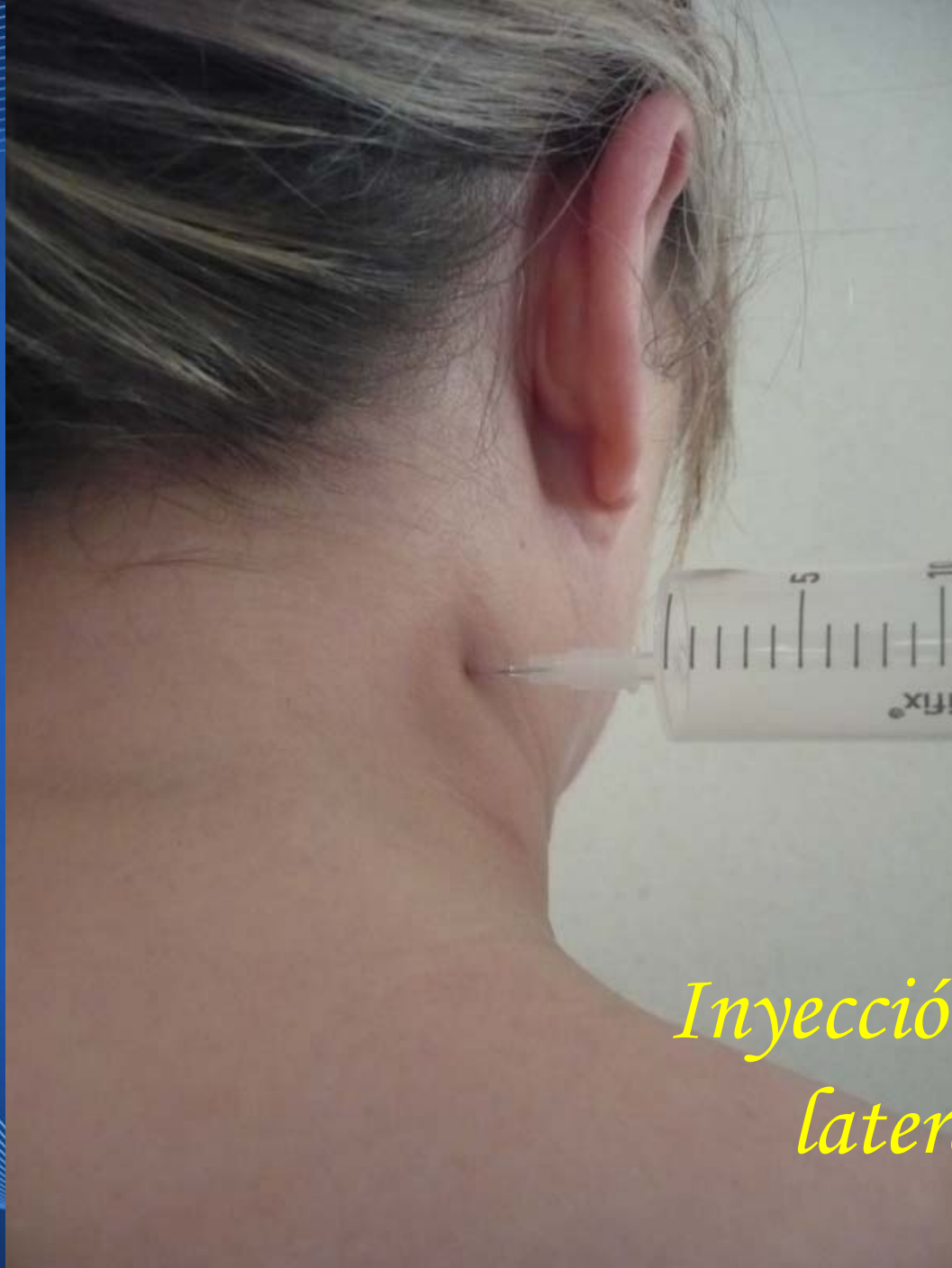

Columna Cervical Rectificada



Neurorrizolisis





*Inyección Paravertebral
lateral Profunda*

“Inyección Paravertebral lateral Profunda” de Columna Cervical

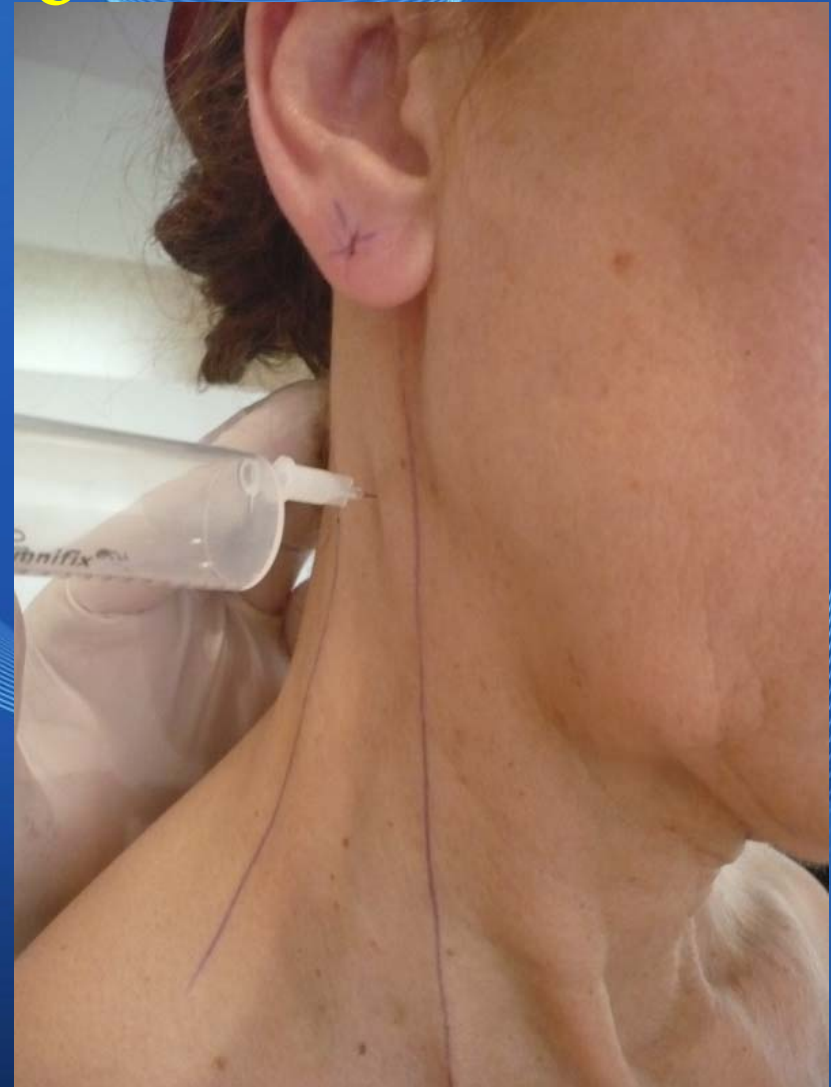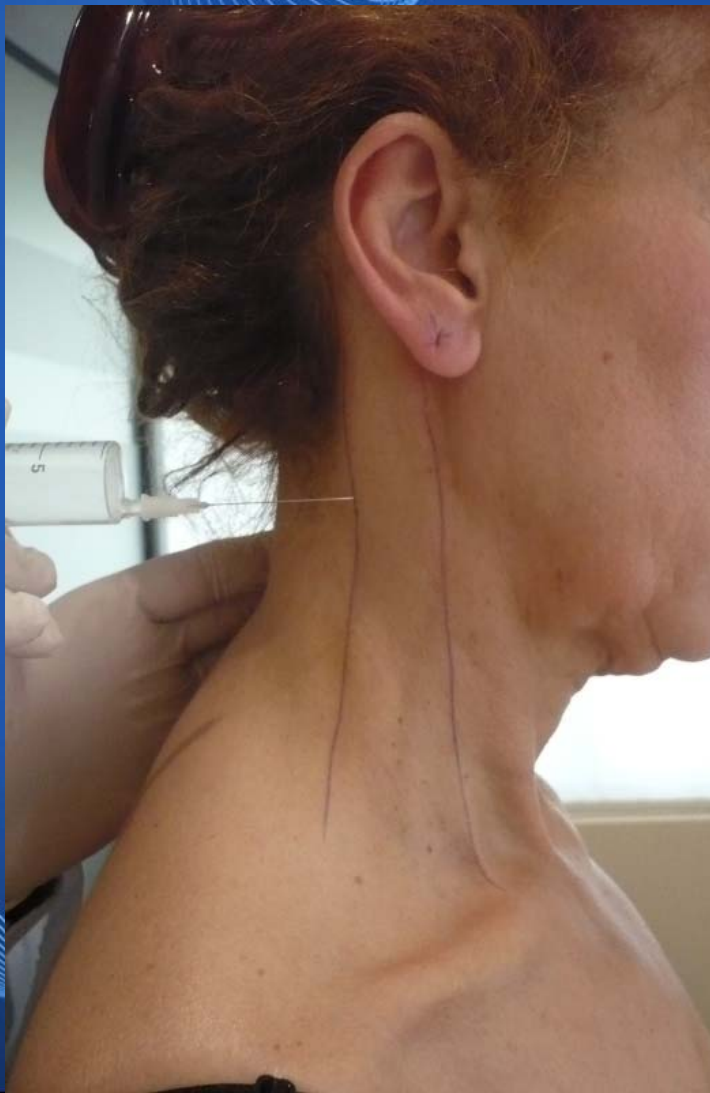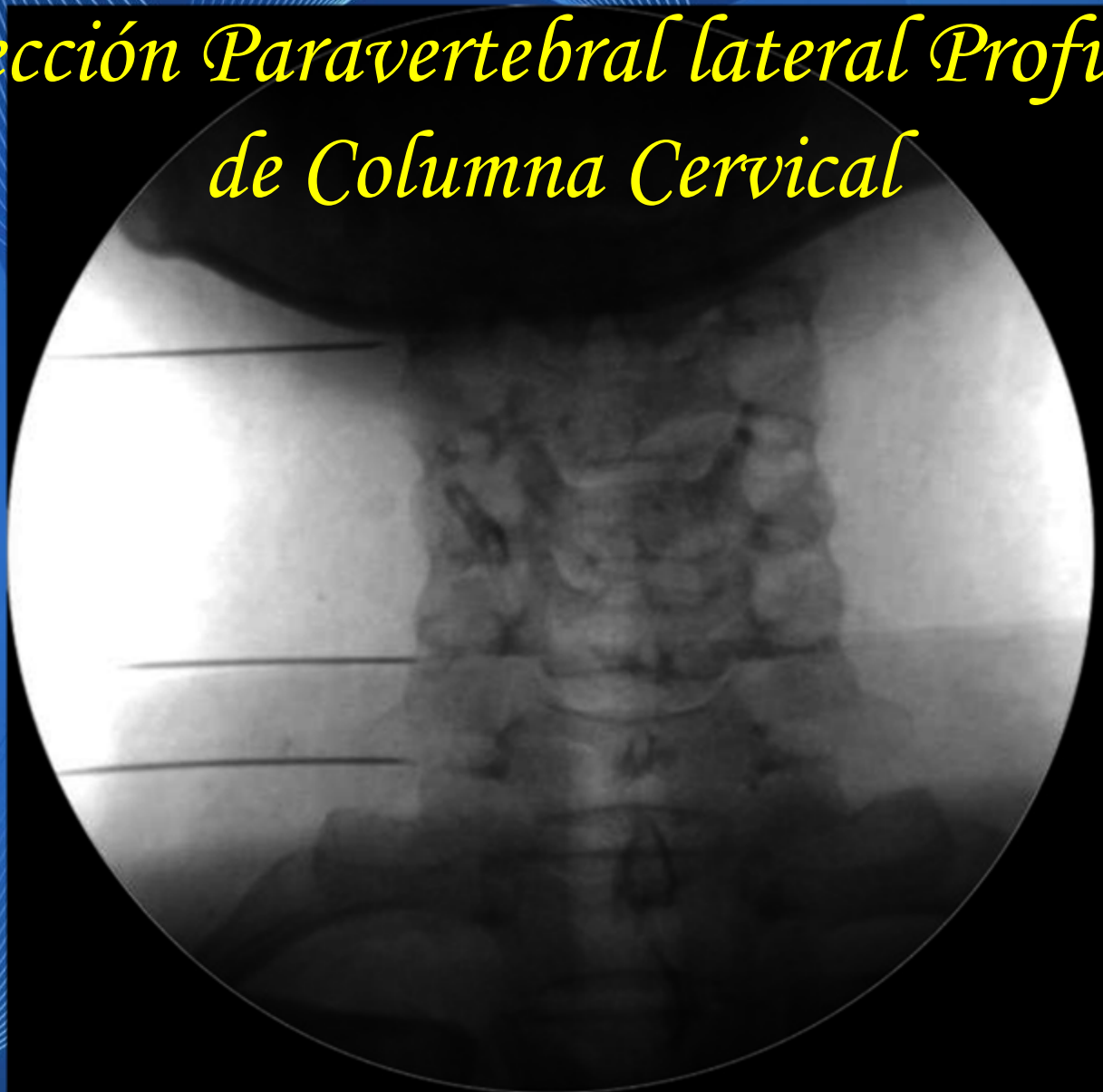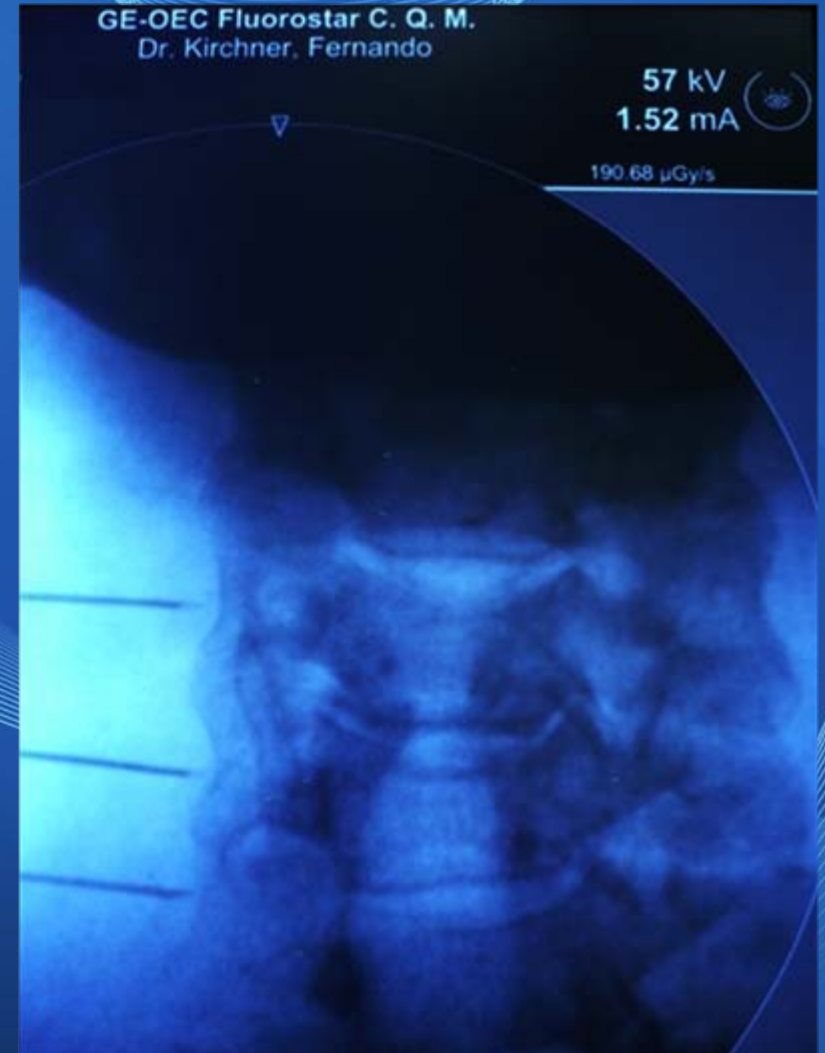


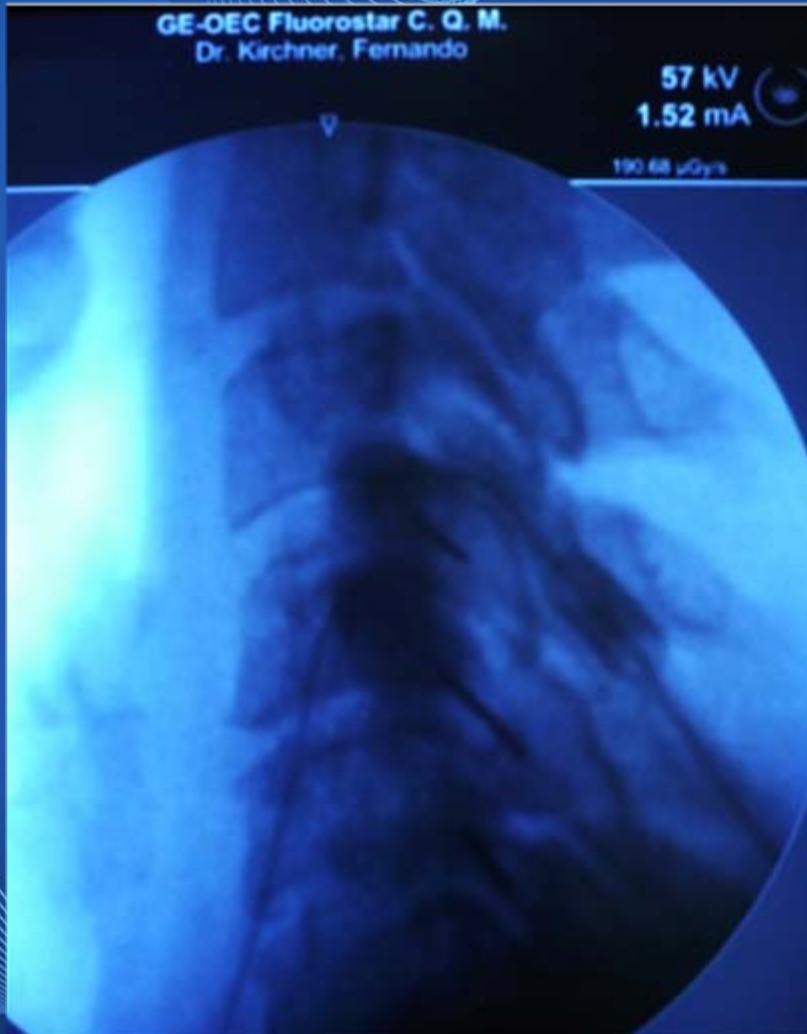Imagen Rx Frente

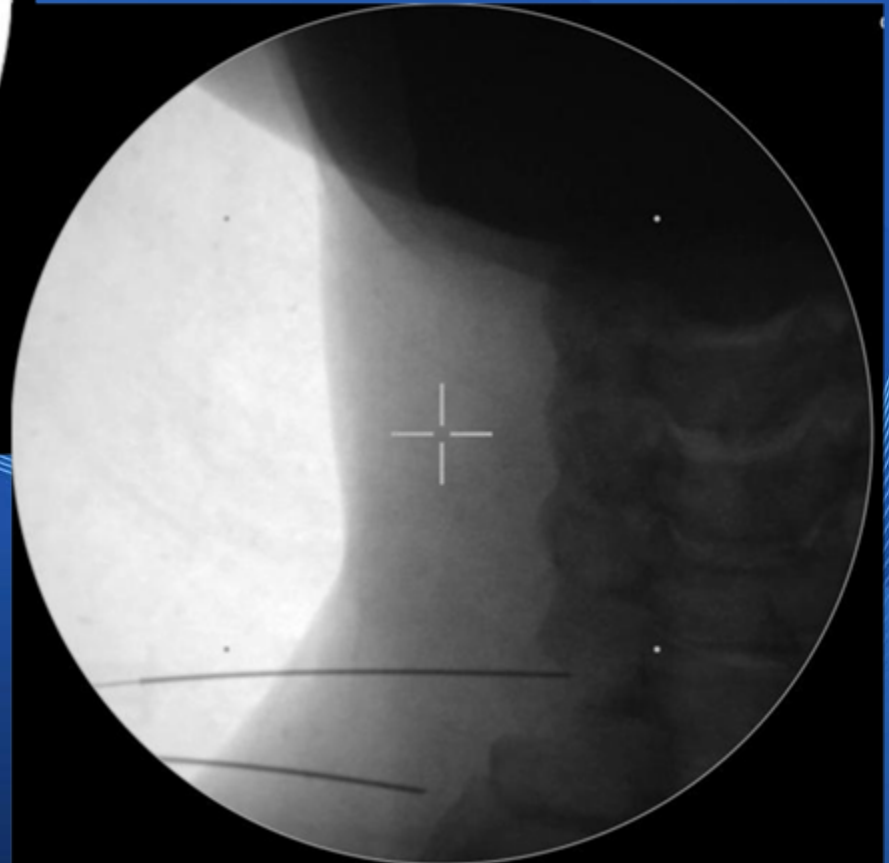
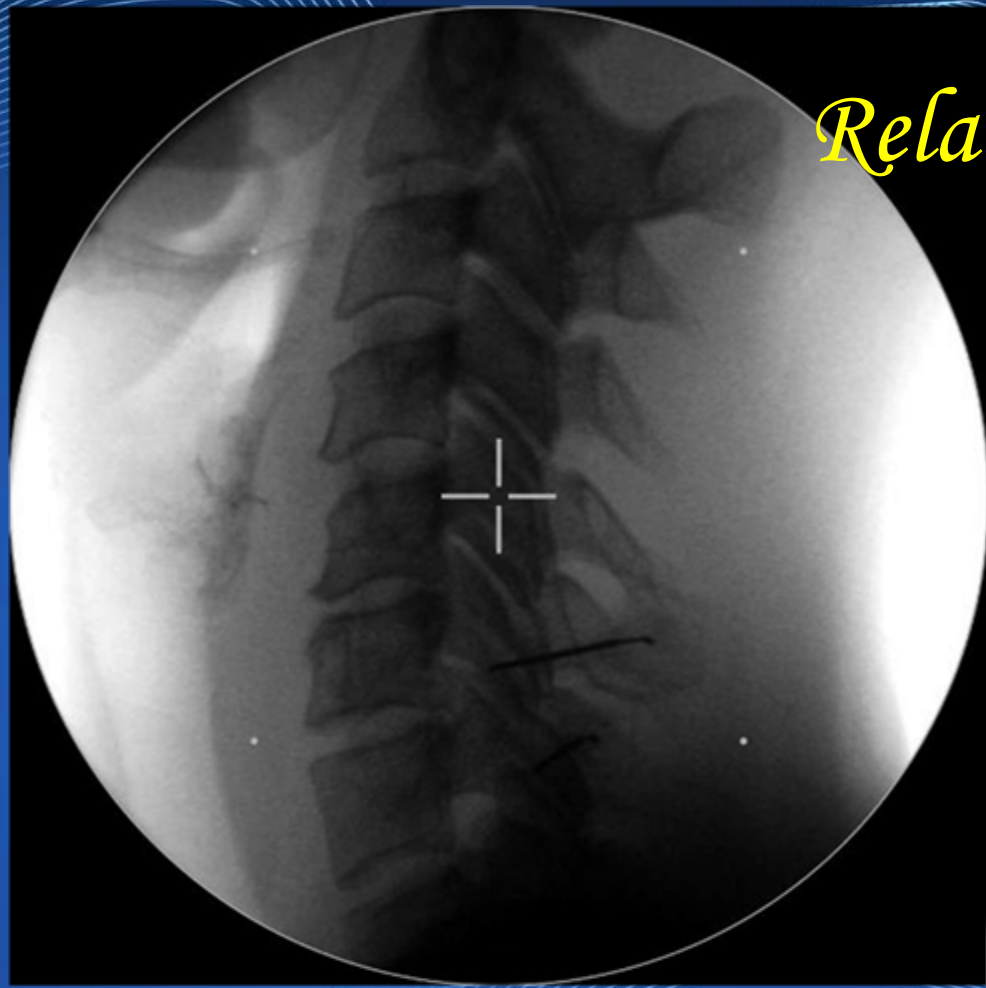
*“Inyección Paravertebral lateral Profunda”
de Columna Cervical*

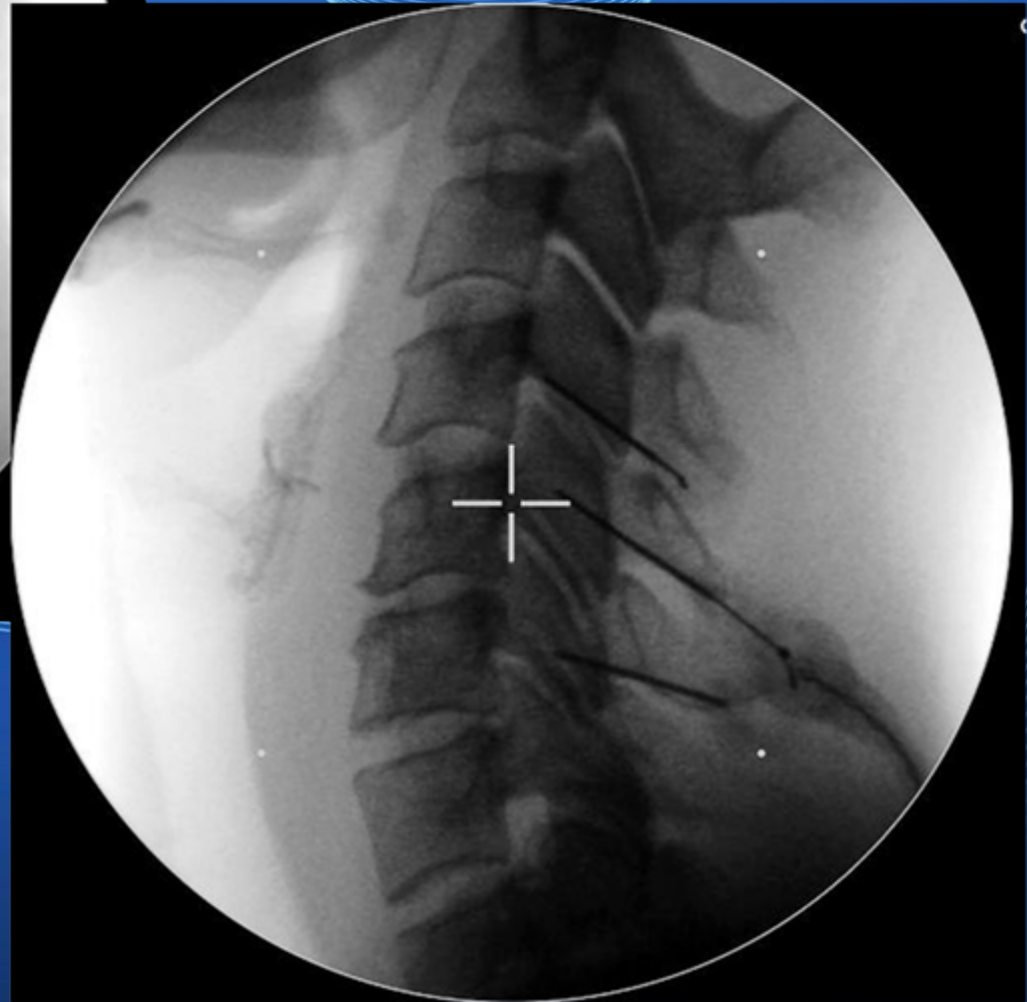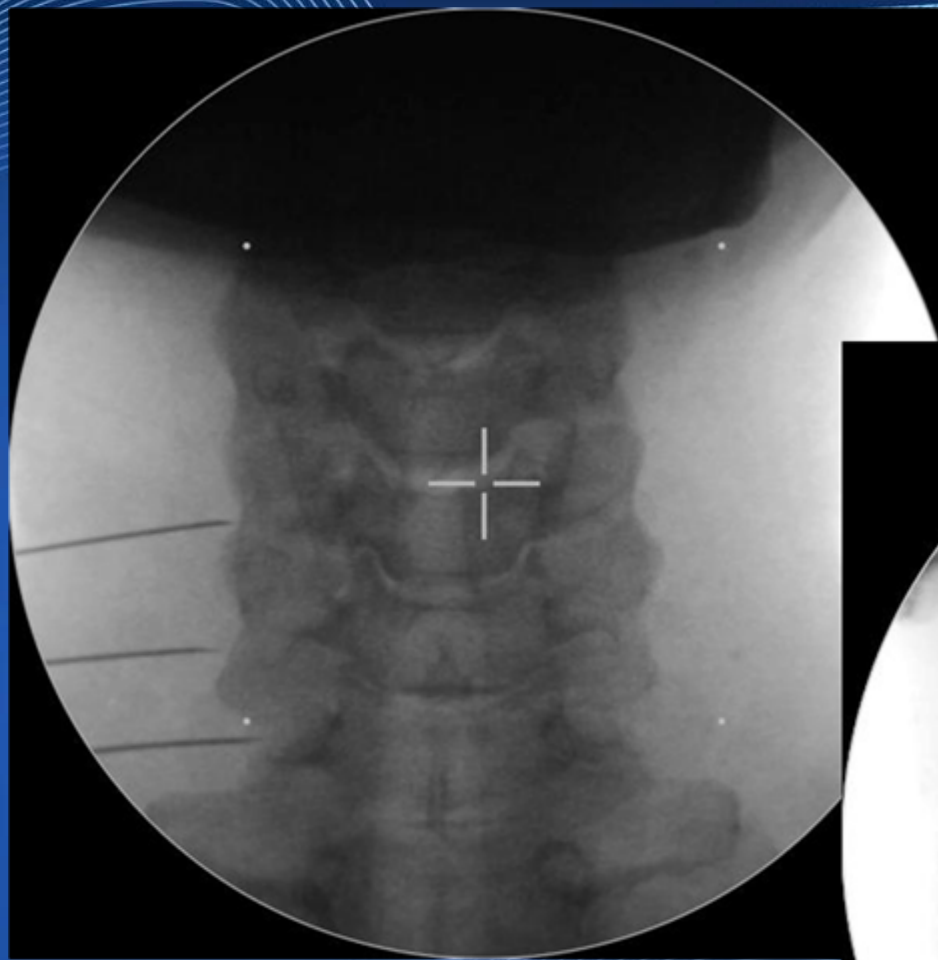


Combinados



Relación Anatómica de Piel con Profundidad

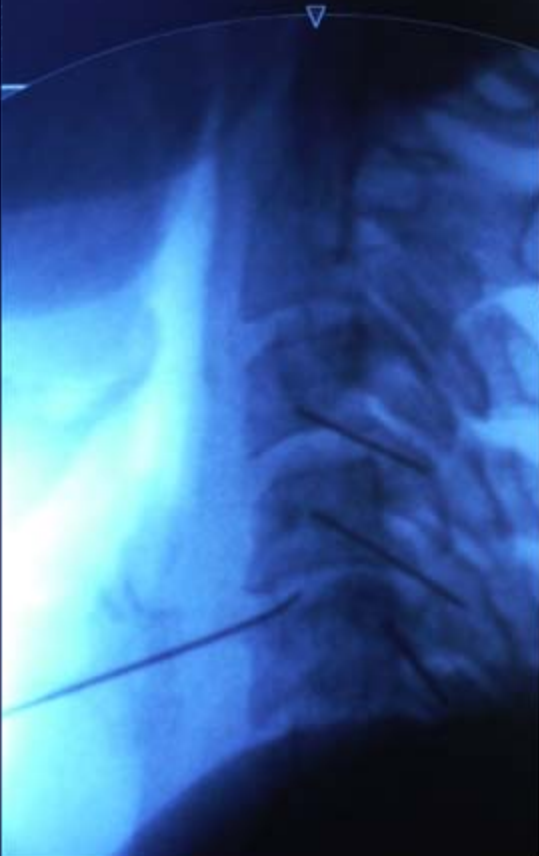



GE-OEC Fluorostar C. Q. M.
Dr. Kirchner, Fernando

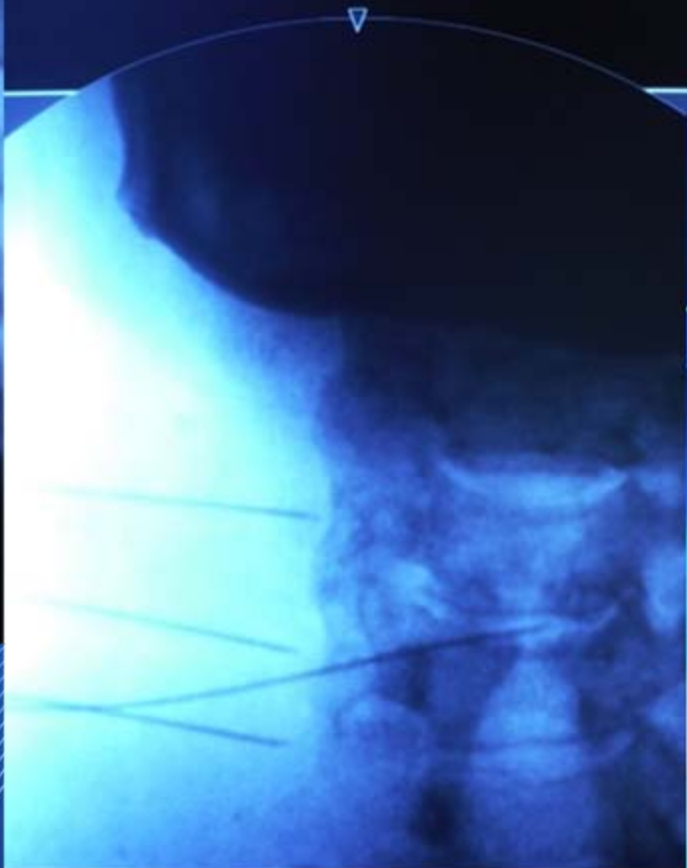
Beatriz

5
1.5
190.68

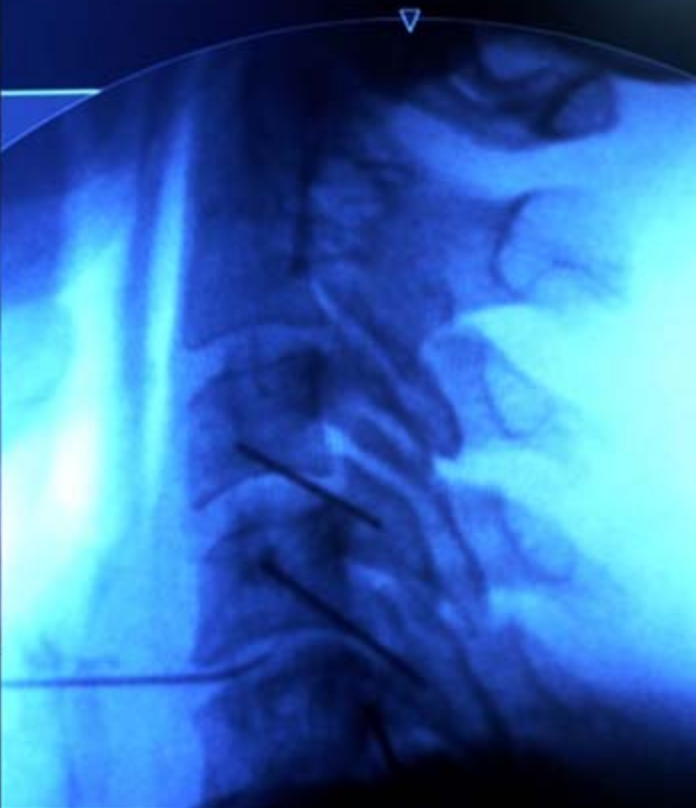


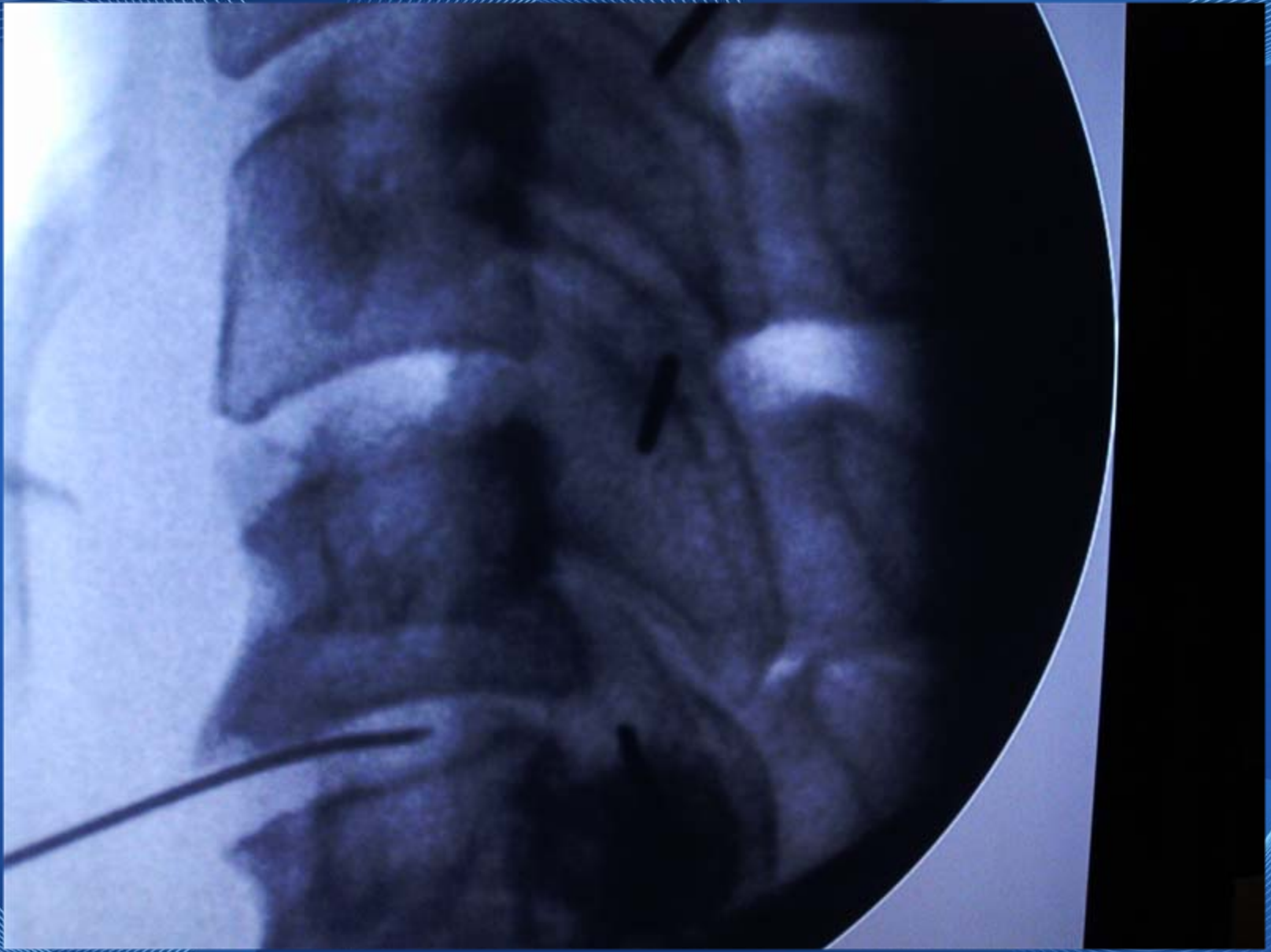GE-OEC Fluorostar C. Q. M.
Dr. Kirchner, Fernando

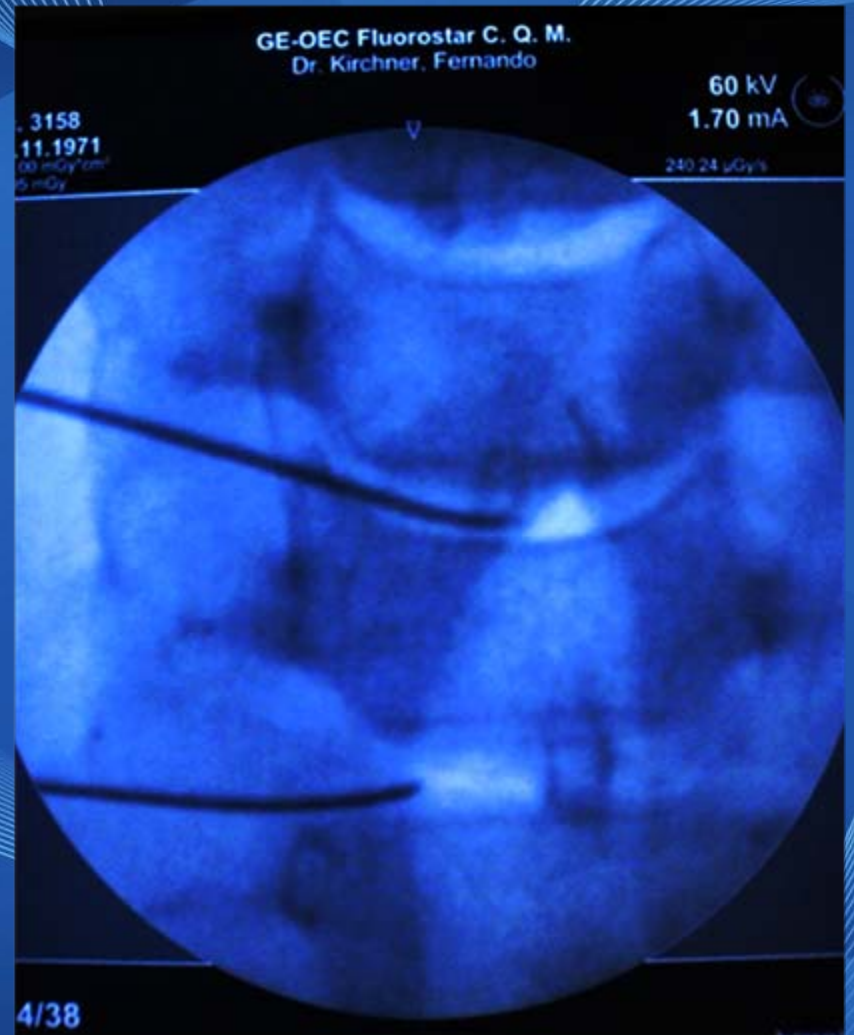
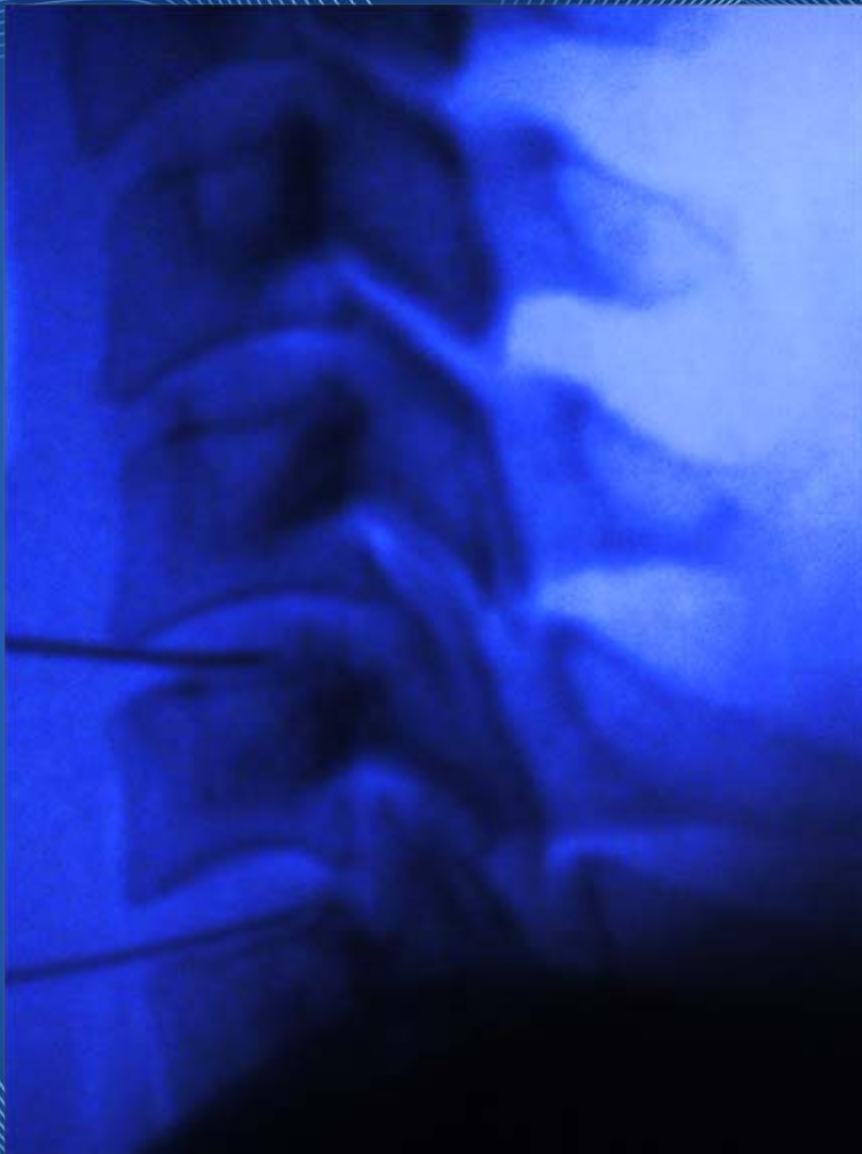190

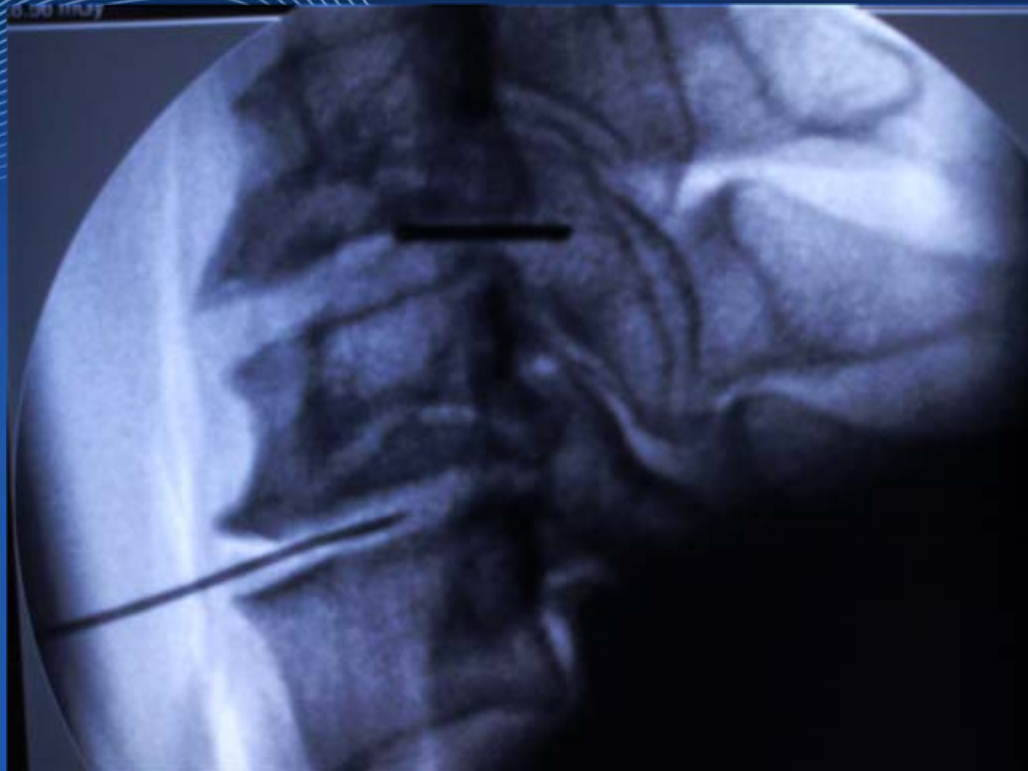

GE-OEC Fluorostar C. Q. M.
Dr. Kirchner, Fernando

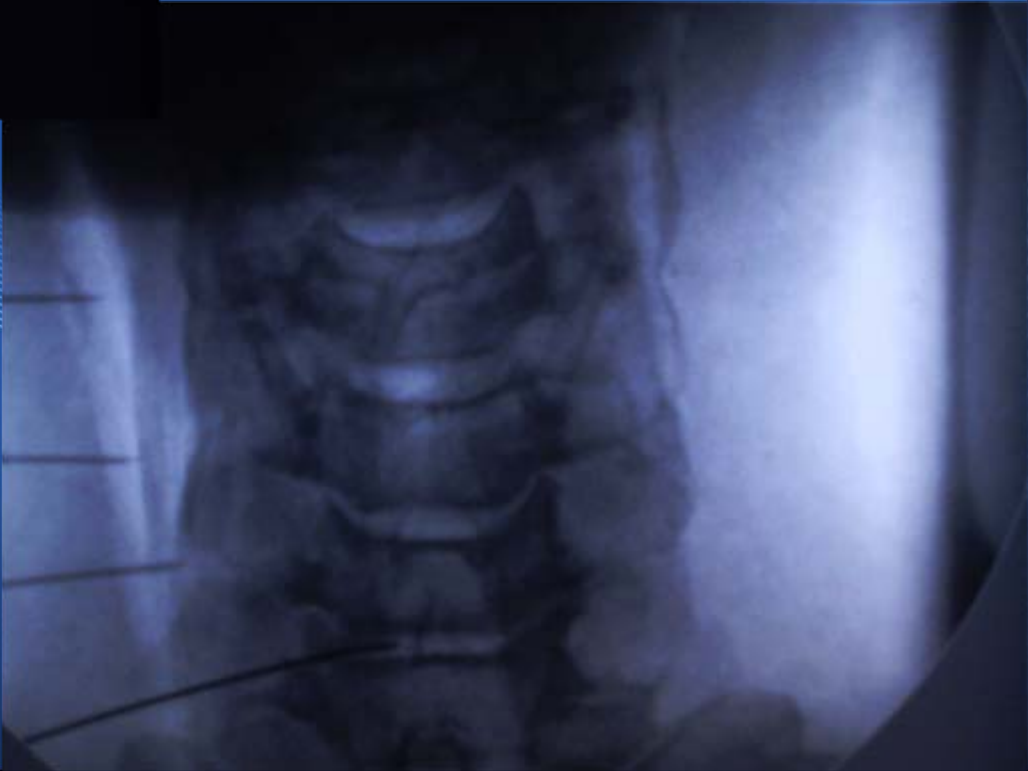

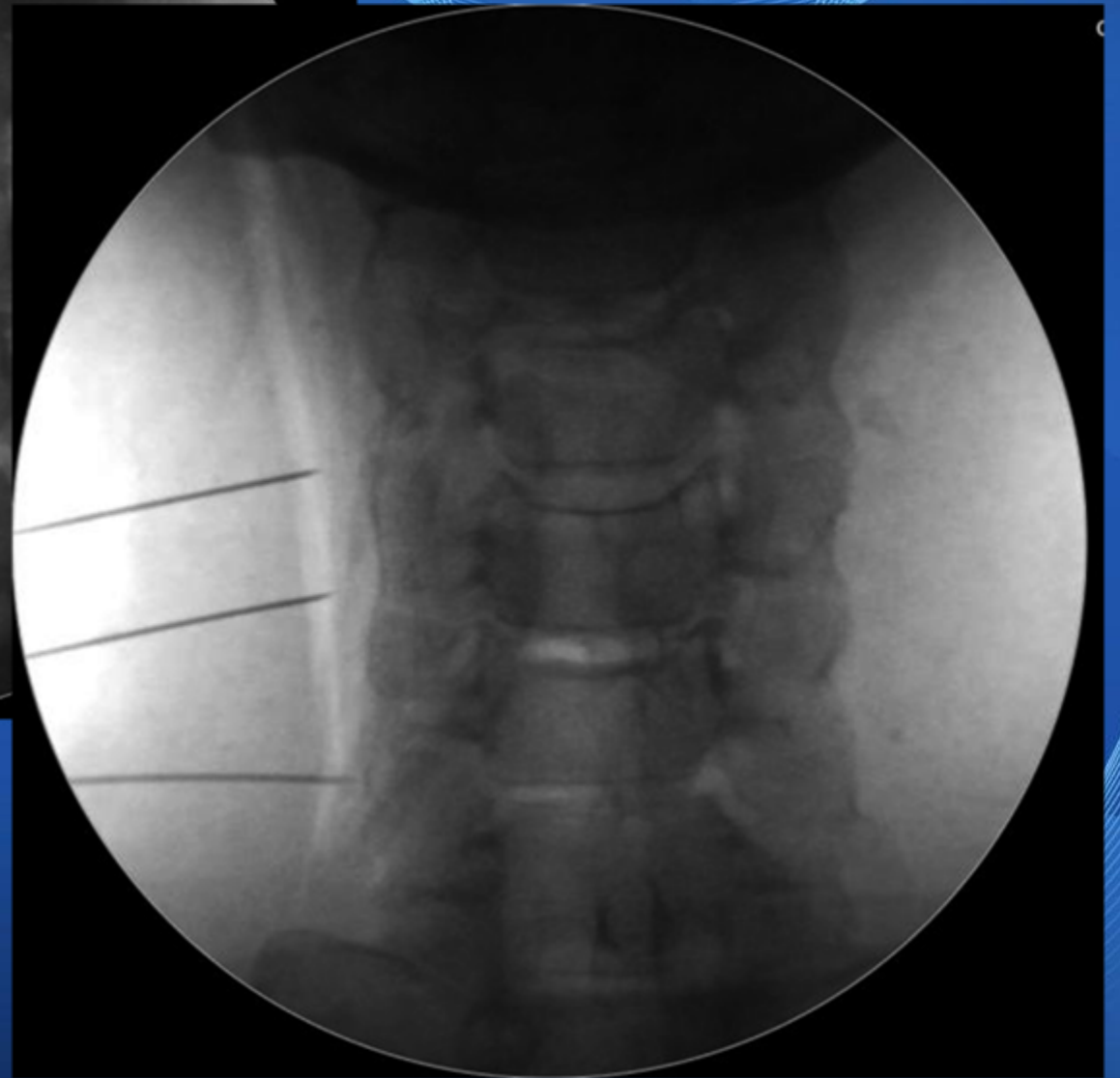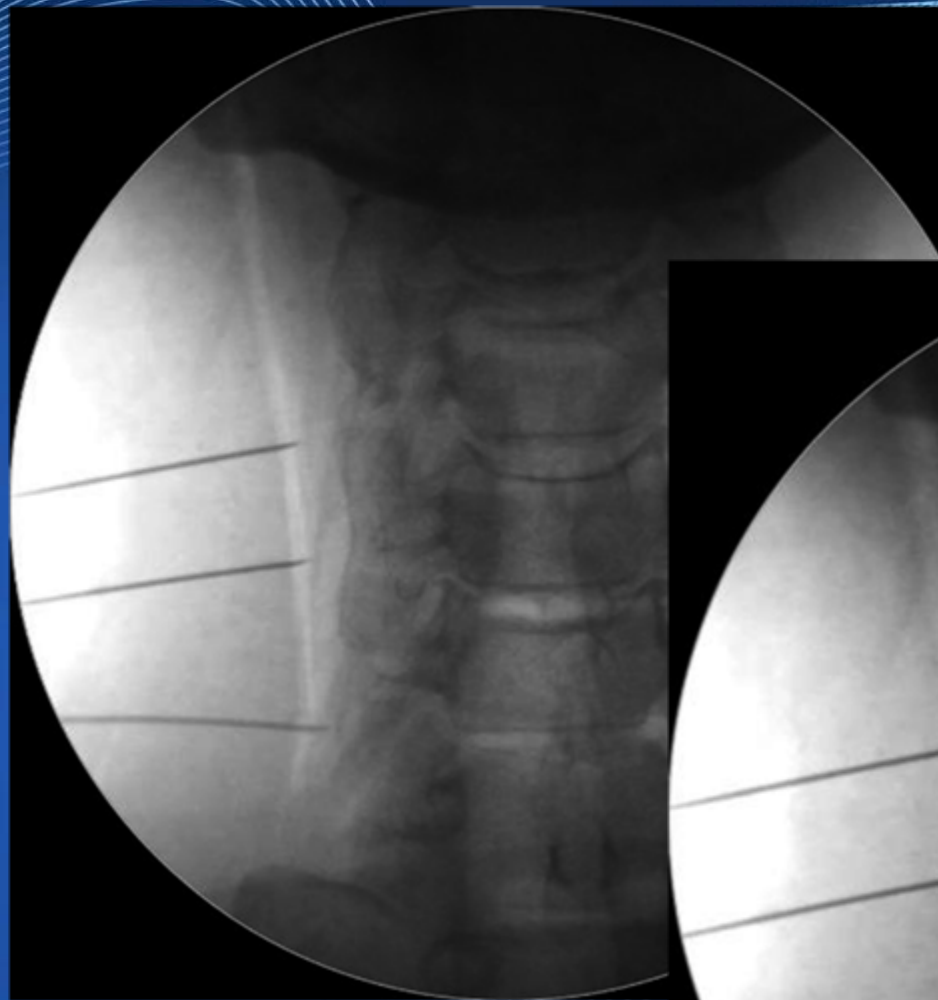




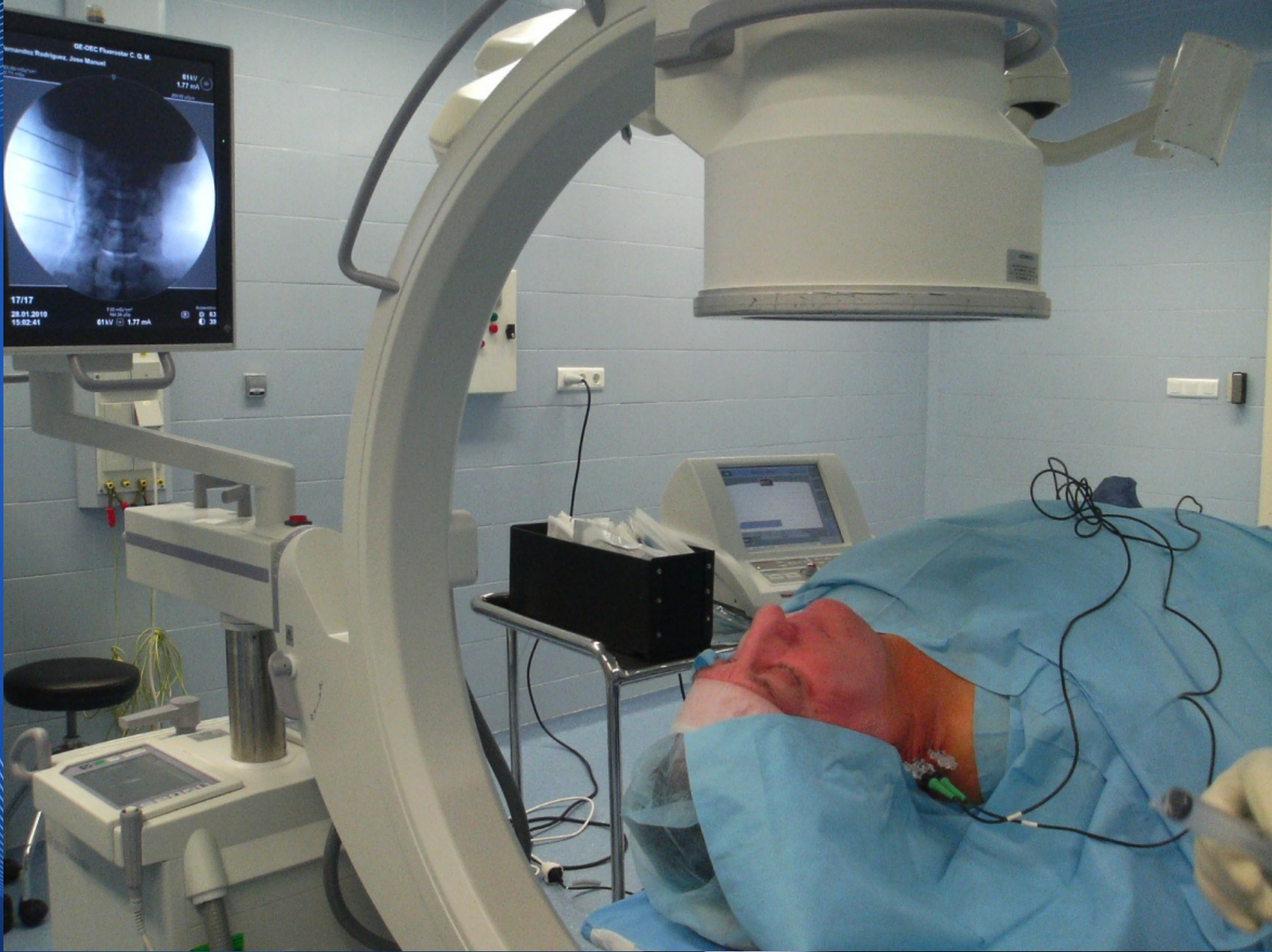
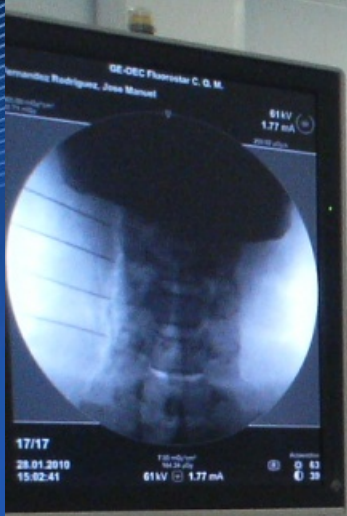
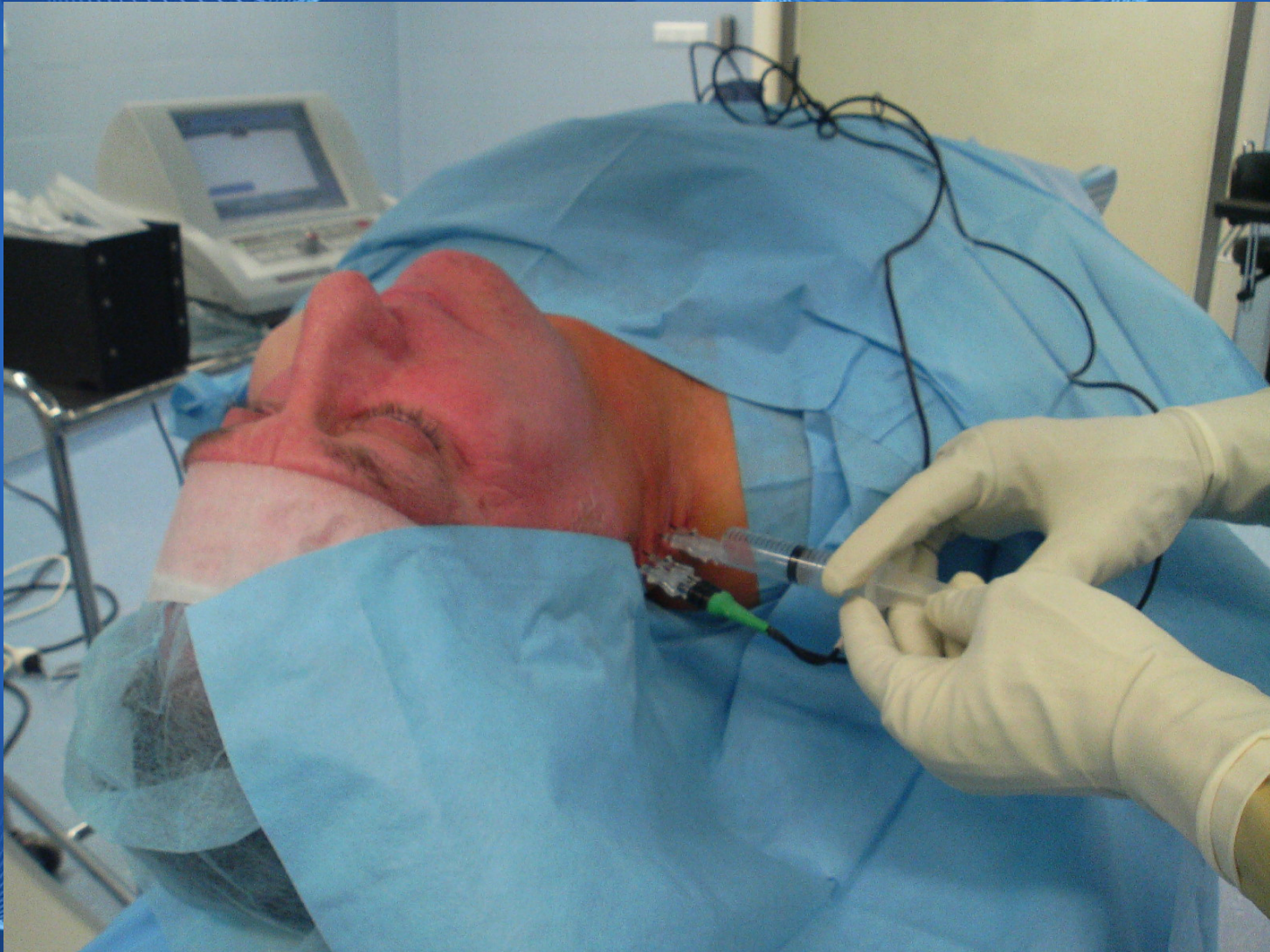Risonolisis Columna Cervical

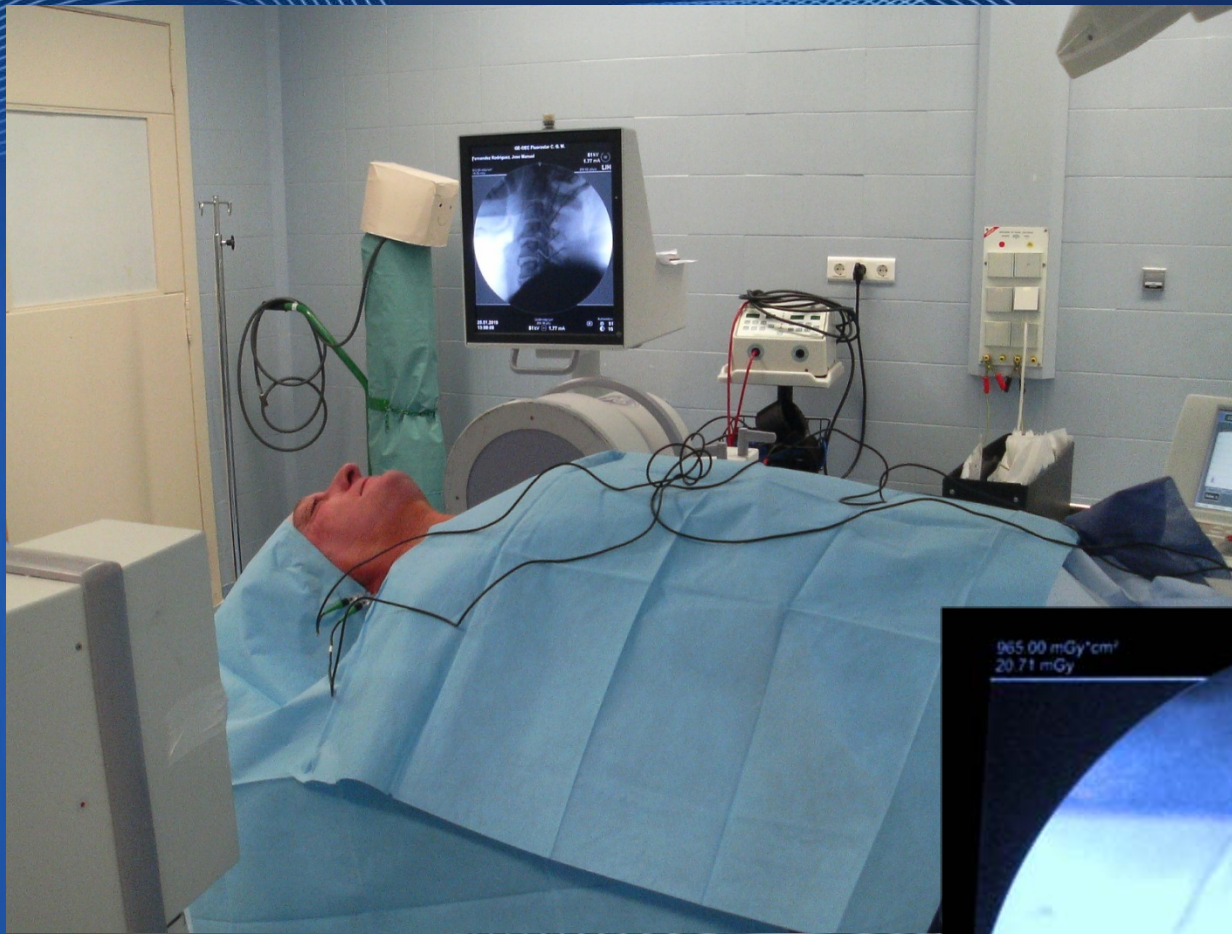




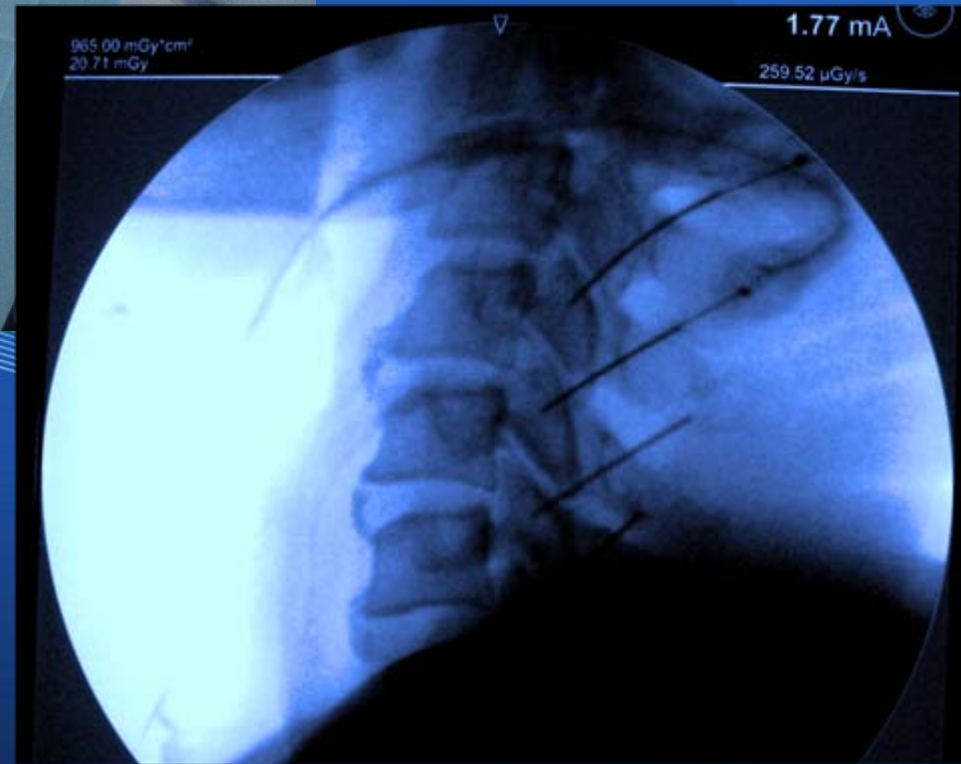

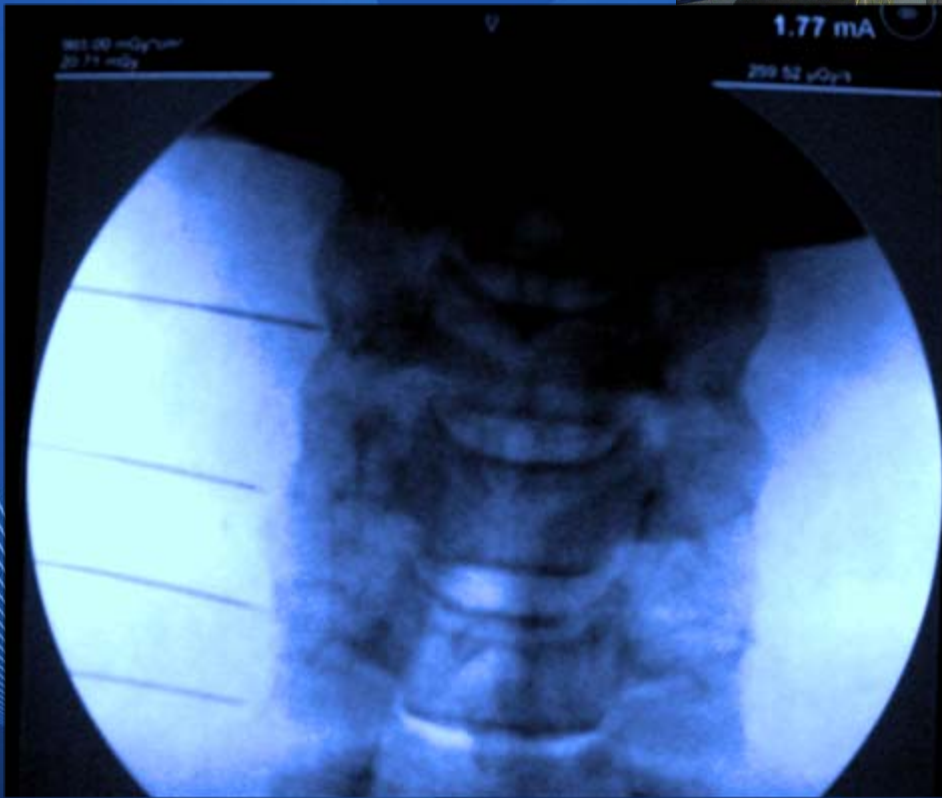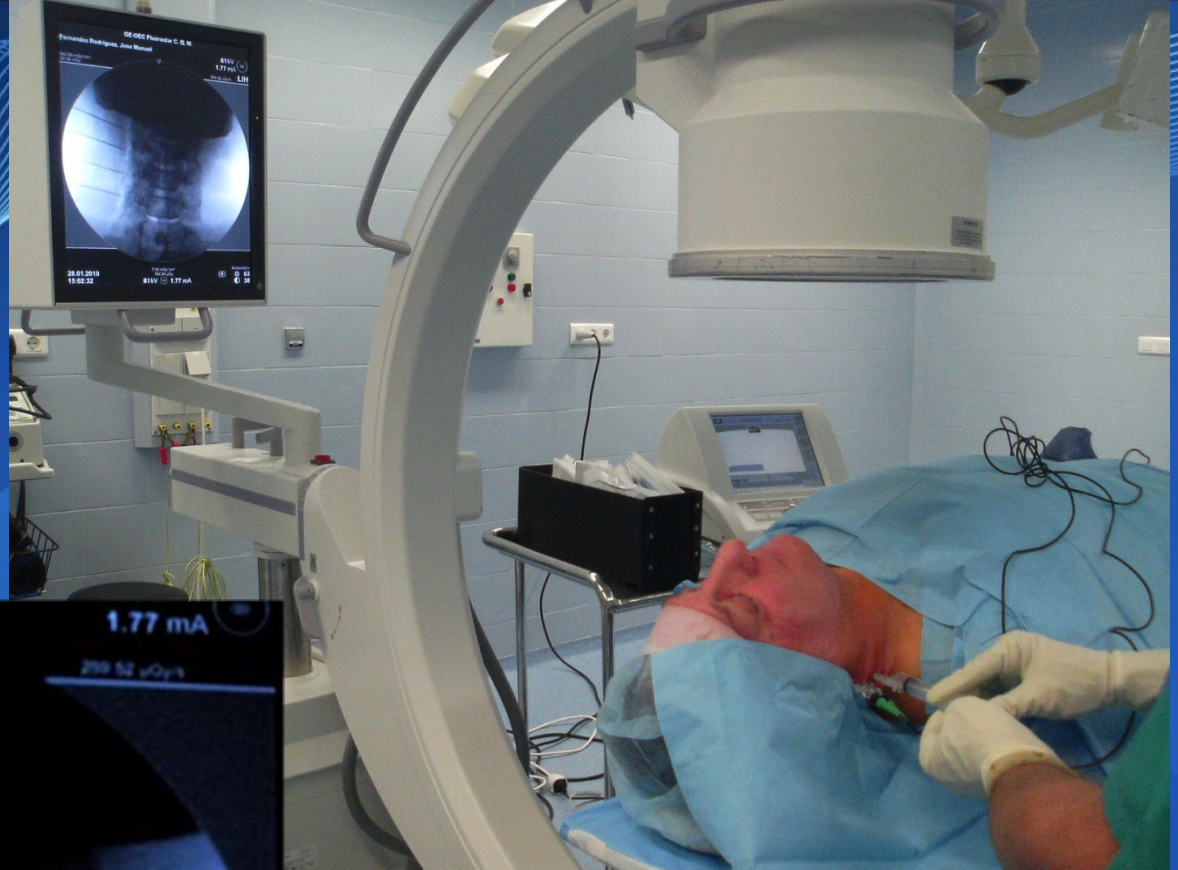
Inyección de Ozono por la Via Lateral Paravertebral Profunda



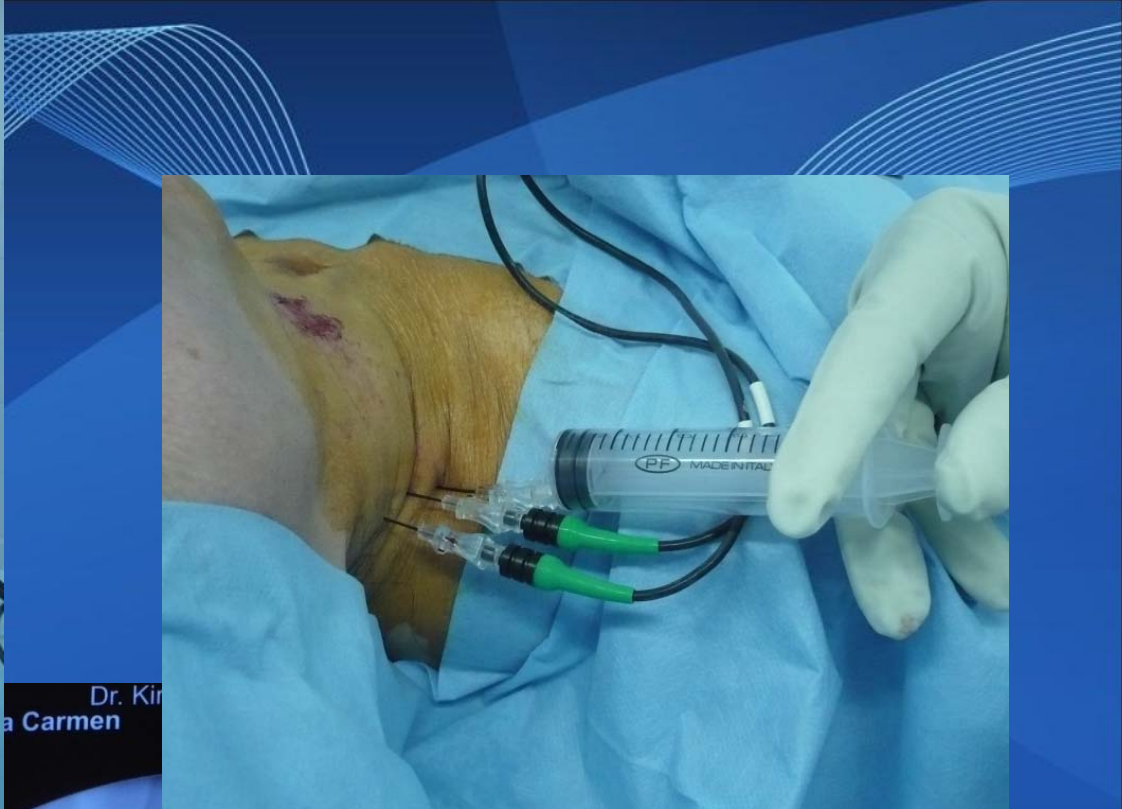
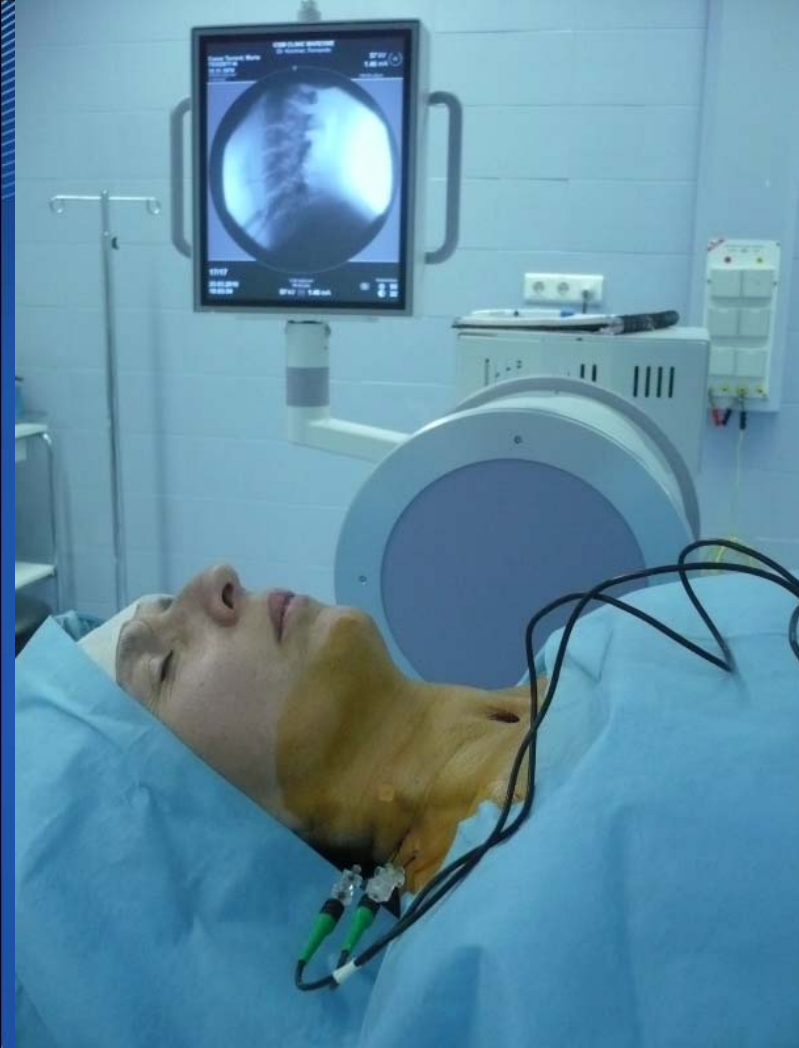
Proyección Radiológica de Perfil Esctricto

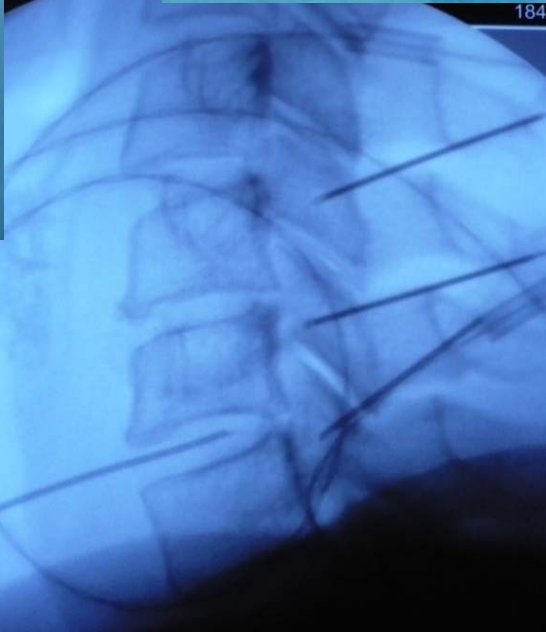


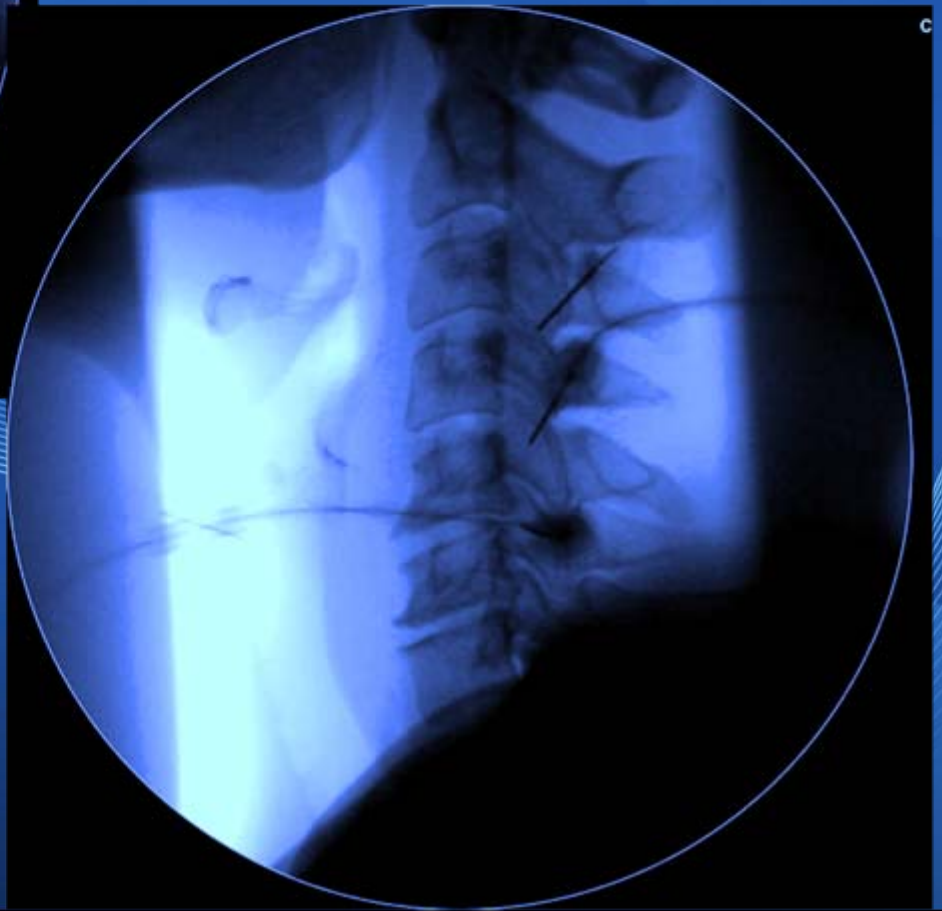
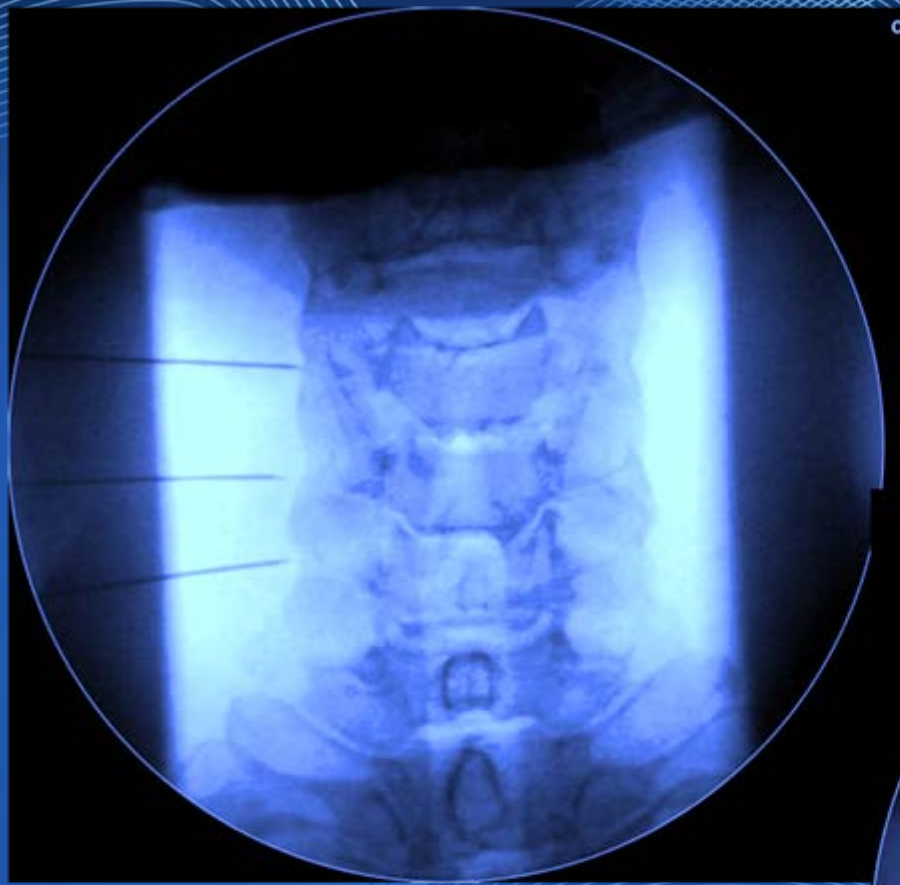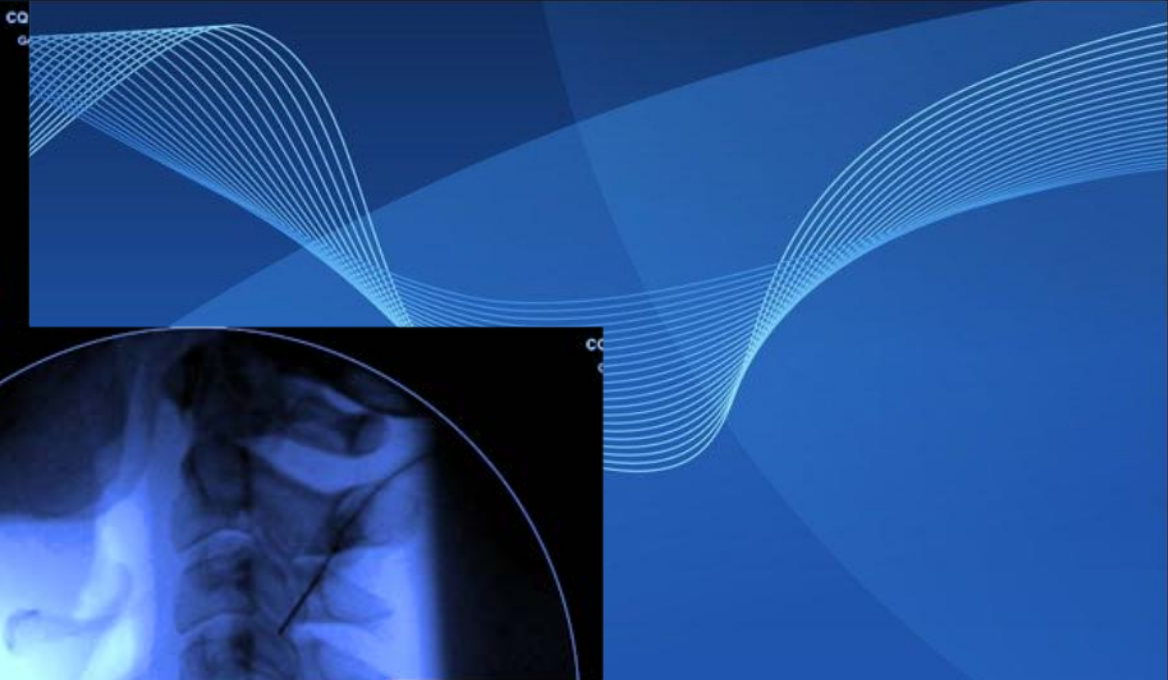
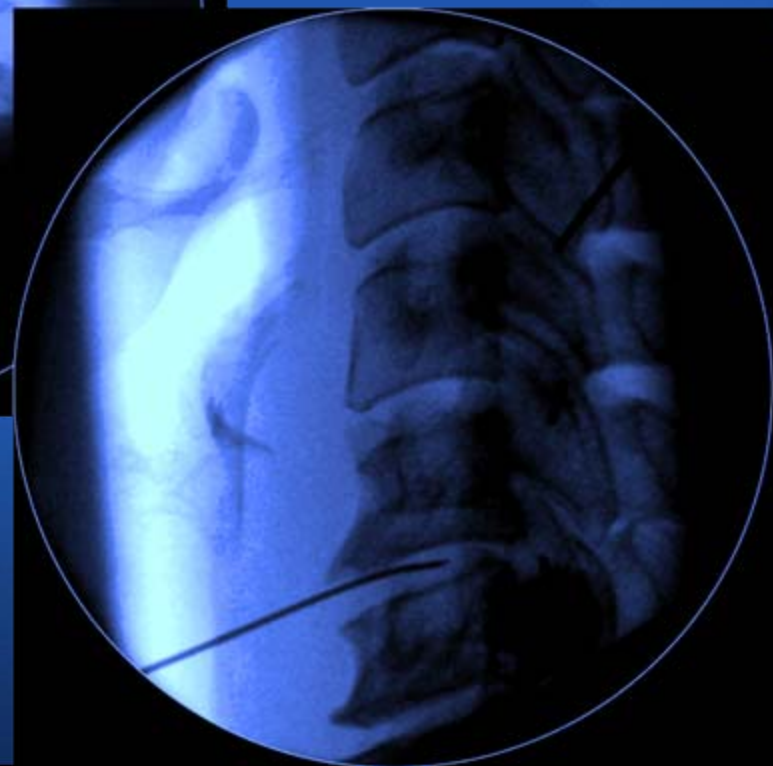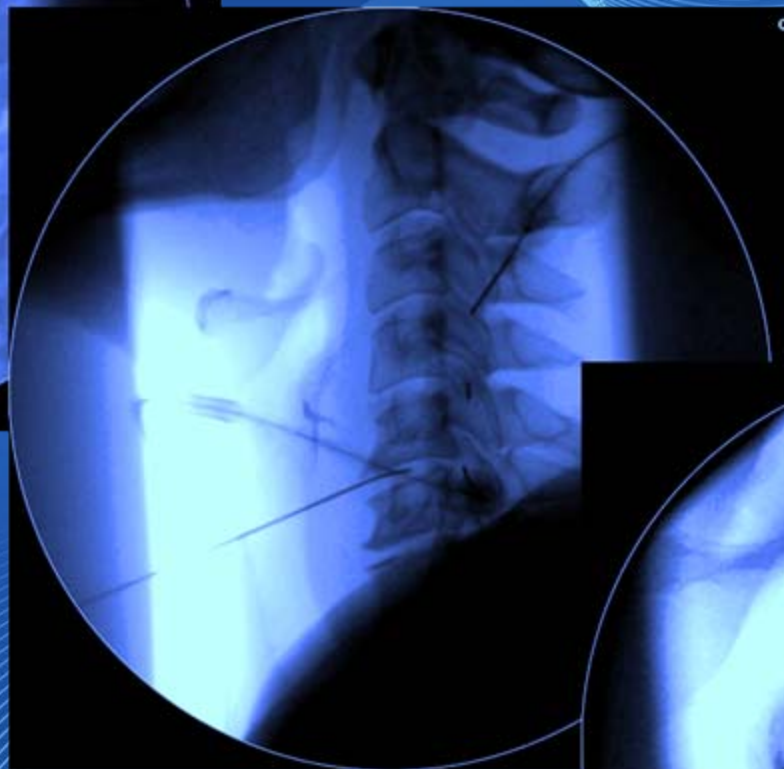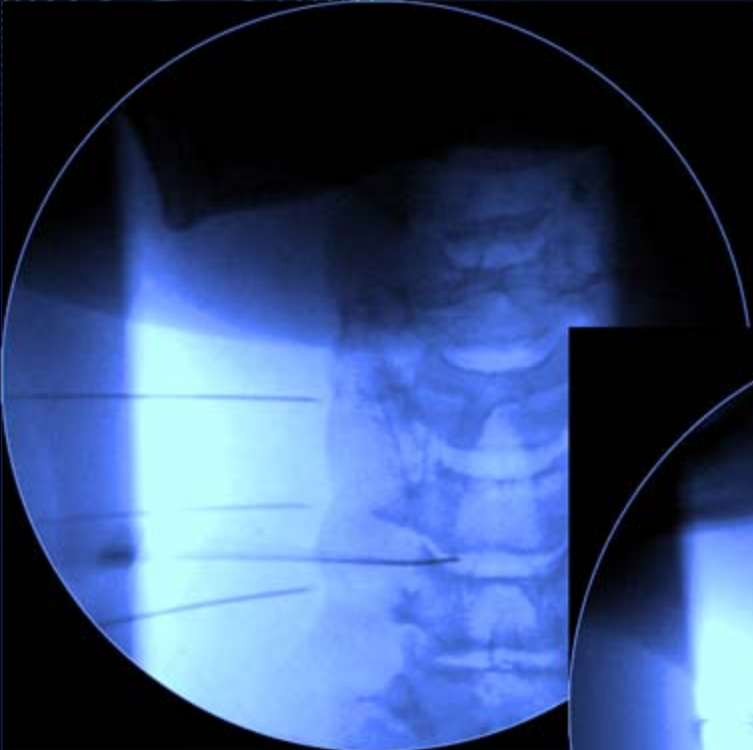
*Proyección Radiológica
de Frente*

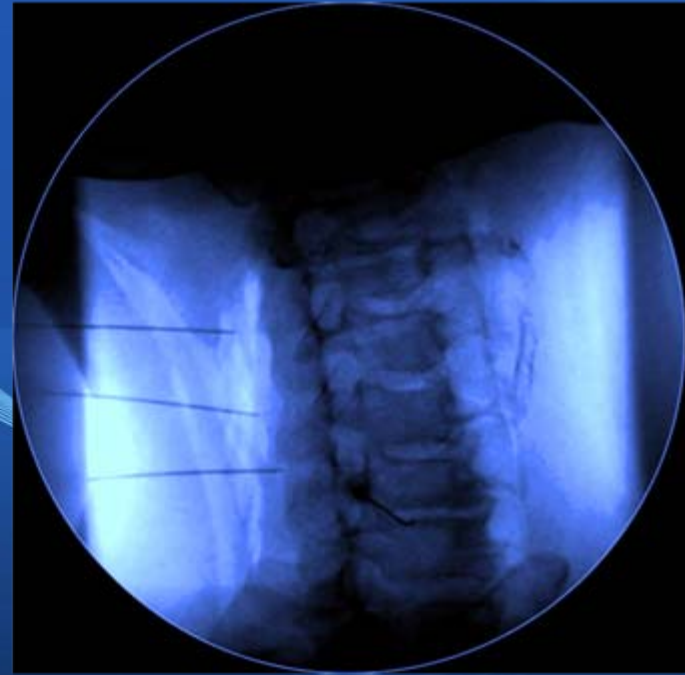
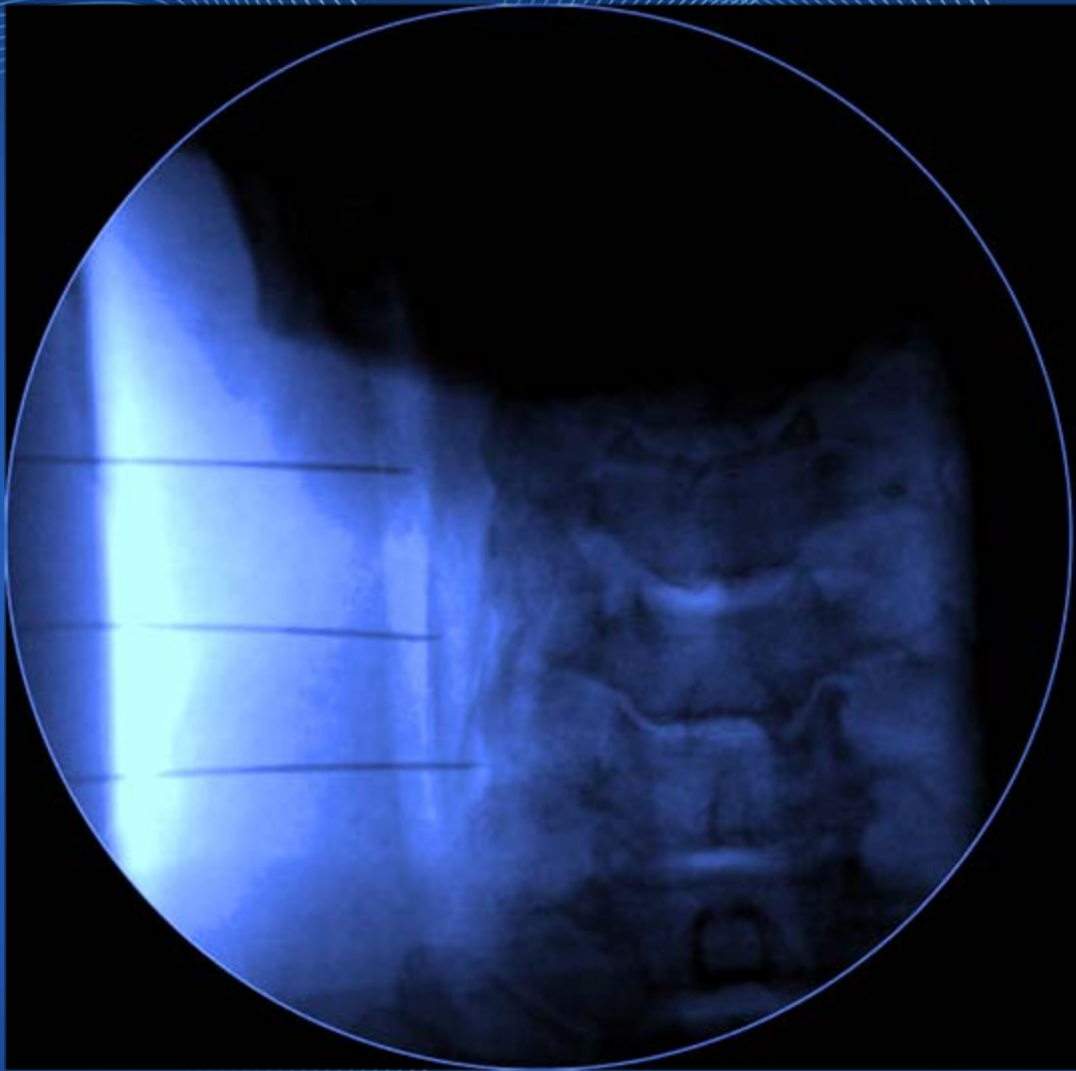


Dr. Kir
a Carmen











Muchas gracias